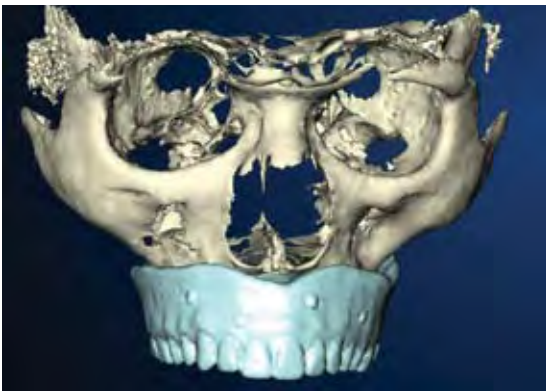
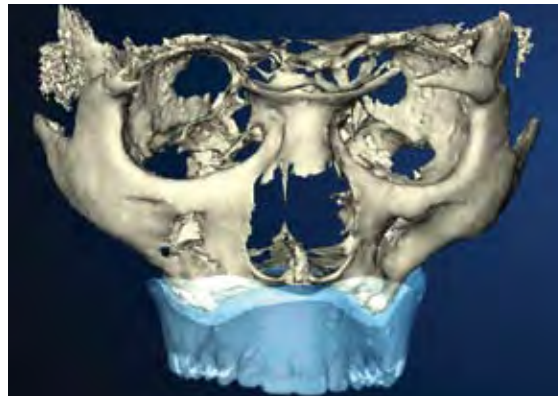


## Against All Odds A "No Bone Solution™"



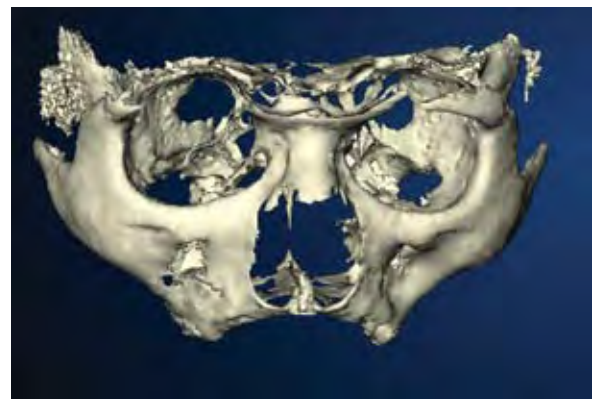
*3-D image of "no bone" maxilla viewed with Nobel Guide ProCera® software from Nobel Biocare*

Long-term success of osseointegrated implants depends on the length of the implants used and the quality and quantity of bone surrounding these implants. As surgical and prosthetic techniques have evolved, the success rate for routine implant treatment has improved and implant prosthodontics has become the standard of care.



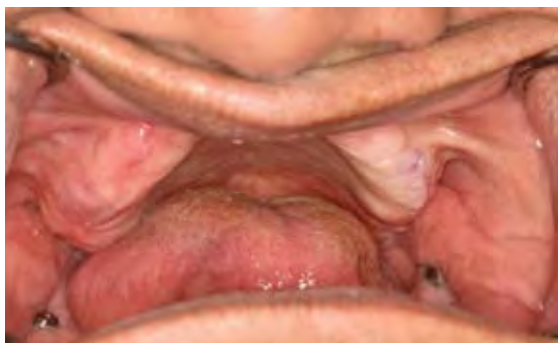*3-D image of skull and denture*

*What happens to the patients who have worn dentures for decades with little or no underlying bone support?*

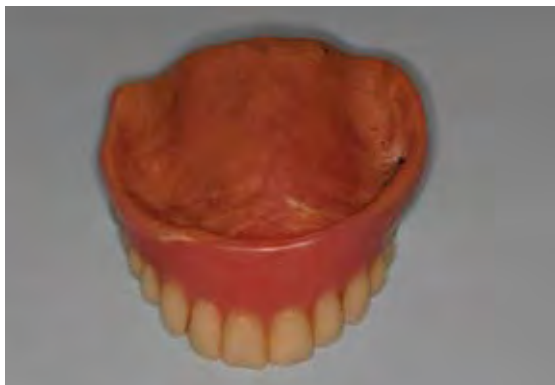

*3-D image of skull*

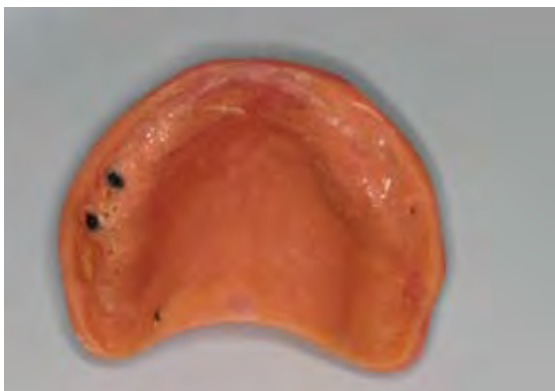**A** 67-year-old retired surgeon was referred to the Pi Dental Implant Center by his periodontist and restorative dentist in April 2007 with a prior diagnosis of “no bone in the maxilla (Figs 1A-C).” This patient’s desire for treatment included “fixed teeth” with improved oral function and esthetics. Some of his medical conditions were potentially detrimental to the long-term prognosis of complex dental treatment, but not insurmountable. The patient was diagnosed with diabetes, emphysema, high blood pressure and dry mouth syndrome. To further complicate matters, he smoked two packs of cigarettes a day and admitted to an intense parafunctional bruxing and clenching habit.



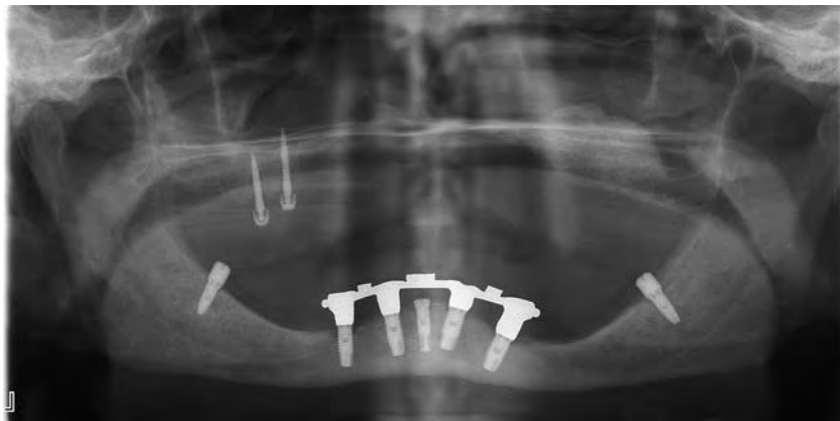
**Fig 1A:** Patient’s intraoral preoperative image illustrates minimal anterior ridge and bone in the posterior below the expanded sinuses.



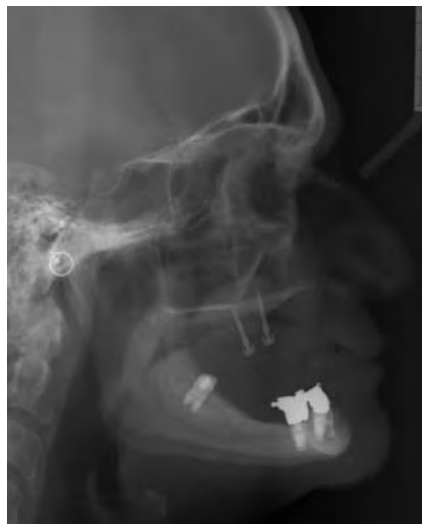**Fig 1B:** Upper removable denture exhibits a very flat and atrophic palate.



**Fig 1C:** Denture with two retention snaps for the failing “mini” implants

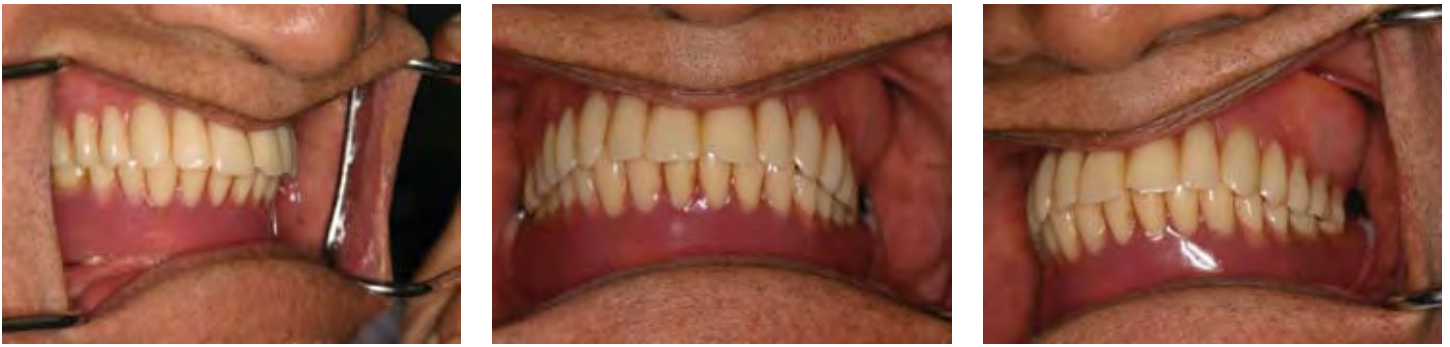

**Fig 2A:** Preoperative panoramic radiograph



**Fig 2B:** Lateral preoperative cephalometric radiograph

**No Bone Solution™** is a special treatment protocol developed at the Pi Dental Center. It combines unique computer guided implant surgery with precision screw retained fixed prosthodontic rehabilitation of the severely atrophic maxilla. The protocol eliminates the need for invasive bone grafting and extensive procedures.



**Figs 3A, 3B, 3C:** Preoperative dentures and radiographic guide

### Initial Clinical and Radiographic Assessment:

After a thorough oral examination, which included evaluation of the existing prosthetics, articulated diagnostic casts, panorex radiograph (Fig 2A), lateral cephalometric radiograph (Fig 2B) and preoperative clinical photographs, the following treatment plan was developed using the “No Bone Solutions™” protocol.

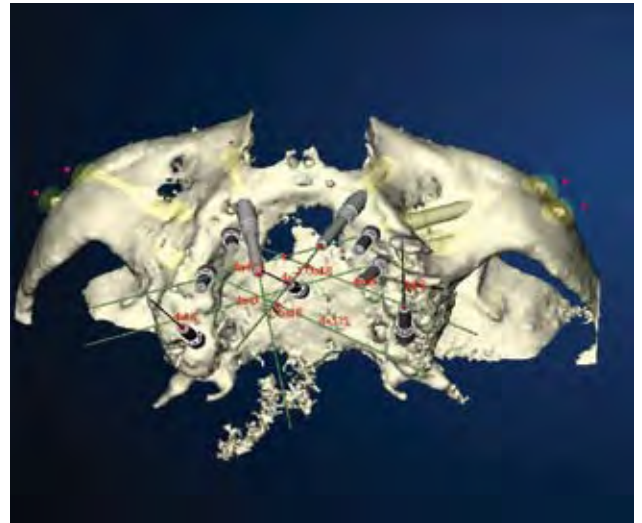
### Treatment Plan:

1. Removal of the non-integrated “mini” implants in the area of teeth 14 and 15.
2. Fabrication of a new maxillary denture (Figs 3A-C) that incorporated radiographic markers to be used in conjunction with an i-Cat cone beam scan.
3. Teeth In An Hour™ guided surgery for placement of five traditional Brånemark implants and freehand placement of four zygomatic implants to support an interim all-acrylic screw-retained fixed prosthesis.
4. After 12 weeks of healing and osseointegration, the fixed screw retained titanium and ceramic prosthesis was fabricated.

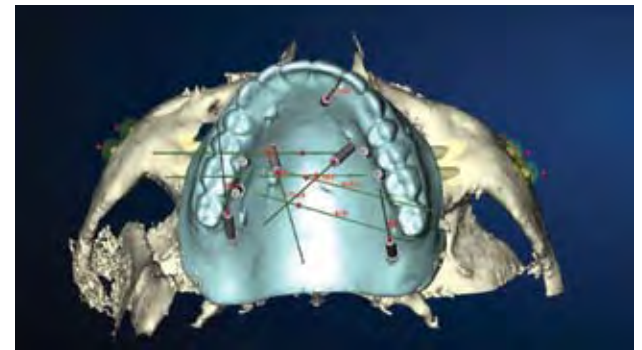
**Computer Plan:** A virtual plan of the intended surgery was completed using the Nobel Biocare Procera software (Fig 4 A-C ). Computer data was transmitted to a rapid prototyper machine for production of the surgical template. Using this template, a master cast was constructed and articulated. The screw retained provisional prosthesis was then constructed prior to dental implant surgery.

**Surgical Protocol:** Blood was drawn prior to surgery, transferred to the Harvest cell separator unit and Platelet Rich Plasma was prepared. General anesthesia was then administered and the patient was fully draped using the standard sterile protocol. Local anesthesia was also used for hemostasis.

Following the guided portion of the surgery, which assisted



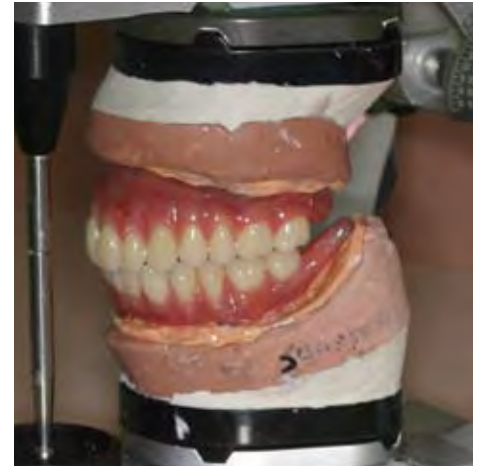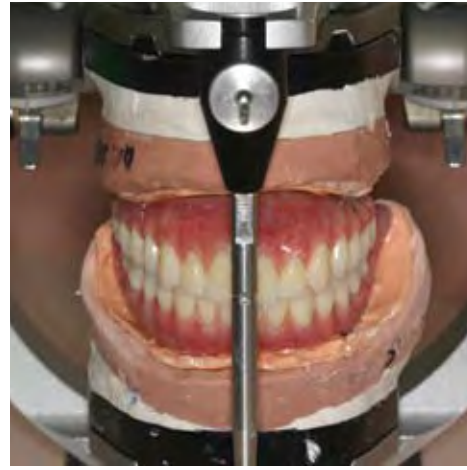
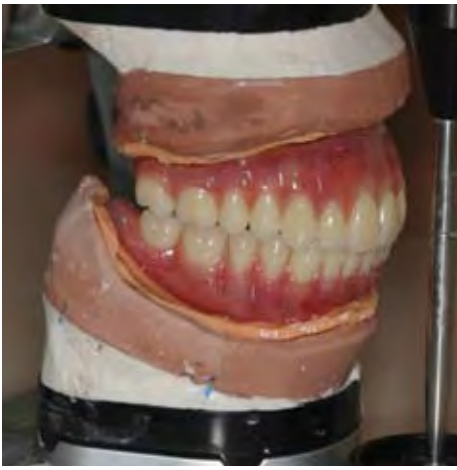**Fig 4A:** Nobel Biocare NobelGuide Procera® software illustrates implant locations and sizes in maxillary bone



**Fig 4B:** Nobel Biocare NobelGuide Procera® software depicts upper prosthesis with implants



**Fig 4C:** Nobel Biocare NobelGuide Procera® software shows implants only



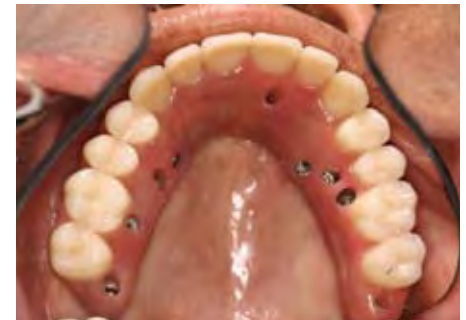**Figs 5A, 5B, 5C: Final prostheses articulated**

in the placement of 5 Brånemark implants, the surgical template was removed. A crestal incision and vertical releasing incisions were made bilaterally and full thickness flaps were elevated to the level of the superior aspect of the zygomatic bone. The transantral osteotomies, using graduated diameter drills, were completed to permit the apex of the implants to penetrate through the lateral surface of the zygoma. A total of four Brånemark System® Zygoma implants were installed—two in each zygoma. Finally, using the Teeth In A Day® conversion protocol, the previously constructed prosthesis was installed on the standard Brånemark implants and then connected intraorally to the zygomatic implants. The prosthesis was then removed, adjusted, polished and reinstalled.

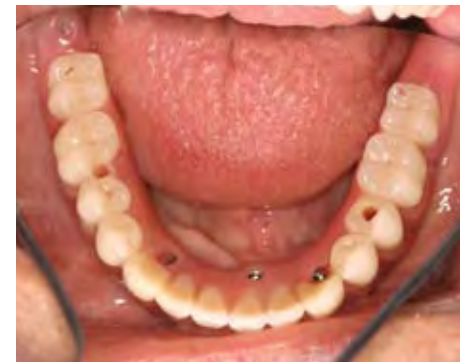### The Final Prosthesis

Osseointegration, under immediate loading conditions is paramount to the success of this prosthesis. Research on immediate loading has shown that after eight weeks—osseointegration should be mature to allow for a predictable outcome.<sup>1</sup> Due to this patient's numerous medical conditions, the final impression was taken after a 12-week healing time. He was restored using CM ceramic technology produced in Mahwah, New Jersey.

The final prosthesis for the maxilla consisted of a CAD/CAM robotically milled titanium frame with individual zirconium ceramic crowns using the Nobel Biocare ProCera Technology. (Figs 5A, 5B, 5C)

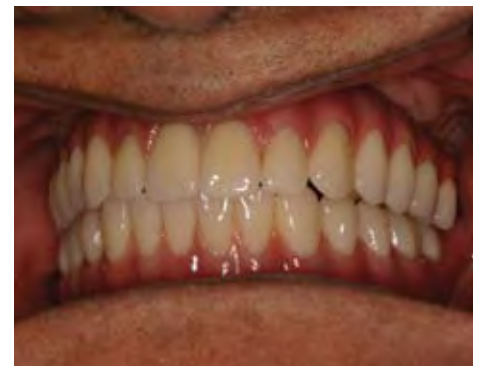
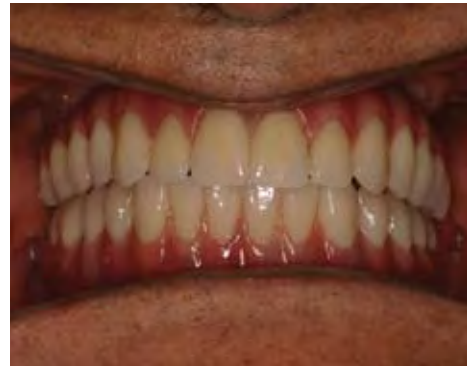
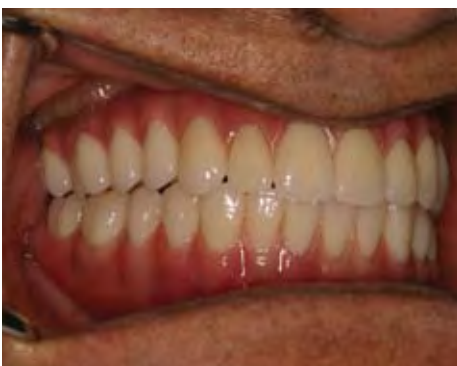**Fig 6A: Maxillary ceramic teeth**

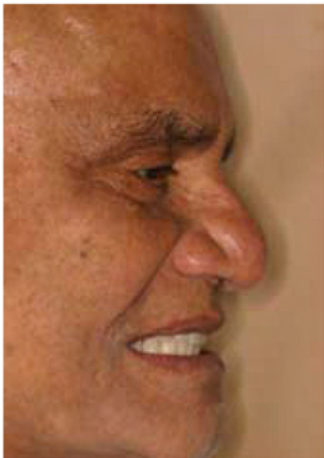


**Fig 6B: Mandibular resin teeth**

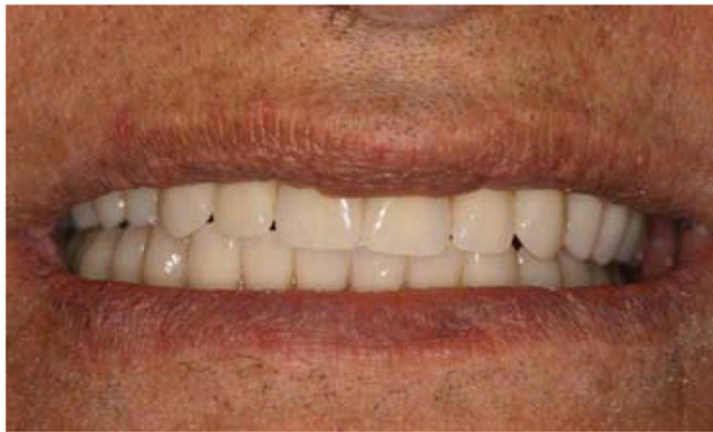**Footnote 1:** A resonance frequency analysis assessment of maxillary and mandibular immediately loaded implants. Balshi SF, Allen FD, Wolfinger GJ, Balshi TJ. Int J Oral Maxillofac Implants. 2005 Jul-Aug;20 (4):584-94.



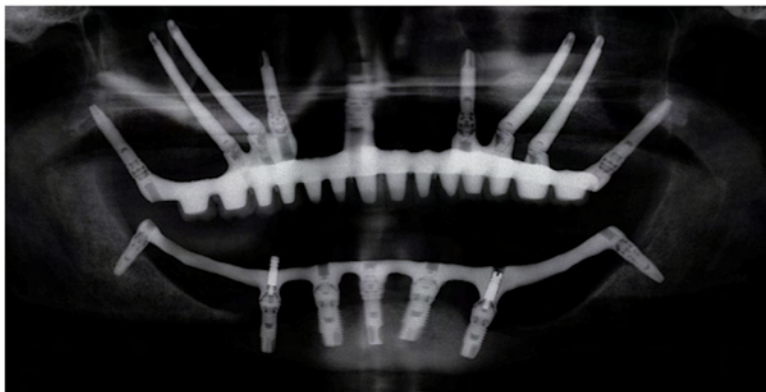**Fig 7A, 7B, 7C: Final maxillary and mandibular prostheses**



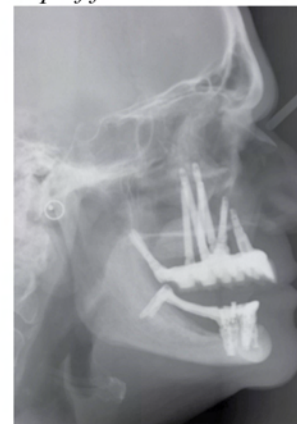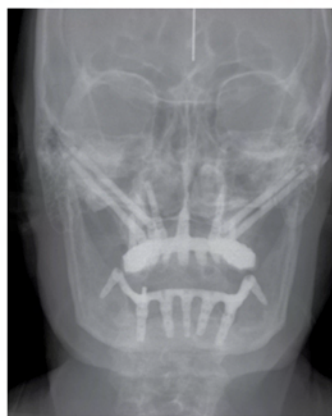**Fig 7D, 7E:** Front and side views with final prosthesis



**Fig 7F:** Post-operative closeup of final teeth



**Fig 8A:** Post-op paradiograph



**Fig 8B, 8C:** Post-op cephalometric radiographs

## Conclusion

Patients with extreme maxillary atrophy generally suffer with ill-fitting removable prostheses that chronically irritate the mucosa and insult what little underlying bone remains. For patients with no remaining alveolar bone, the “No Bone Solution™” protocol demonstrated in this article is an ideal treatment that avoids major bone grafting and the long associated healing and treatment time. The “No Bone Solution™” potentially shortens treatment time to only 3 visits over a 3-month period. It also provides patients with little or no bone with a non-removable solid set of teeth in just one day.

## Acknowledgement

Pi team gratefully thanks two dedicated dental specialists, Dr. Russell Morgan, Restorative Dentist and Dr. Gregory Felthousen, Periodontist (both of Salisbury, MD) for extraordinary “insights” in their encouragement and genuine concern for the patient illustrated in this issue. Likewise, we also acknowledge numerous colleagues who have provided similar guidance to clinically “hopeless” patients.

### Lab Support:

Stephen F. Balshi, MBE, CM Prosthetics, Fort Washington, PA  
Robert D. Winkelman, CDT, MDT, Fort Washington Dental Lab



Prosthodontic Insights is published by Pi Dental Center and distributed without charge to individuals. Please request a subscription on your organization’s letterhead.

**Pi Dental Center**

467 Pennsylvania Avenue, Suite 201  
Fort Washington, PA 19034 USA  
TEL: 215-643-5881  
FAX: 215-643-1149  
piteam@pidentalcenter.com



*Thomas J. Balshi,  
DDS, FACP*



*Glenn J. Wolfinger,  
DMD, FACP*



*John J. Thaler II,  
DDS*



*James R. Bowers,  
DDS*



FEATURING



THOMAS J. BALSHI, DDS, FACP  
Board Certified Prosthodontist



GLENN J. WOLFINGER, DMD, FACP  
Board Certified Prosthodontist



STEPHEN F. BALSHI, M.B.E.  
Biomedical Engineer



ROBERT WINKELMAN, CDT, MDT  
Master Dental Technician



## Continuing Education:

### Immediate Loading of Implants With The Teeth In A Day® Protocol

This course reviews traditional dental implant surgery and current scientifically based techniques including Teeth In A Day® using lectures, computer presentation, and videos, as well as hands-on training and observation of live surgeries. Intraoral live video gives participants the "Surgeon's Eye View" of the procedure and interactive discussion. Courses are presented in a private practice clinical facility with full laboratory support.

### Nobel Guide Concept™ and Teeth In An Hour™ 3D Computerized Implant Guided Surgery and Prosthetics Course

The NOBELGUIDE™ Concept and the Procera® System is a treatment modality that uses computer surgical planning to treat patients with minimally invasive protocols. The i-Cat cone beam has made evolutionary advances in CT scanning that make it possible to fully recreate a 3-D surgical site. Based on virtual planning, robotics and rapid prototyping are used to create a precise surgical template. Reverse engineering is then used to prefabricate a fixed restoration.

Combining the surgical template, immediate loading principles, and a screw retained prosthesis makes it possible to provide a flapless surgical procedure with a restoration called "Teeth In An Hour™", shortening healing time and minimizing bruising and swelling.

This two day hands-on training course will also be conducted at Nova Southeast University, Fort Lauderdale, Florida: January 19 & 20, 2008.

### Advanced Guided Surgery

This advanced course is for the clinician who is already certified and experienced with the NobelGuide™ / Teeth in an Hour™ protocol. Course participants are asked to bring their laptops with Procera® software. More challenging tasks using the Procera® Software to place implants that are tilted off axis, posterior implants of the All-on-4 technique, pterygomaxillary implants, and zygoma implants are reviewed. An advanced guided surgery case is covered. Live patient CT data will be distributed to the course participants for conversion and 3D planning of the case. Live surgery of the patient will follow. This live case will deviate from the standard NobelGuide™ protocol and the course will emphasize the necessary steps to avoid potential inaccuracies with those deviations.

### The Severely Atrophic Maxilla:

#### Stabilizing Implants in the Pterygomaxillary and Zygoma Regions

This course will include a live surgery showing the placement of the implants along with hands-on mannequin laboratory workshop. Course highlights will include presentations on treatment planning, as well as the surgical, radiological, biomechanical, and restorative aspects of new approaches to treat the compromised maxilla.

### All-on-4:

The All-on-4 treatment concept for complete arch rehabilitation is an economic yet attractive prosthetic solution utilizing immediate loading concepts. Call for schedule and details.

### Zygoma Implants Using NobelGuide 3D Computerized Planning, and Live Guided Implant Surgery:

This course explores the NOBELGUIDE™ Concept and the Procera® System using zygoma implants and utilizing virtual surgical planning with a minimally invasive protocol. Call for schedule and details.