

## Hygiene maintenance procedures for patients treated with the tissue integrated prosthesis (osseointegration)

Thomas J. Balshi, D.D.S., F.A.C.P.\*

### Introduction

Successful prosthodontic rehabilitation of edentulous or partially edentulous patients treated with osseointegration (Figs. 1a to 1e) has been described by Brånemark et al.<sup>1</sup> The restoration secured to the jawbone is termed the *tissue integrated prosthesis*. These patients have unique requirements for posttreatment soft tissue maintenance. Currently the tissue integrated prosthesis consists primarily of a rigid cast gold substructure supporting artificial teeth, anchored to the jawbone via osseointegrated Biotes† titanium fixtures (Figs. 2a and 2b). The titanium fixtures and abutment cylinders of the Biotes system are specifically designed and machined to produce special biocompatible surface characteristics. The titanium oxide (TiO<sub>2</sub>) on the surface of the fixtures and abutment cylinders is critical to the continued maintenance of tissue integration between the vital biologic tissues and the implanted material.

Clinically the Biotes abutment cylinders appear to be less plaque-retentive than natural teeth. However, plaque accumulations do occur (Fig. 3) and must be removed to prevent inflammation of the adjacent mucosal tissues.

### Hygiene procedures

A variety of techniques have been used clinically to maintain adequate plaque control and oral hygiene. Oral hygiene attention must be considered in two

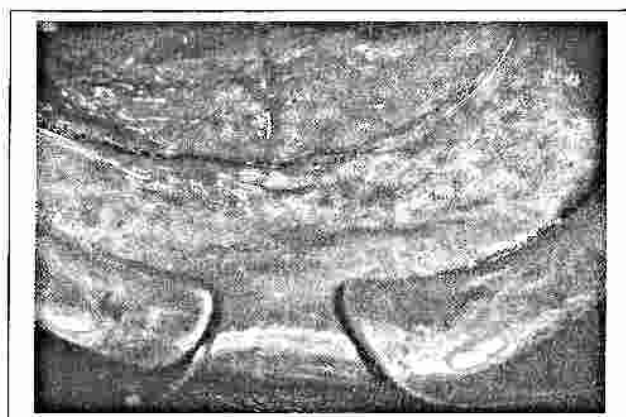

Fig. 1a Pretreatment condition of the edentulous mandible.

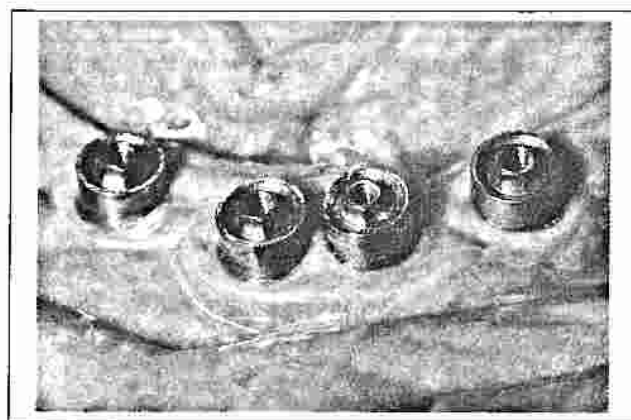


Fig. 1b Titanium Biotes jawbone anchorage units used to support the nonremovable tissue integrated prosthesis.

\* Associate Clinical Professor, Temple University, School of Dentistry. Address all correspondence to: Dr. Thomas J. Balshi, Upper Dublin Professional Center, 1244 Fort Washington Avenue, Fort Washington, Pennsylvania 19034.

† Bofors Nobelpharma, Inc., Goteborg, Sweden.

specific areas of the tissue integrated prosthesis. The first area is the portion of the titanium fixtures and abutment that is exposed above the mucosal tissues (Fig. 1b) in the oral cavity as well as the small portion of the abutment fixtures just slightly below the

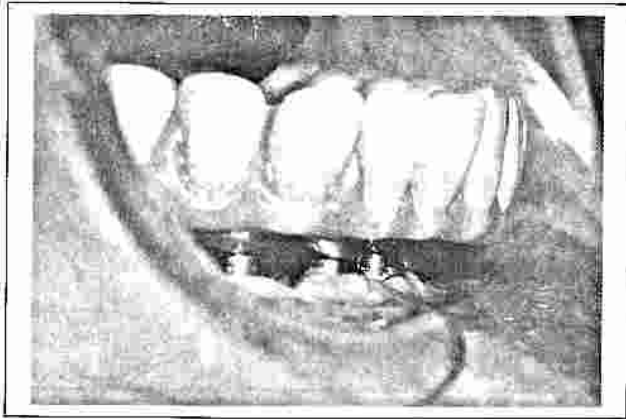


Fig. 1c Lateral view of the final prosthesis.

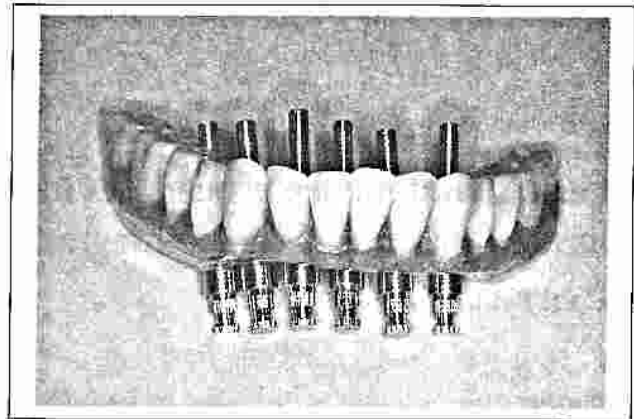


Fig. 2a Facial view of the tissue integrated prosthesis.

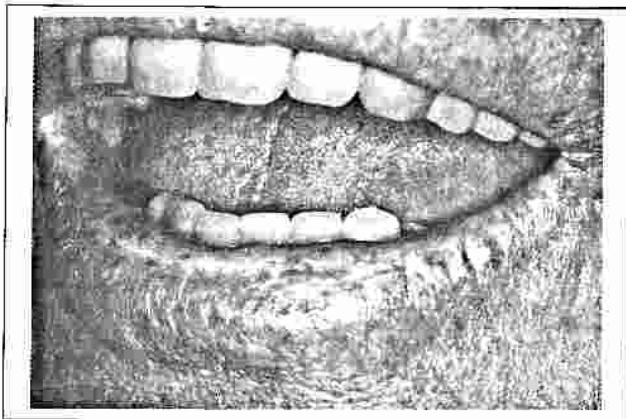

Fig. 1d The prosthesis as it is viewed when the patient is smiling.

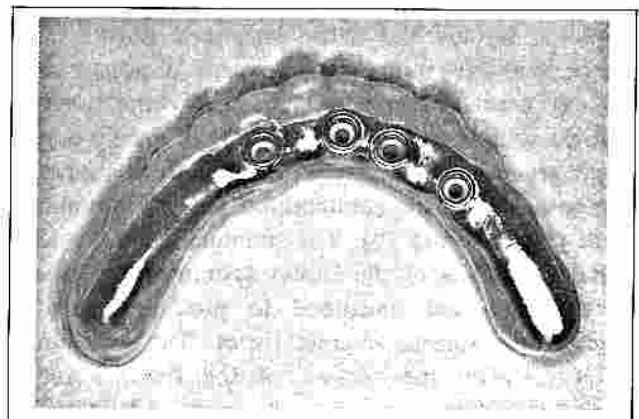


Fig. 2b Cervical view of the prosthesis shows the highly polished gold substructure.

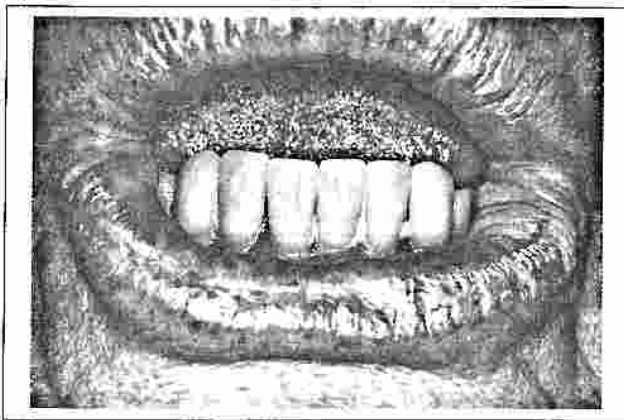


Fig. 1e An unsuccessful attempt to expose the titanium anchorage unit under deliberate lip strain.




Fig. 3 Although the Biotes abutment cylinders may not be as plaque-retentive as natural teeth, some plaque accumulation does occur.

mucosal tissues. The second area requiring plaque control and hygiene maintenance is the prosthetic component, consisting of the rigid cast framework and tooth replacement materials (Figs. 2a and 2b).

### *General cleansing*

The dental prosthesis itself can be cleaned and maintained using most of the traditional methods of plaque control and oral hygiene described for use with patients having conventional fixed prosthodontics.<sup>2</sup> Toothbrushes with soft polished bristles are recommended for general all-purpose cleaning of the facial, lingual, and occlusal surfaces (Figs. 4a to 4c).

### *Pontic areas*

Where space permits between the residual ridge and cantilevered pontic portion of the prosthesis, gauze strips can be used to debride and continually polish the cervical aspect of the prosthesis. The gauze can also be pulled toward the abutment cylinders and used to cleanse the titanium surface as well (Figs. 5a to 5c).


In areas where space is limited, thin, soft nylon mesh, frequently found as a bulk filler in quilted fabrics, can be used as a broad surface cleansing aid (Figs. 6a to 6c).

### *Fixture cleansing*

Cleansing of the titanium fixtures and surrounding areas, however, must take special consideration. Since the titanium oxide is critical to the maintenance of tissue integration, an effort should be made to preserve the surface texture of the abutment in its original smooth condition. Although titanium is a strong, lightweight metal, it is easily scratched and marred. Scratches, cuts, and dents increase plaque retention and may change the surface oxide character. To avoid damaging the titanium surface, specific cleansing methods must be followed.

Exposed portions of the fixtures and abutments can be cleansed by conventional brushing. Hard-to-reach areas are often best managed with an end-tufted soft polished bristle brush (Fig. 4c).

Several methods of cleaning between the fixtures are available. Use of Superfloss\* produces excellent results for plaque control around the fixtures and



Figs. 4a to 4c Toothbrushes with soft polished bristles can be used for general cleaning of the facial, lingual, and occlusal surfaces.

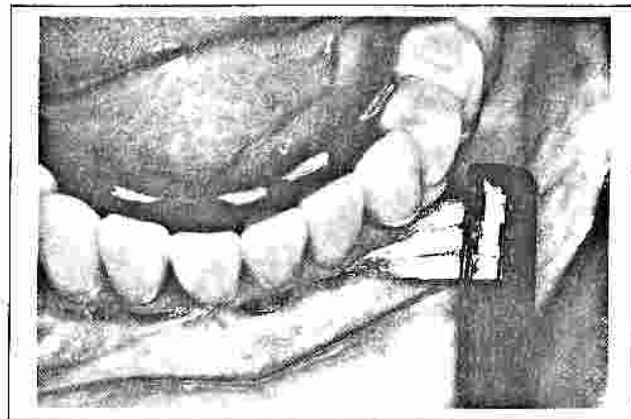


Figure 4b

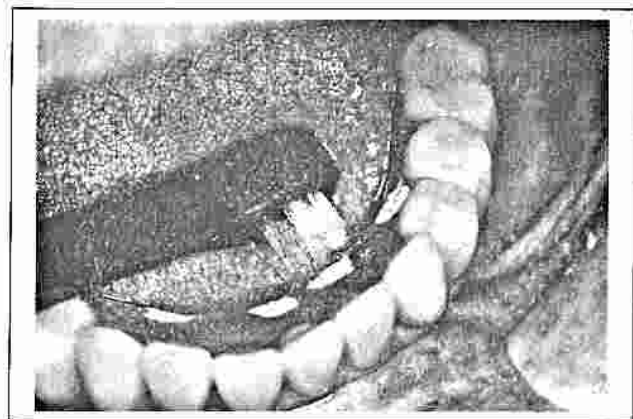
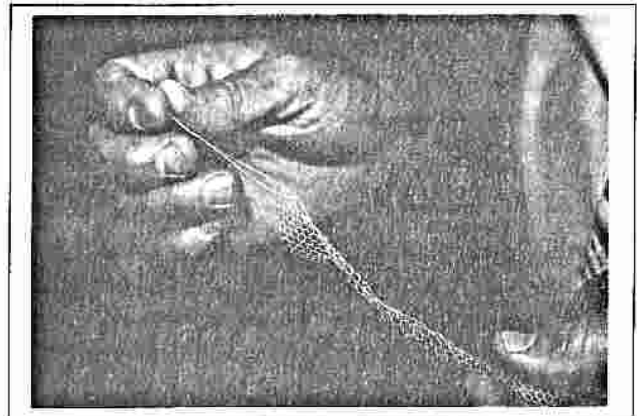
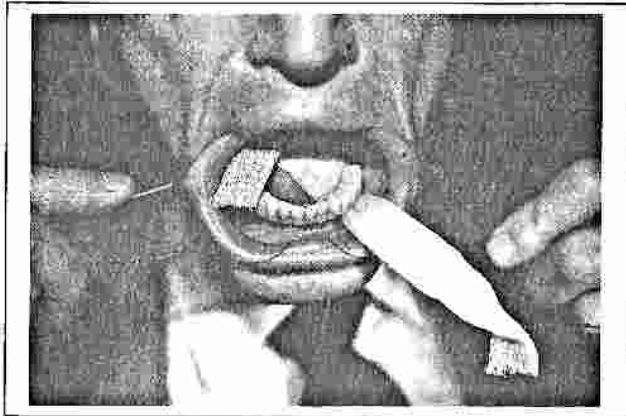

Figure 4c

\* Oral B, Atlanta, Ga.



Figs. 5a to 5c A gauze strip is inserted under the posterior cantilevered pontic area and drawn out of the mouth in a buccal direction. Gauze is also used to cleanse the distal aspect of the titanium abutment cylinder, as shown in Fig. 5c.

Figs. 6a to 6c This, soft nylon mesh can be used to clean areas where space is limited. The mesh is attached to a floss-threading device and inserted where necessary.

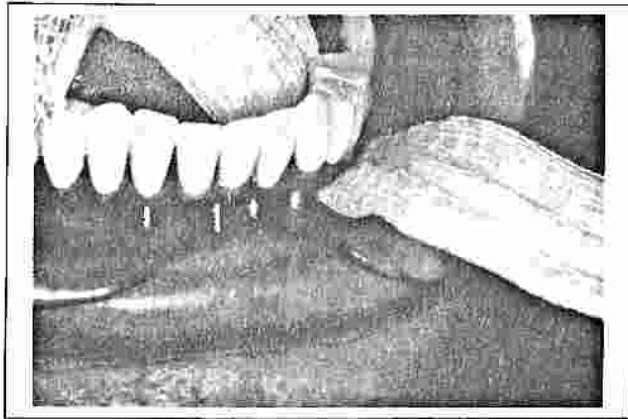


Figure 5b

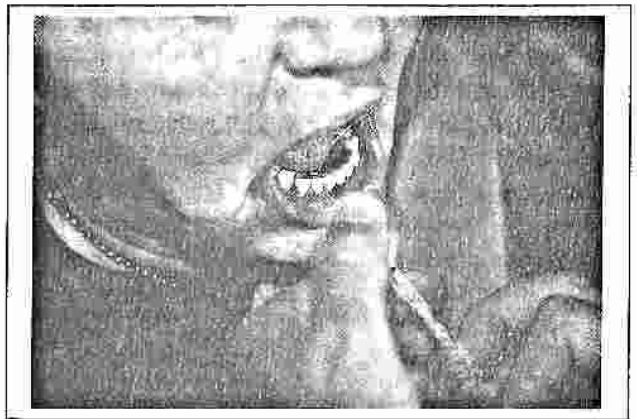


Figure 6b

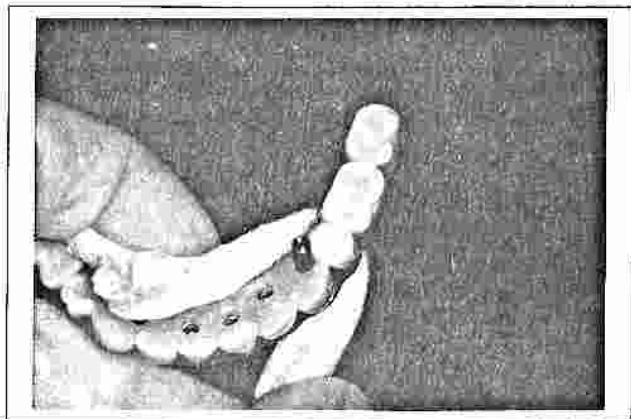


Figure 5c

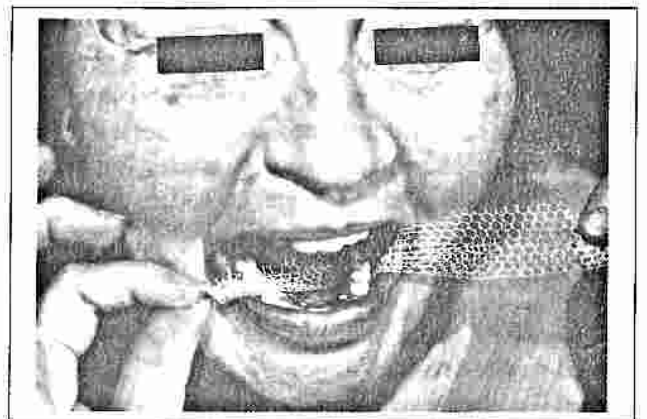


Figure 6c

abutment cylinders, as well as the cervical aspect of the prosthesis (Figs. 7a to 7c). Although the mechanical configuration of the prosthesis and the abutment cylinders generally permits wide spaces ideally suited for the use of interproximal brushes, the hazard of mechanically scratching the titanium surface of the fixtures and abutment cylinders is always present, especially when the brush bristles are held by a braided wire (Figs. 8a to 8d). Ideally an interproximal brush consisting of polished nylon bristles held by a flexible plastic stem would eliminate the possibility of the braided wire scratching the fixtures.

#### *Custom designed cleaning instrument*

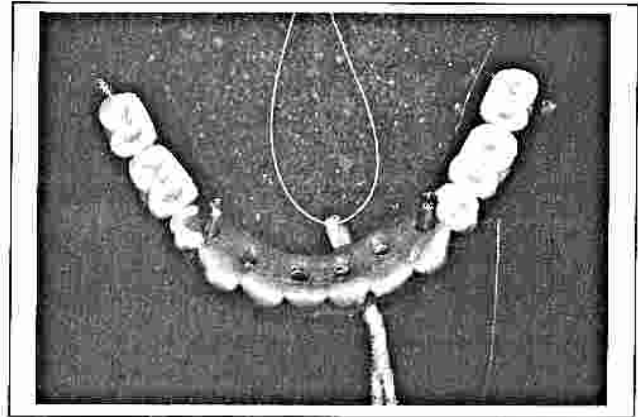
Because patients frequently suffer severe bone loss requiring the tissue integrated prosthesis to extend below the level of the floor of the mouth, lingual cleansing with the end-tufted or conventional toothbrush becomes extremely difficult (Figs. 9a and 9b). Experience has proven that patients often miss cleansing the most lingual aspect of the titanium abutment cylinders with tooth brushing techniques. In order to cleanse this area, a special plastic plaque and calculus removing instrument has been designed.<sup>†</sup> This instrument, made of hard plastic, is soft enough to avoid scratching or denting the titanium fixtures and abutment cylinders. The double-ended instrument provides a semicircular hook on one end and a crescent blade on the other (Figs. 10a and 10b). The internal circumference of both the hook and the blade are identical to the external circumference of the abutment cylinder.

Small "teeth" on the internal curved surface of the hook are essential in removing more tenacious calculus deposits (Fig. 10c). The hook end of the instrument can be rotated around the abutment cylinder to reach difficult access areas on the lingual of the titanium anchors. This end can also be moved in a cervical occlusal direction (Figs. 10d and 11a to 11c).

The crescent blade end of the instrument is designed for cleansing the facial surface of the fixtures and abutment cylinders. Its configuration is designed to function as a vertical scraper on the surface of the abutment (Figs. 12a and 12b). The instrument is capable of cleansing all exposed fixture and abutment surfaces.

In addition to mechanical devices that directly contact the prosthesis and the fixtures, it is beneficial to use a water irrigating device to flush out debris and dislodged plaque.

<sup>†</sup> Fort Washington Dental Lab, Inc., Maple Glen, Pa.



Figs. 7a to 7c Superfloss, inserted with a floss-threading device, can control plaque around the fixtures and abutment cylinders.

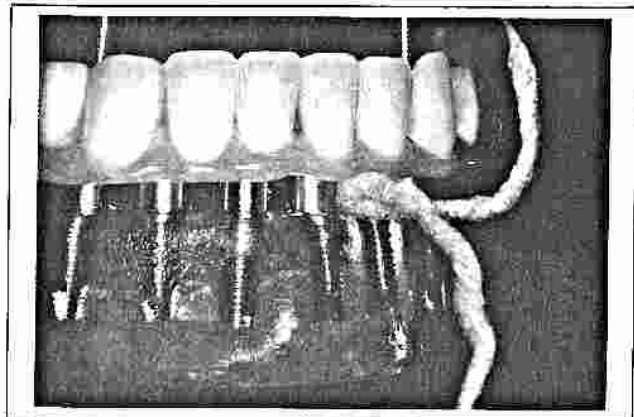


Figure 7b

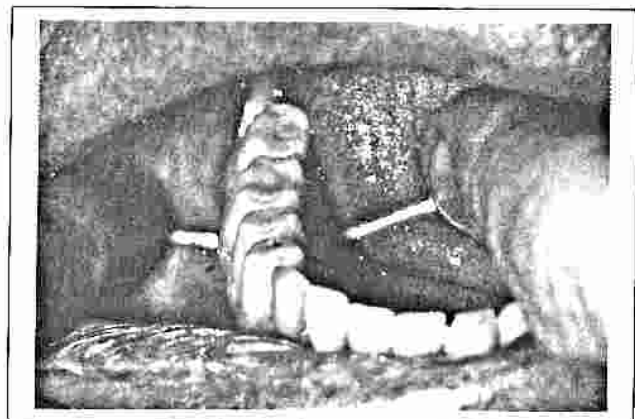
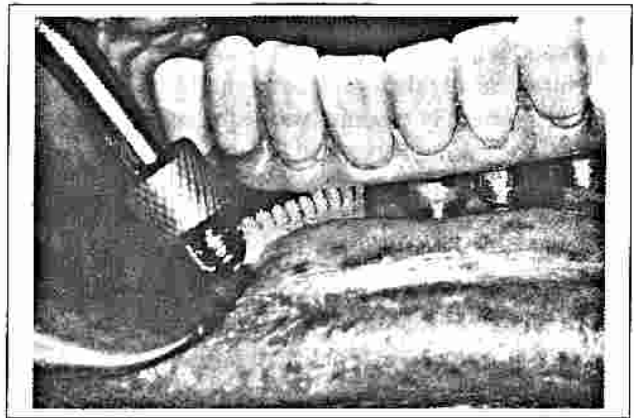
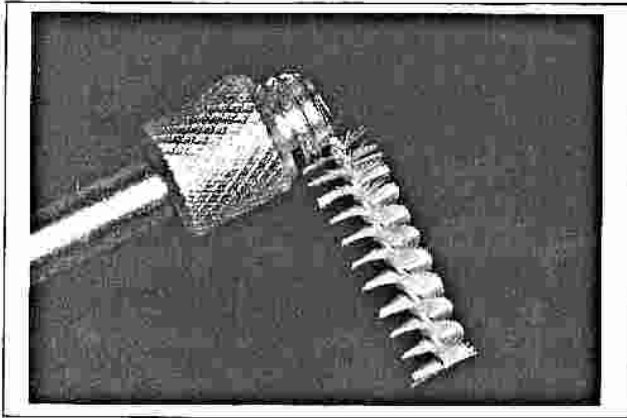


Figure 7c



Figs. 8a to 8d Although titanium is a strong metal, it is easily abraded. Interproximal brushes held with a braided wire must be used with care so as not to scratch the surface of the fixtures and abutment cylinders. The brush can be carefully inserted from the facial direction completely through to the lingual side, or vice versa.

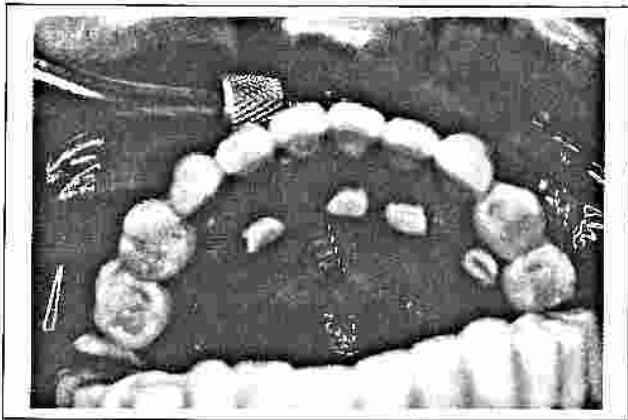


Figure 8c

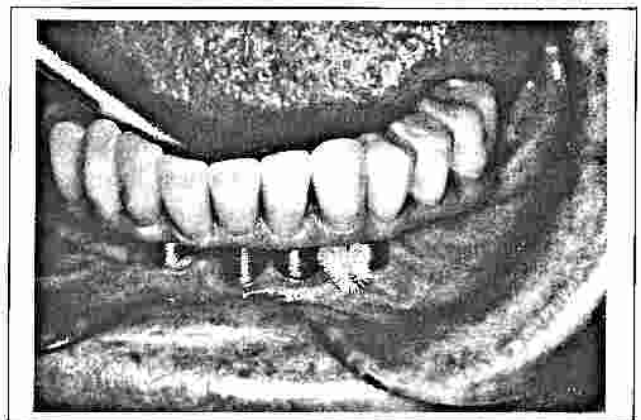
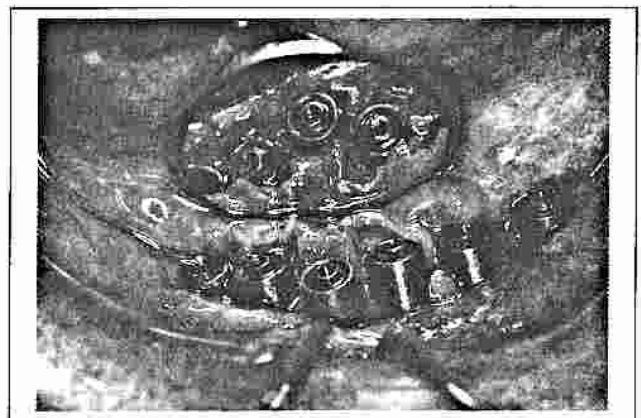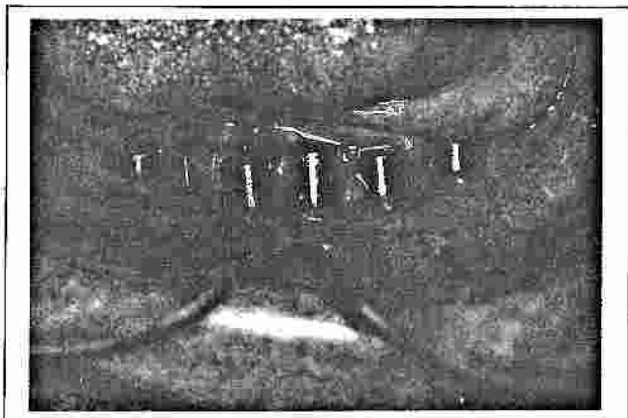

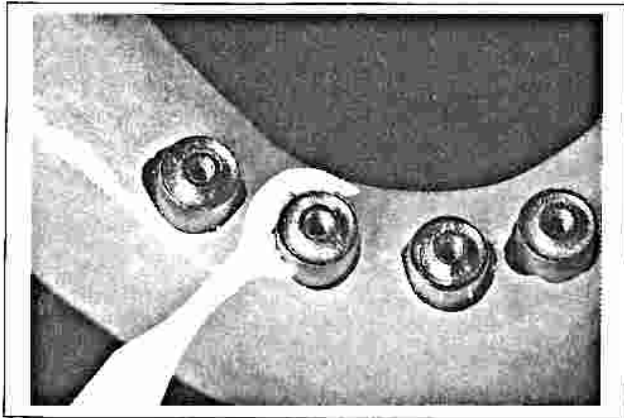


Figure 8d



Figs. 9a and 9b Lingual cleansing with end-tufted or conventional toothbrushes can be difficult when the tissue integrated prosthesis extends below the floor of the mouth. A mouth mirror can be used to deflect the tissue away from the lingual side of the abutment cylinders.



Figs. 10a to 10d The specially designed cleaning instrument shown in these illustrations is made of a hard plastic that will not damage the titanium surfaces. One end of the double-ended instrument has a semicircular hook, while the other provides a crescent blade.




Figure 10c

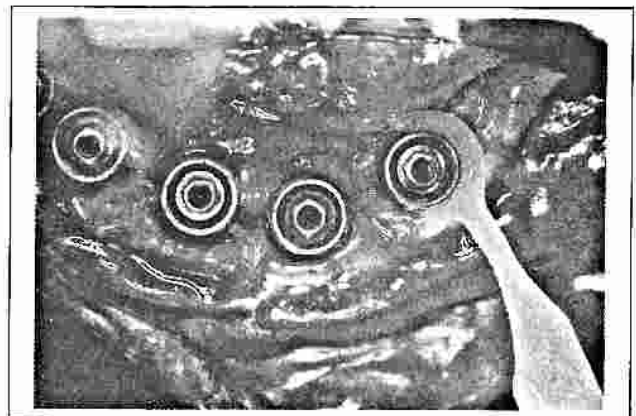
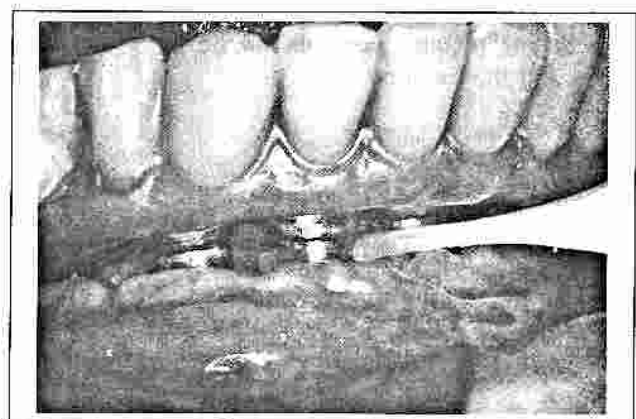
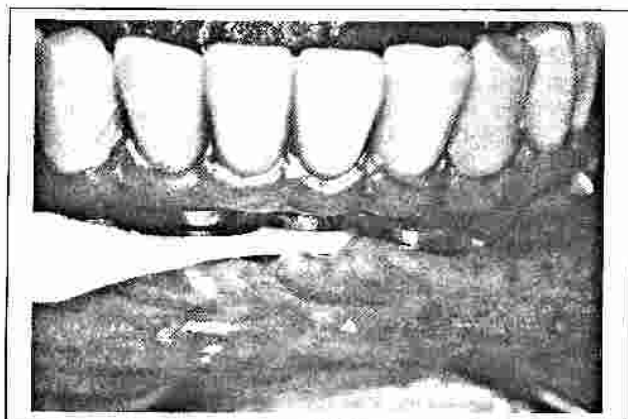

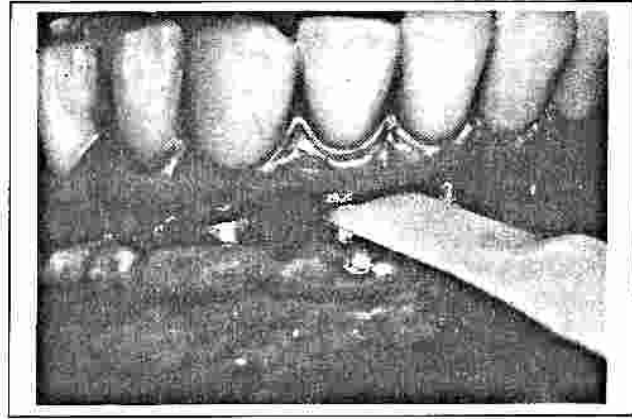
Figure 10d



Figs. 11a to 11c The hooked end of the instrument can be rotated around the abutment cylinder to reach lingual areas of the titanium anchors. A mirror view of the lingual access is shown in Fig. 11c.

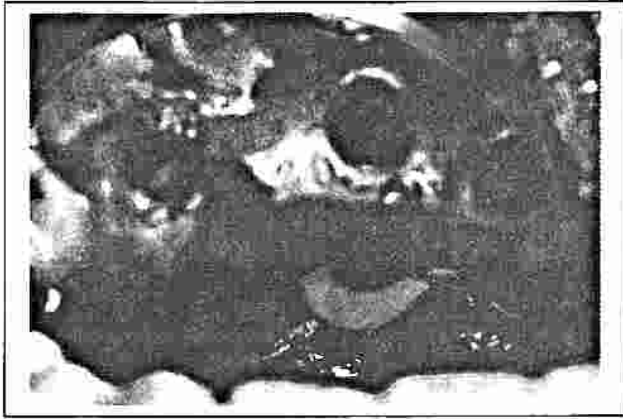

Figure 11c



Figs. 12a and 12b The crescent-shaped end of the instrument is used in an up-and-down scraping motion to remove plaque and calculus.

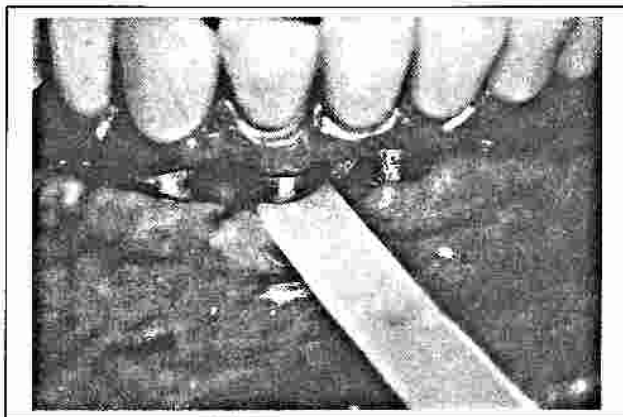


Figure 12b

Mouthwashes, especially those containing the sanguinaria extract, such as Viadent,\* are also helpful in reducing plaque accumulation on both the prosthesis and the fixtures.

\* Vipoint, Inc., Fort Collins, Colo.

### Summary

Maintenance of a plaque-free environment, especially around the abutment cylinders, is important in preserving a functional soft tissue barrier over the osseointegrated fixtures.

Patients treated with osseointegration should have frequent professional hygiene recall visits. During the early years following initial prosthesis installation, patients should return every three months for hygiene maintenance and instruction. No more than six months should elapse between hygiene visits after osseointegration is established.

### References

1. Brånemark et al. Intraosseous anchorage of dental prosthesis. I. Experimental studies. *Scand. J. Plast. Reconstr. Surg.* 3:81, 1969.
2. Balshi, T. J., and Mingleford II, E. B. Maintenance procedures for patients after complete fixed prosthodontics. *J. Prosthet. Dent.* 37:420-431, 1977. □

**BAUSCH**  
Articulating  
Papers since 1953

- samples free -

200  $\mu$



BK 01 blue/BK 02 red

200  $\mu$  and 60  $\mu$



BK 03 blue  
BK 17 blue x-thin  
BK 18 red x-thin

40  $\mu$



BK 09 blue  
BK 10 red  
also available in  
sheets or rolls

8  $\mu$  mylar film



1-sided  
BK 20 black  
BK 21 red  
BK 22 green  
BK 23 blue  
BK 29 white

2-sided  
BK 24 black  
BK 25 red  
BK 26 green  
BK 27 blue

Bausch Dental Co. of America, POB 15 B, San Francisco, CA 94115