

Vol. 4, No. 4 November 1991

PROSTHODONTIC

Insights



World Congress on Prosthodontics, Hiroshima, '91

Thomas J. Balshi

This past September I had the honor of being one of four international specialists invited to present a keynote lecture on esthetics with dental implants at the 4th meeting of the *International Congress of Prosthodontists* in Hiroshima, Japan. This World Congress, the largest gathering of prosthodontists ever, was a joint meeting of the ICP and the Japan Prosthodontic Society. Other members of the keynote panel included Dr. George Zarb, from Toronto, Canada; Dr. Alfred Geering from Switzerland; and Dr. Israel Finger from Louisiana.

The President of the International College of Prosthodontists, Harold Preiskel, London, paid tribute to the spirit of international cooperation that pervades the specialty. President Preiskel presided as president from the first informal meeting of the International College of Prosthodontists in London in 1982, to the founding session of the College in Seattle in 1985, through the highly successful meetings in Interlaken 1987, Toronto 1989 and Hiroshima 1991.

Professor Hiromichi Tsuru, President of the World Congress on Prosthodontics opened the congress by stating that the congress would highlight advanced knowledge and arts in the field of prosthodontics, provide opportunities to further international understanding, and improve communications between col-

continued on page 6

WORLD CONGRESS ON PROSTHODONTICS, HIROSHIMA '91

KEYNOTE SYMPOSIUM

The Integral Implant and Its Use in Maxillofacial Prosthetics

I. M. Finger

Great strides have been made in developing new techniques and materials to meet the needs of patients suffering from acquired and congenital defects. As the predictability of implant therapy improved, this modality of treatment found favor in the field of maxillofacial prosthetics.

The Integral Implant system, which utilizes a hydroxylapatite coating, has been successfully used to aid in the rehabilitation of patients with both intra and extroral defects and has also been placed into radiated sites and autogenous bone grafts. The Integral Implant used in patients with intraoral defects is the same as those commercially available for conventional implant prosthodontic techniques. The implants used for facial prosthetic restorations are custom fabricated. These implants are 4 mm. in diameter and 4 mm. in length with no vents at the distal end of the implant. The implants

continued on page 6

Esthetics and Implant Prosthodontics

G.A. Zarb

Esthetic and functional effectiveness of the many different methods of prosthodontic therapy has largely depended on educated anecdotes and asseveration. This approach has to a very large extent enabled dentists to enrich the quality of their patients' lives. However the trade-off between the need for prosthetic intervention per se, and the biologic price inherent in certain therapeutic endeavors, has demanded strict concerns regarding treatment effectiveness. The technique of implant prosthodontics is certainly one that has focused such concerns, particularly since the concept of osseointegration was introduced to North American dentists in 1982.

Consequently clinical research and opinion in this area have elicited both clinical euphoria and polarization vis-a-vis newer possibilities for resolving the twin objectives of esthetic and functional success. While these objectives may be regarded

continued on page 6

Overdentures Supported by Osseointegrated Implants

A.H. Geering

Treating edentulous patients and wearing dentures are both difficult tasks. The main problem seems to originate in the atrophic edentulous mandible. Therefore, the efforts of the profession focuses on improving the residual ridge by vestibuloplasty, bone surgery, or implants. However, preprosthetic surgery should not be viewed as an alternative to poor prosthodontic treatment. Patients who complain about functional problems may only need new dentures which are properly designed for function and esthetics. In the presented method, classic Swiss removable prosthodontic treatment precedes implant surgery. After a period of adaptation of six months at least, during which the patient has acclimatized to the new dentures, his or her attitude towards implant surgery is discussed. About 90% of the patients concerned are no longer interested in treatment

continued on page 6

Esthetic Prosthodontic Rehabilitation With Osseointegrated Implants

T. J. Balshi

The subject of dental implants adds a new and challenging dimension to dental esthetics. An esthetic dental restoration requires an appreciation for artistic perception and scientifically based biologic response. The prosthetic replacement supported by bone anchored implants must be in harmony with the intraoral anatomy and dentition. It must provide appropriate lip support and complement facial balance. Special esthetic considerations for implant prostheses include the selection of restorative materials for single tooth replacement as well as multiple tooth partially edentulous rehabilitations.

Some of the most challenging esthetic rehabilitations are fully edentulous patients who have not only lost dental function and form but have also experienced the "aging" process which accompanies the loss of occlusal vertical dimension and diminished elasticity of the perioral and facial muscula-

continued on page 6

4th Meeting of the International College of Prosthodontists September 21-23, 1991 Hiroshima, Japan

A Consideration on Load Supporting Mechanisms of the Osseointegrated Implant

H. Sekine *et al*

Eighteen fixtures were installed in the tibiae of two adult dogs to clarify the occlusal load supporting mechanism of the fixture and its surrounding bone. After three months of healing, the metal block which had one loading point and two measuring points on its surface, was fixed to each fixture via an abutment. Up to 2000 gs loads were applied to the loading point in horizontal and axial direction of the fixtures and the displacement by each load was measured on the measuring points.

After measurement, the tibiae were sectioned into blocks 6 mm thick, each containing a fixture. Standardized x-ray photographs of the blocks were taken in axial direction of the tibiae. The bone blocks were prepared for non-decalcified specimens for microscopic examination. Further, the displacements of abutments and gold cylinders themselves were also measured.

The results are summarized as follows.

continued on page 6

Mandibular Arch Width Change During Mandibular Movement

K. Hasegawa *et al*

The object of this study was to measure mandibular flexure in the horizontal plane during opening and protrusive jaw movement. Using the principle that any change in the arch width between the right and left lower first molar teeth reflected flexure of the mandible. Subjects with intact dental arches (excluding third molars) and no evidence of periodontitis were selected for the study. The measurement apparatus consisted of a linear variable differential transformer (LVDT), right and left side intraoral metal caps, and LVDT cap joints. Intraoral caps covered the lower first molars and LVDT cap joints were waxed on working casts for each subject. The waxed caps and LVDT cap joints were cast in a gold palladium silver alloy. The LVDT was placed between right and left side caps through the LVDT cap joints on the working casts. The metal caps were cemented into position in the mouth using polycarboxylate cement.

Mandibular arch width continued on page 6

Effect of Pulsed Electromagnetic Fields on the MC3T-E1 Osteogenic Cell Line—Part Four

Y. Hirose *et al*

The quantitative effect of pulsed electromagnetic fields (PEMF) on cell proliferation of the MC3T3 osteogenic cell line on implant materials was evaluated. The implant materials used were aluminum oxide (single crystal and polycrystal) and titanium. Disks were 10 mm. in diameter and 1 mm. thick. Disks of these materials were placed in 35 mm. diameter culture dishes. The cells were inoculated at 6×10^3 cells per disk on the implant materials, and cultured in 5ml of α -MEM supplemented with 10% fetal bovine serum. The medium was changed every 3 days. The cells were exposed to vertically directed PEMF (3 gauss, 25 μ sec, 100Hz) by placing the culture dishes between the ϕ 70 mm. diameter helmholtz coils. After experimental cultured samples were continuously exposed for 7 days, cell proliferation was measured by the fluorimetric method for DNA microassay. The result of this study was that DNA content in the stimulated group

continued on page 6

Mechanical Properties of Laser Welded Titanium Alloy Prosthesis

K. Kakimoto *et al*

A fundamental study was performed to investigate the applicability of laser welding to titanium alloy prostheses. This author describes the effect of joint geometry on mechanical properties of laser welds from a practical viewpoint. Pulsed Nd:YAG laser was used to weld pure Ti to pure Ti, or to Ti-6Al-4V as well as Ti-6Al-4V to Ti-6Al-4V. In the case of the similar welding of pure Ti and Ti-6Al-4V, strengths of laser welds were almost equal to those of their base metals. In the dissimilar welding of pure Ti to Ti-6Al-4V, a large part of the laser weld fusion zone exhibited acicular microstructure, and the hardness of the weld metal was higher than that of Ti base metal but lower than that of Ti-6Al-4V alloy. The strength of laser welds of pure Ti to Ti-6Al-4V was higher than that of pure Ti base metal. Tensile loads were dependent upon laser irradiation conditions and lap ratio (laser-welded area) of laser spot welds, and were satisfactorily high if proper welding conditions were selected. No cracks were present in any laser weld, and it was therefore

continued on page 6

EMG Activity of Masticatory Muscles Before and After Osseointegrated Implant Dentures

Y. Kobayashi *et al*

There are many reports on the residual rate, pressure sense of peripheral tissue, and occluding strength, in evaluating the treatment efficacy of osseointegrated implant dentures, but very few reports on masticatory movement. To evaluate the degree of recovery in masticatory function when osseointegrated implant dentures were used, the muscular activities of masticatory muscles were investigated.

Ten osseointegrated implant denture patients ages 58-74, 6 males, 4 females, were asked to chew boiled fishpaste on their habitual chewing side, and EMGs of temporal and masseter muscles were recorded. The integral values of muscular activities of masseter and temporal muscles for the 5th to the 14th stroke were calculated, and the results obtained before the implant dentures were compared with those obtained one month and one year after the implant dentures.

The amount of muscular activities in both masseter and temporal muscles in-

continued on page 6

Evaluation of Heat Injury of Peripheral Bone Tissue Caused by the Heat Generation During Bone Drilling By Microradiographic Technique

N. Minamidate *et al*

To clarify the effect of heat generated upon the peripheral bone tissue during bone drilling for dental implants, the relationship between bone heat injury and its healing mechanism was investigated in vivo on the premolar and molar region of the mongrel dog mandible by performing bone drilling with coolant (control group) and without coolant (test group). Following bone drilling, an implant was embedded into the prepared cavity. Observations were made on day 1, 7, 14, and 30 postoperatively and microradiographic studies were performed for each sequence to depict the changes in the healing phenomena.

The results indicated a delay in healing at 7 and 14 days after implantation in the test group. After 30 days bone regeneration occurred in both test and control groups. These results suggest that lack of a coolant system in the test group caused delay in healing during the first two weeks.

Production of Accurately Fitting Full-arch Implant Frameworks: Part I - Clinical Procedures

G.E. Goll

Osseointegrated implant frameworks for full and partial fixed partial dentures should fit passively on the fixtures. The *author's experience* has shown that perhaps 25% of "his" metal frameworks for full arch restorations do not fit accurately. This article defines and discusses some of the parameters involved in obtaining a one-piece, full arch metal casting that accurately fits Branemark System osseointegrated implants, including impression techniques, verification of fit of plastic framework, alternatives if the plastic framework does not fit, casting procedures and metal selection.

Eden et al tried to standardized the mold conditions for producing single unit porcelain fused to metal crown and fixed partial denture castings. They addressed the following parameters: casting ring size, asbestos liner, position of pattern, investment type, powder-liquid ratio, spatulation, setting time before casting, burnout sequence, removal of casting ring from oven, casting machine, melt soak time, and melting temperature of the oven. Their findings showed Ni-Cr castings to be consistently undersized and precious metal castings to be oversized. Because of the complexity of the casting process it is not surprising that casting distortions may arise.

Each step in the fabrication of a one piece metal implant framework casting is of critical importance. The following suggestions will improve the accuracy of the casting

and reduce some of the possible errors:

1. Use machined parts because their intimate fit and contact is more predictable.
2. Check the fit of gold cylinders and transfer copings onto the abutment cylinders at the first clinical appointment following the second stage surgery to ensure that all of the components fit together properly.
3. Cover the abutments with cover caps to prevent debris from accumulating on the abutment surface.
4. Double check the accuracy of the master cast by using an acrylic resin fixed partial denture facsimile before proceeding to the casting of the framework. Construct the acrylic resin fixed partial denture the night before it is needed and leave it bolted down overnight.
5. Use new guide pins for the laboratory stages and when checking the fit of the cast metal framework intraorally. Test the fit of the casting by using only one screw at one end of the framework.
6. Clean the fitting surface of each gold cylinder with wax solvent before investing.
7. Cast the metal framework in one piece if possible.
8. Cover the cylinders with stainless steel protector caps or duplicate brass analogues to protect the surface when polishing the framework.
9. For full arch castings use 4 mm gold cylinders because the framework will have more bulk and sturdiness. The acrylic resin try-in framework will similarly be less likely to distort.

Prosthetic Dentistry 1991, 66:377-84

The Use and Fabrication of a Self-retaining Surgical Guide for Controlled Implant Placement: A Technical Note

S. Parel & J. Funk

The use of a surgical guide to control and predict final implant position can be critical in establishing both the functional and esthetic basis for a variety of fixed or removable restorations. This paper describes a technique which allows for the simple creation of a self-retaining facial veneer guide that eliminates the need to stabilize the prosthesis during the surgical procedure, results in a relatively clear and self-retentive guide which will limit the angulation of the implant in a facial and mesiodistal direction, and leaves surgical access and visibility unimpaired. This design is more convenient to use than previously described occlusal extension splints, and it maintains the concepts for ideal fixture placement that have proven so valuable in creating both a functionally and esthetically uncompromised prosthesis supported by implants. Int J Oral Maxillofac Implants 1991, 6:207-210.

Membrane-Induced Bone Augmentation at Titanium Implants. A Report on Ten Fixtures Followed From 1 to 3 Years After Loading

C. Dahlin et al

It is known that exposed threads of the implant may cause mucosal disorders that might lead to a total loss of the implant in some advanced cases. This study reports the clinical experience of the first ten consecutive implants combined with e-PTFE membranes (GTAM) at the Branemark Clinic.

Since connective tissue formation occurs at a rapid rate and often creates a hindrance to osteogenesis, a membrane was placed in such a way that a secluded space into which only the presumably slower migrating osteogenic cells could enter was created. The outcome of the treatment was found to be successful as new bone was created around all test fixtures. Complete bone coverage of exposed implants was obtained after a six week healing period. The controls showed considerably less bone regeneration even after 15 weeks. The bone gain, ranging between 0.5 and 3.0 mm, corresponded to approximately one to five threads of the fixture and was considered to be crucial to the long term prognosis of the fixtures.

No complications were observed after loading of the membrane treated implants with fixed prostheses. There were no exposed threads or mucogingival reactions. This finding indicates that the newly generated bone seemed able to bear the stress and tensile forces that were transferred to it via the loaded fixtures. This study gives evidence that the membrane technique is a useful tool for establishing new bone in conjunction with the placement of titanium implants in patients.

Int J Periodont Rest Dent 1991, 11:4



Oral Hygiene Video For the Implant Patient

Educate your patients with a detailed film of home care techniques for implant patients.

Reinforce the hygiene instructions you have already shown your patients.

Optimize the time that your hygienist spends with home care instructions.

Legal documentation is verified by patient viewing home care video.

1 Video \$25.00 5 Videos \$100.00

Return _____

Address _____

Please mail check and form to:

Institute for Facial Esthetics

467 Pennsylvania Avenue, Fort Washington, PA 19034

Tel: 215-643-5881 • Fax: 215-643-1149

Endosseous Cylinder Implants in Severely Atrophic Mandibles

Triplett *et al*

A retrospective study was undertaken to evaluate implants in patients with severely atrophic mandibles whose greatest anterior mandibular height was 10 mm or less as measured from standardized lateral cephalometric radiographs. To be included, patients had only implants that were located anteriorly between the mental foramina. Also, each patient had been wearing an implant supported prosthesis for a minimum of 1 year. Twenty-eight patients, 21 females and 7 males, fit the criteria for this study. The patients ranged in age from 30 to 78 years (mean 59) and the follow up ranged from 15 to 62 months (mean, 33).

In the 28 patients included, maximum anterior mandibular height ranged from 5-10 mm. A total of forty-six 7 mm implants and eighty-four 10 mm implants were used to restore the teeth of these patients. The prosthetic reconstruction consisted of 9 fixed prostheses and 19 overdentures. Supporting the fixed prostheses were eleven 7 mm implants and thirty-four 10 mm implants. No fixed prosthesis was attached to 7 mm implants alone. Thirty-five 7 mm and fifty 10 mm implants were used to support the cast substructures for the overdentures. Success rates for the 7 mm and 10 mm implants were 96% and 93% respectively with an overall success rate of 94%.

One 10 mm implant was removed from a patient 5 months after placement because of a mandibular fracture. Radiographically, the fracture line travelled directly through the implant site. This patient had four remaining implants that were unaffected by the fracture. Following successful treatment of the fracture and an adequate healing period, a cast gold bar and an overdenture with clips was fabricated.

One of 9 fixed restorations failed, and 1 of 19 overdentures was unsuccessful, yielding success rates of 90% and 95%

respectively.

Major complications included a complete mandibular fracture in one patient with a mandible that measured 9 mm in height, and a partial mandibular fracture in a second patient whose mandible was 6 mm in height. A third patient had a transient bilateral mental nerve hypoesthesia.

The patient who had the complete mandibular fracture that required removal of an involved implant had advanced osteoporosis and had suffered other bony fractures previously. This mandibular fracture was treated with open reduction via an extraoral approach and application of a compression bone plate. Masticatory function was restored using the four remaining successful implants and an overdenture. While osteoporosis is not a contraindication to dental implant therapy, poor bone quality may have led to the development of these fractures.

Minor complications were noted in five patients. Gingival hyperplasia developed around abutments in three patients, prolonged pain and edema occurred in one patient in whom the inferior border of the mandible was completely penetrated by implants and formation of a hematoma under the mucoperiosteal flap was noted in one patient. The hyperplastic inflammatory tissue observed was related to poor oral hygiene. Following a local gingivectomy in the indicated areas and improved hygiene measures, the gingival hyperplasia resolved.

When the implants were placed in mandibles of 7 mm height or less, an attempt was made to engage or even slightly penetrate the cortical bone of the mandibular inferior border. After the healing period, radiographs commonly showed bone covering the inferior portion of the implants that penetrated the inferior border. Since the tensile, compressive, and bending strengths of cortical bone are seven or more times greater than that of cancellous bone, the stability afforded by engaging the extra layer of cortical bone probably contributed

continued on page 6

The Effect of Piezoelectric Film on the Bone Repair in Rats

S. Chiba *et al*

The effect of the electrical stimulation on bone repair by using Piezoelectric film was investigated. The film was Vinylidene Fluoride-Trifluoroethylene copolymers (VDF/TrFE), and generated piezoelectricity when stretched, bent and compressed. A drilled bone hole (02.0 mm) was prepared in 40 Wistar strain male rats in the right femoral diaphysis. VDF/TrFE Film (10mm. X 5 mm.) was implanted round the bone over the drilled hole. Subjects without films were used as controls.

The femur of the rat which was given an injection of calcein and oxytetracycline double labeling, was examined histologically by Villanueva bone staining on the 7th, 14th, 21st and 28th day after the operation.

The results were as follows. 1) The surface of VDF/TrFE Film was surrounded with connective tissue. A little inflammatory infiltration was found in the edge of the film. 2) In the experimental group the hole drilled in the femur was filled with incompletely mineralized bone formed about the 7th to 14th day. On the other hand, the holes in the control group filled with osteoid and low density bone. 3) VDF/TrFE Film accelerated new bone formation in the drilled holes.

World Congress on Prosthodontics, Hiroshima, '91

The Comparative Accuracy of Implant Impression Procedures

A. H. Fenton *et al*

Several dental implant impression procedures have been advocated. This study compared the accuracy of implant casts produced by four different impression techniques. A standard mandibular metal implant framework was made. A metal model of a mandibular arch with five Nobelpharma implants was then constructed to fit to it. Fifteen casts of the metal model were made with each of four different impression techniques. The fit of the standard implant framework to each cast was assessed manually. The difference between passive seating and "screw-tight" fit was measured at 30x with a travelling stage microscope. Results:

Method	(n=15) Bad Fit Gap	(Gap (x + SD)
a. Acrylic splint and alginate	0	4.17 + 1.76
b. Acrylic splint and polyether	0	4.17 + 1.83
c. Polyether only	4	11.0 + 4.41
d. Replaceable copings in polyvinylsiloxane	8	21.6 + 18.57

The manual assessments of passive fit correlated with the gap measurements. When acrylic was used to splint-transfer copings in an impression, all casts were acceptable and more accurate than the best of the other procedures.

Going West... for the Academy Meeting in Vancouver?

Why not make a week of it!

Plan to Attend the Advanced
Osseointegration 'Ski/Course

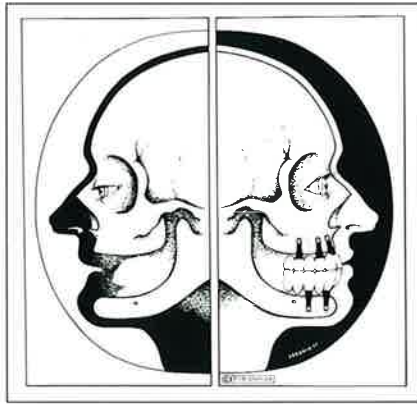
Place: Chateau Whistler Resort
Whistler, British Columbia

Dates: Saturday, February 22 to
Wednesday, February 26, 1992

Presenters: Thomas J. Balshi, D.D.S.
Robert A. Jaffin, D.M.D.
Stephen M. Parel, D.D.S.
Barbara Lord, R.D.H.
Bob Winkelman, C.D.T.
Ken Orth, C.D.T.

Contact: Institute for Facial Esthetics
Tel: 215-643-5881
Fax: 215-643-1149

For: Doctor \$725
Technician 325
Hygienist/Assistant 125



Reconstruction with tissue-integrated prostheses in partial or complete edentulism provides a structural and functional restitution to a state similar to the dentate situation also preventing further bone resorption. In addition to the local oral rehabilitation effects there are also positive consequences for the entire psychosocial condition of the previous oral invalid. (From Brånemark et al.)

Early Failures in 4,641 Consecutively Placed Brånemark Dental Implants: A Study From Stage I Surgery to the Connection of Completed Prostheses

Friberg et al

This study comprised 4,641 Brånemark dental implants which were retrospectively followed from stage 1 surgery to completion of the prosthetic restorations. The implants were placed during a 3 year period (1986-1988) in 943 jaws, representing 889 patients with complete and partial edentulism. The jaw and sex distribution revealed a predominance of mandibles (564/943) and females (534/943). The mean age of the patients was 57.5 years (range 13 to 88 years) at implant placement. Only 69 (1.5%) fixtures failed to integrate, and most losses were seen in completely edentulous maxillae (46/69) in which the jaw bone exhibited soft quality and severe resorption. A preponderance of failures could also be seen among the shorter fixtures (7 mm). A majority of the mobile implants were recorded at the abutment connection (stage 2) operation (48/69).

Jaw shape and bone quality seemed to be the two most important factors for early fixture failure in this study. While the same factors may be significant in the maintenance of osseointegration during functional periods, this was not revealed by the present results. This observation will be the focus of other investigations.

Int J Oral Maxillofac Implants 1991;6: 142-146.

The Prosthodontics Intermedica Philosophy of Professional Collaboration

As you know all too well, few medical conditions are as insidiously disabling as full or partial edentulism. Though not life-threatening, edentulism exacts a toll—in loss of function, loss of self-image, and indeed loss of maxillofacial bone—that can be incalculable.

Conventional dentures are, at best, a poor substitute for natural teeth—one which many patients never learn to tolerate. Even conventional bridgework can compromise the viability of healthy teeth, leading to further tooth loss.

This is why, when the opportunity to pursue postgraduate training with Dr. P-I Brånemark in his system of osseointegrated implants was first presented to me nearly a decade ago, I eagerly pursued it. Since then, I have had the privilege of treating thousands of patients, with a remarkable success rate of over 95%.

This dramatic success—and the equally dramatic improvement in the quality of life I have seen the Brånemark System® make for patients—was the impetus behind the founding of Prosthodontics Intermedica as a resource for dental practitioners throughout the northeastern United States.

If you are unfamiliar with Prosthodontics Intermedica, please take a moment to read why many of your colleagues have used this resource to make their own practices more successful.

Dentists who do not already perform implant procedures find that PI enables them to expand the range of solutions they can offer their patients, and patients appreciate this knowledgeable recommendation.

Practitioners whose practices focus on other areas of dentistry find they are able to better concentrate on their specialties while still providing their patients a full range of services and advice. Even those who are already performing implants may turn to PI for patients who present special challenges.

When patients come to PI for Brånemark System® osseointegrated implants, you can be assured that they will be treated by experienced specialists—including doctors, surgical assistants, hygienists, and technicians—thoroughly trained in all aspects of this procedure, to assure the highest degree of success.

Patients can also be confident that the full spectrum of their ancillary needs—from specialized oral hygiene to speech therapy—will be met by a multidisciplinary treatment team.

Most importantly, we respect the role of the patient's primary dental care provider as a full member of the treatment team—receiving full communication from PI specialists and assisting in the procedure to the extent they wish. Many collaborating practitioners have remarked on the positive effect PI has had on patient relationships.

Prosthodontics Intermedica offers a wide range of educational services to the dental community—including seminars, preceptorships, and access to an extensive international database of information on osseointegrated implants. I hope you will take the opportunity to visit Prosthodontics Intermedica personally. To request more information, call 215-646-6334.

World Congress (continued)

leagues who share a special scientific interest.

Over 2,300 prosthodontists from 35 countries attested to the international flavor. The numbers were further swollen by those involved in a large Trade Show and those accompanying the delegates.

Presentations were arranged into four main symposia and two separate lectures. There were in excess of one hundred oral and poster presentations, and despite the number of parallel programs, all were well attended.

The social program included the Presidential Reception with its lavish display of exquisite Japanese foods and an elegant black tie dinner dance. A three hour boat trip around the Inland Sea culminated the meeting. The calm sea, island and capes were an ideal setting for affirming new friendships and saying good-byes with promises to meet again.

World Congress on Prosthodontics was the first of its kind in Asia and was considered by all to be an overwhelming success in scope and scale. The next meeting of the International College of Prosthodontists will be held in Venice, September 24-26, 1993.

Esthetics and Implant (continued)

separately for reasons of convenience, they are like two sides of a coin and an integral part of a therapeutic currency. It is now possible to look back and take stock of the merits of implant prosthodontics as a viable alternative to traditional therapies. This retrospective assessment will be carried out in the context of those criteria which comprise optimal functional and esthetic restorations with minimal risk of morbidity.

Educational Opportunities Sponsored By The Institute For Facial Esthetics— Pennsylvania's First Official Branemark Training Center

Prosthetic Training Program For The Branemark Method Of Osseointegration

*Two Day Course, Includes Hands-on Instruction

Apr. 3-4, 1992
Jul. 17-18, 1992
Nov. 20-21, 1992

*All courses are AGD accredited

Advanced Osseointegration Ski Course:

Feb. 22-26, 1992
Whistler, British Columbia

Information:
215-643-5881

Overdentures (continued)

with osseointegrated implants. Generally, two implants are placed in an optimal relation to the denture base and the morphological aspects of the residual ridge in the anterior region between the mental foramina. For denture retention, spherical anchors or a clip bar are mounted on the implants. Between 1984 and 1990, a total of 256 implants have been placed in 108 mainly elderly patients (average age 65 years). Six implants failed (2.3%).

Esthetic Prosthodontic (continued)

ture. The correction of skeletal deficiencies and treatment of facial tissues in conjunction with implant rehabilitation is a multidisciplinary approach to improved dental and facial esthetics. The stability of the osseointegrated implant provides excellent support for maximum esthetic opportunity resulting in both physical beauty and inner peace for the patient.

Consideration (continued)

When horizontal loads were applied to the fixtures, small amounts of linear rotations corresponded to the loads. The amount of rotation varied greatly according to the situation of fixtures to supporting bone. When axial loads were applied however all fixtures barely indicated displacement.

Mandibular Arch (continued)

was found to decrease during opening and protrusive jaw movements. Comparison of arch width change with millimeters of jaw opening showed marked acceleration of change as position approached maximal opening. Mandibular arch width decrease plotted against protrusion showed an immediate change in arch width at the beginning of protrusion.

Effect of Pulsed (continued)

had a significant increase of 30-40% ($P < 0.001$, t-test). *PEMF stimulation promoted osteogenic cell proliferation on the implant materials.*

EMG Activity (continued)

creased significantly both after one month, and after one year of implant denture use. However, between one month and one year the difference was insignificant. From these results it was clear that the amount of muscular activities varied conspicuously and increased significantly after wearing osseointegrated implant prostheses.

PROSTHODONTIC

Insights

is published by Prosthodontics Intermedica and distributed without charge to qualified individuals. Please request a subscription on your organization's letterhead.



Fixed, Removable, Maxillofacial,
and Implant Prosthodontics

Prosthodontics Intermedica
467 Pennsylvania Avenue
Fort Washington, PA 19034 U.S.A.
Telephone: 215-646-6334

Endosseous Cylinder (continued)

to the high success rate in these severely resorbed jaws.

The majority of patients in this study were limited to the use of a removable prosthesis. Most of these patients selected a removable prosthesis because of financial constraints. Only one removable prosthesis failed thus far. The patient was a 52 year old white female with Crohn's disease. The patient functioned well for over 4 years with a cast gold bar and an overdenture with clips.

The preliminary results of this study indicate that endosseous cylinder implants are useful and effective for the rehabilitation of mandibles that are 10 mm or less in maximum anterior height. These implants may also be used in selected patients whose mandibles are less than 7 mm in maximum anterior height, even without bone augmentation procedures. However, additional long term studies are needed to evaluate these implants when used for the rehabilitation of *extremely resorbed jaws*.

Int J Oral Maxillofac Implants 1991, 6:264-269

Integral Implant (continued)

have been used to provide the retention and stability required to provide an esthetic and functional restoration.

Mechanical Properties (continued)

found that laser welding would be a useful technique for prostheses framework construction.