



*Thomas J. Balshi,
D.D.S., F.A.C.P.*

From Blade Vent to Subperiosteal to Osseointegration: One Patient's 19 Year Experience

The patient had a long history of complex dental care beginning in 1975 with a failing blade implant in the mandibular right posterior and advanced periodontitis associated with the remaining teeth (Fig 1). The blade implant survived for three years (1978). The blade and the remaining teeth were lost in 1986. After eight years of intolerable denture wearing, the patient underwent subperiosteal implant treatment (Fig 2). The subperiosteal was chronically infected and painful in function. The patient had tolerated this condition for seven years when he presented to

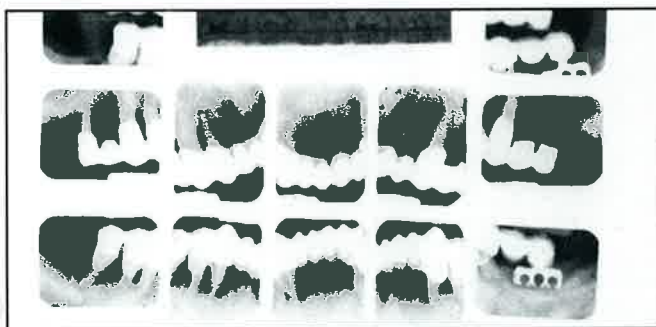
Prosthodontics Intermedica for evaluation and treatment in August 1993 at age 72. He was in excellent health and was very nutritionally aware, avoiding red meat and high cholesterol intake. He was also an avowed athlete and a long time distance runner.

His oral status was totally edentulous in the maxilla restored with a complete removable denture. The mandibular arch had an infected subperiosteal implant supporting an overdenture. The mobility of the subperiosteal implant contributed significantly to the spread of infection

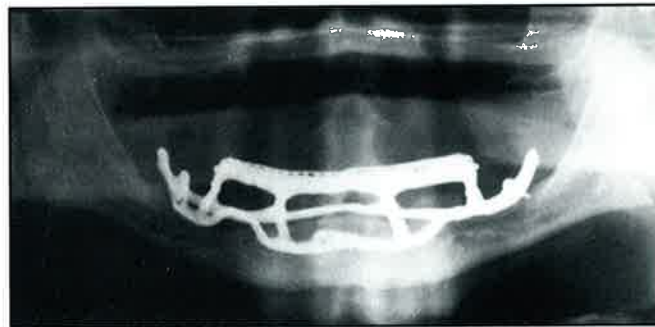
throughout the entire arch. A pronounced malocclusion (Fig 3a) with contact only in the mandibular left molar area added additional insult through excess loading forces.

On September 1, 1993 the subperiosteal implant was removed under local anesthesia. All of the granulation tissue and suppurative material was debrided from the surgical site (Fig 3b). The patient healed uneventfully and ten days later a second surgical procedure was performed for the placement of six Brånemark implants in the mandible and eight

(Continued on Page 2.)



*Figure 1:
1975 radiograph illustrates the failing blade implant and advanced periodontal disease.*



*Figure 2:
Panradiograph of the subperiosteal.*

From Blade Vent to Subperiosteal to Osseointegration: . . .

(Continued from Page 1.)

Brånemark implants in the maxilla (Fig 4a). The patient again healed uneventfully following the standard Brånemark protocol for postoperative wound healing. To accelerate the healing process the patient avoided wearing the mandibular denture. In December 1993, stage II surgery was performed in the mandibular arch and the same day a nonremovable conversion prosthesis was fabricated. Two weeks later the final prosthesis for the

mandibular arch was completed.

Second stage surgery was performed in April 1994 for the maxillary implants. All but one implant appeared firmly osseointegrated. The implant in the area of #16 was mobile and removed at the time of the stage II surgery. The conversion prosthesis was constructed the same day. The final porcelain fused to gold fixed prosthesis was delivered two weeks later (Fig 4,b,c,d,e).

Following prosthesis delivery, clinical evaluation revealed an excellent mucosal response to the titanium implants. Radiographically, bone levels were maintained as expected with

negligible marginal bone loss evident.

Six months following prosthesis delivery the patient expressed his extreme satisfaction with both esthetics and function, noting that his mouth was pain free for the first time since he began his implant treatment in the early 1970's (Fig 5a & 5b).

The transition from failing blade-vent and subperiosteal implant treatment to successful osseointegrated implants is based on numerous clinical and laboratory studies. Brånemark implants have proven to be the treatment of choice for "permanent tooth replacement" based on 30 years of clinical success.

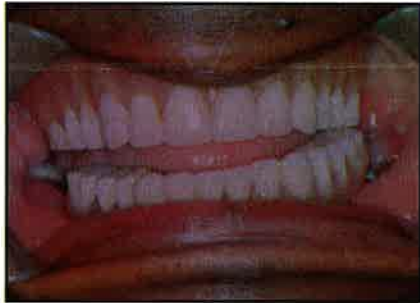


Figure 3a:
Severe malocclusion with only molar contact on the left side.

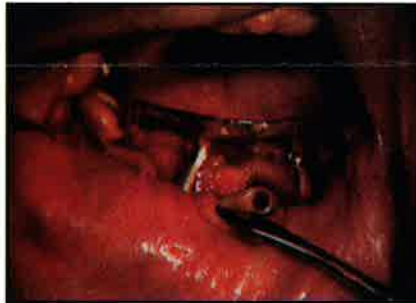

Figure 3b:
Clinical view of the infected subperiosteal.

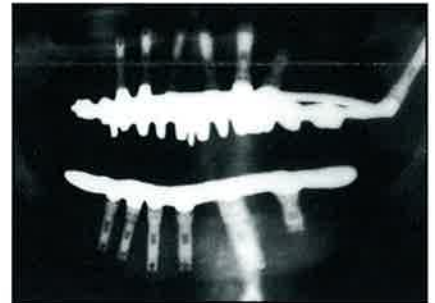


Figure 4a:
Panradiograph of final reconstruction with seven Brånemark implants in the maxilla and six in the mandible.

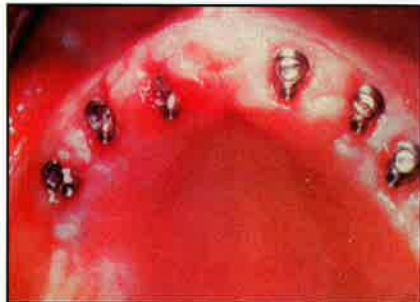

Figure 4b:
Six Brånemark angulated abutments were used in the maxilla to redirect the long axis screw holes through the lingual of the prosthesis.

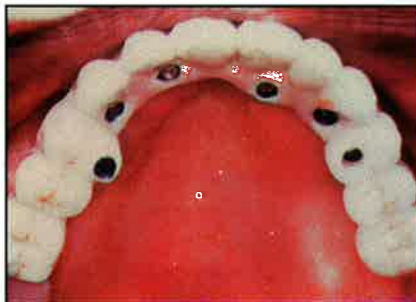


Figure 4c:
Palatal view of the porcelain fused to gold tissue integrated prosthesis.

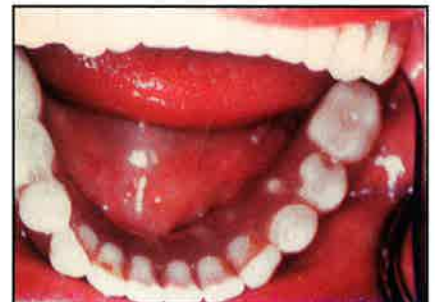

Figure 4d:
Occlusal view of the mandibular fixed tissue integrated prosthesis constructed of acrylic with gold substructure.

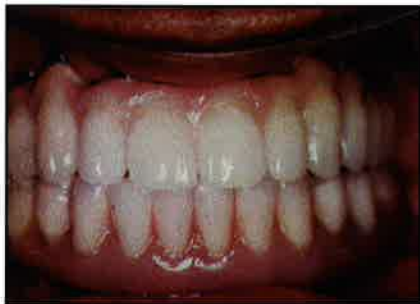

Figure 4e:
Final implant reconstruction with fixed prostheses in both the maxilla and mandible establishing a Class I occlusion.

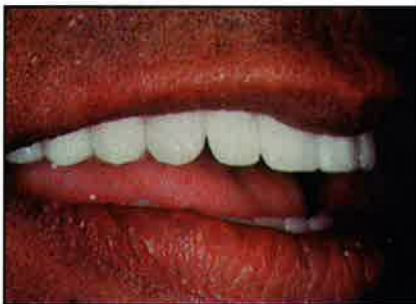

Figure 5a & b:
A lateral profile view demonstrates excellent lip support and dental esthetics.

Autogenous Bone Grafting of Bone Defects Adjacent to Implants Placed into Immediate Extraction Sockets in Patients: A Prospective Study

W. Becker, B. Becker, G. Polizzi, C. Bergstrom

A total of 54 implants were placed in immediate extraction sockets of 30 partially edentulous patients. All defects received autogenous bone grafts harvested from bony ledges adjacent to the extraction sites and from drill flutes used to prepare the implant recipient sites. Twenty-eight implants were placed entirely within the alveoli, while 26 implants were placed within extraction sockets but also had buccal dehiscences. The mean defect bone fill was 5.6 mm for implants placed entirely within alveoli and 4.7 mm for defects that were in alveoli but with buccal dehiscences. Analysis of the 50 evaluated implants showed that at 2nd stage surgery there was an average of less than one implant thread exposed. The mean

defect bone fill compares favorably with that reported in the multicenter study, in which immediately placed implants were augmented with ePTFE barriers.

The results indicate that bone defects adjacent to implants placed into immediate extraction sockets and grafted with autogenous bone heal with significant quantities of bone. At abutment connection, all implants were immobile, symptom-free, and restorable. To date, 50 implants have been loaded with no loss of implants.

Within the limits of this study, implants placed into immediate extraction sockets will heal predictably.

Int J. Oral Maxillofac Implants 1994;9:389-396

A Comparison of Impression Techniques for the CeraOne Abutment

Schmitt et al

The ability to register accurately the position of the implant abutment is critical to the success of any prosthodontic treatment. The use of autopolymerizing resin (Duralay) to lute the implant transfer coping to the tray has been advocated by some authors, as well as by the Nobelpharma manual. Does the distortion of the resin on polymerization affect the accuracy of the final impression?

Comparing the two impression techniques recommended for the CeraOne implant system, the following conclusions can be drawn. The more accurate technique is to pick up the plastic impression coping in the impression material, without luting it to the tray with autopolymerizing acrylic resin. When the plastic impression coping is luted to the tray with the autopolymerizing resin, significant distortion is introduced into the impression.

J Prosthodont 1994;3:145-158

Single-Stage Surgery for Rehabilitation of the Edentulous Mandible: Preliminary Results

P. Henry & I. Rosenberg

Rehabilitation of the edentulous mandible by implant supported bridge-work is generally carried out as a two-stage surgical procedure. However, some patients with a genuine fear of surgery are discouraged from treatment because two surgical procedures are involved. Patients requiring general anesthesia for surgical procedures may decline treatment if they are significantly medically compromised from an anesthetic point of view. And patients referred from remote geographical locations may find it logistically impossible, from a cost effectiveness point of view to fulfill a treatment plan scheduled over 6 to 8 months with multiple visits.

This pilot study was undertaken to evaluate the predictability of a single-stage surgery with controlled immedi-

ate loading of the nonsubmerged implants with an intent to simplify the logistics of treatment and provide cost/benefit advantages.

Five edentulous patients received 6 standard 3.75 mm diameter implants, installed between the mental foramina, with 4 designated to be nonsubmerged and 2 submerged (sleeping). The submerged implants were to act as therapeutic reserve in the event of subsequent failure of any of the nonsubmerged implants. Every effort was made to achieve bicortical stabilization by engaging the inferior border of the mandible to maximize initial stability. All inserted implants demonstrated firm anchorage throughout the 2 year observation period and no mobility was detected when tested manually with the bridges detached.

The modified dentures were relined with tissue conditioner over the entire surface to ensure maximum distribution of masticatory load over the available support, both implants and posterior denture bearing area. This subjected the implants to controlled loading during the early phases of osseointegration. Careful occlusal adjustment ensured adequate load distribution. Strict adherence to the plaque control regimen was mandatory.

After a 2-year follow-up, the study concluded that immediate loading of adequately installed, nonsubmerged implants, by reinsertion of a modified denture, does not appear to jeopardize the process of osseointegration in the anterior mandible. Clinical performance and prognosis of the procedure compare favorably with the traditional method of leaving the implants submerged for a healing period between implant installation and abutment connection.

Pract Perio Aesthet Dent 1994;6:15-22

Implant Placement in Combination With Nerve Transpositioning: Experiences With the First 100 Cases

Bo Rosenquist

Implant placement posterior to the mental foramen is a problematic surgical procedure in patients with extensive bone resorption. Bone quality in the posterior mandible is usually thinly trabecular, making it less suitable for implant placement. The aim of this study was to calculate implant survival in a large clinical sample, to record marginal bone loss, to examine changes in neurosensory function, to record perioperative and postoperative complications, and to suggest indications and contraindications for the procedure.

Seventy-two consecutive patients referred for implant placement posterior to the mental foramina were included in the study. In 44 of the patients, nerve transpositioning was made unilaterally, and in 28 patients bilaterally; a total of 100 operations were performed. A total of 250 implants were placed, an average of 2.5 implants per patient.

Implant survival, marginal bone loss, and neurosensory function were recorded 1 week and 6 months postoperatively, and 72 of these were followed until 18 months postoperatively. During the 12 month period following abutment connection, mean marginal bone loss was 0.3 mm (range 0.1 to 5.1 mm). One week after implant placement, 32% had diminished neurosensory function, and 47% had no function. Six months

postoperatively, 77% had normal neurosensory function, 21% diminished function, and 2% had no function. At 18 months postoperatively, 94% had normal sensation, 4% had diminished sensation, and 1% had no sensation.

The low incidence of nerve morbidity in this study may encourage the use of nerve transpositioning as a routine procedure for implant placement in the posterior mandible especially as increased initial implant stability is obtained by the method. However, patients should be selected with considerable care and should fully understand and accept the risks of the procedure.

This study concludes that nerve transpositioning is indicated when: (1) the alveolar bone height above the mandibular canal is less than 10 to 11 mm and (2) in other cases where the quality of cancellous bone does not offer adequate stability for implant placement. Nerve transpositioning is contraindicated when: (1) the bone height above the canal is less than 3 mm, and relatively contraindicated when; (2) the patient has a combination of thick buccal cortical bone and a thin neurovascular bundle, (3) the patient is susceptible to hemorrhage or infection, and (4) when access to the operation field is limited.

Int J Oral Maxillofac Implants 1994;9:522-531

The Pterygoid Plate Implant: A Solution for Restoring the Posterior Maxilla

S.L. Graves

Placement of a cantilevered restoration or augmentation with a sinus lift has become conventional treatment for the maxilla. Placement

of a pterygoid plate implant is an alternative that may be used with predictable success. This implant passes through a pillar of bone composed of the maxilla, pyramidal process of the palatine bone, and the pterygoid process of the sphenoid. The thickest area of supporting bone is located in the middle part of the pterygoid process between the plates. This is 3 to 4 mm medial to the alveolar ridge; an implant must therefore be angled slightly medially to bisect this dense juncture of bone in the pterygoid region. The hamular process on the

(Continued on Page 6.)

◆
Educational Opportunities
Sponsored By The Institute
For Facial Esthetics –

Presented At
Prosthodontics Intermedica
A Brånemark System Implant
Treatment Center

FEB. 21, 22, 23, 1995

APRIL 4, 5, 6, 1995

A Unique Training Opportunity:

- 24 hours of live surgeries, lectures and hands-on training
- Patient interaction
- The Conversion Prosthesis:
Converting a full denture or RPD to a provisional osseointegrated prosthesis at stage II surgery.
- Oral hygiene for implants
- Laboratory procedures
- Tips on monetary arrangements
- Implant rehabilitation from treatment planning to completed osseointegrated prostheses
- Class size limited to 6.

Presentors: Thomas J. Balshi,
D.D.S., F.A.C.P., F.A.O.
Glenn J. Wolfinger,
D.M.D.
Robert Winkelman,
C.D.T., M.D.T.

Tuition: \$1,600.00

For Information: Tel: 215-643-5881

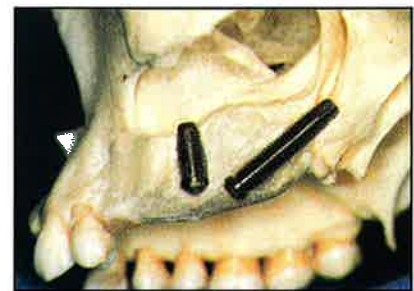

Figure 1: The amount of bone surrounding a 10mm implant is compared to that surrounding a 20 mm pterygoid plate implant. The screw access area for both is the occlusal aspect of the first molar.

(photo: courtesy Quantessence Pub. Co.)

Microbial Penetration Along the Implant Components of the Brånemark System

An In Vitro Study
Quirynen et al

Plaque has been identified as an important etiological factor of periimplantitis. Implants with periimplantitis were found to harbor a complex microflora of conventional oral pathogens. This bacterial leakage might effect the evolution and treatment of this disease and interfere with the long-term success of Brånemark implants. This in vitro study examined the possibility of a penetration of oral microorganisms between the components of the Brånemark implant system.

Thirty-two implant/abutment assemblies were installed in a liquid blood medium previously inoculated with oral microorganisms. To examine the leakage at the implant-abutment interface, 16 assemblies were partially immersed. The remaining 16 were completely immersed to observe the leakage at both the implant-abutment and abutment-prosthesis interface. After 7 days microorganisms were found in the completely immersed assemblies and at lower numbers in the partially immersed implants.

The data clearly prove the existence of bacterial leakage along the components of the Brånemark implant system, both at the junction between the abutment and the implant, as well as along the abutment screw.

Although the longevity of the Brånemark implant is well documented, this bacterial leakage might play a role in periimplantitis and/or might influence the outcome of guided tissue regeneration after periimplantitis.

Editors Note: Although plaque accumulations have been clinically identified inside abutments and between abutments and prosthetic components, there appears to be no clinical significance in relation to mucosal health or marginal bone levels for patients treated up to ten years in our center. Guided tissue regeneration appears to be most successful when abutments are completely removed during the healing period and the implant clinically re-submerged.

Clin Oral Impl Res 1994;5:239-244

Ten-year Longitudinal Study of Masticatory Function in Edentulous Patients Treated With Fixed Complete Dentures on Osseointegrated Implants

G.E. Carlsson & L.W. Lindquist

Twenty-three edentulous patients who received a mandibular fixed complete denture retained by osseointegrated implants (CDOI) were followed over a 10-year period. A maxillary fixed complete denture was later placed for nine of the participants. All had worn complete dentures in both arches for at least 1 year and had experienced great difficulty in adapting to their restorations. Results of the study indicated:

1. Placement of a mandibular fixed complete denture on osseointegrated implants (CDOI) in dissatisfied

- complete denture wearers lead to a rapid and dramatic improvement of masticatory function that was acceptable for many patients.
2. Some patients requested and required a maxillary CDOI to experience a satisfactory rehabilitation.
3. The gain for the group receiving a maxillary CDOI was mainly psychological as the functional tests showed only minor improvement after the maxillary implant treatment.

Int J. Prosthodont 1994;7:448-453

Clinical and Radiographical Features of Submerged and Nonsubmerged Titanium Implants

Ericsson et al

The Brånemark System advocates that implants be submerged during the initial phase of healing, with a second surgical procedure connecting the abutments to the implants before a supraconstruction is attached and loading allowed. However, it has been demonstrated that proper bone anchorage (osseointegration) to titanium implants can be achieved with a 1-step procedure. This study was performed to evaluate whether initial submergence of titanium implants is an obligate treatment measure for the establishment of proper bone anchorage when Brånemark implants are used.

The patient group comprised 11 healthy individuals edentulous in the mandible for at least a 3-year pre-treatment period. Of a total of 63 implants placed, 33 were installed using the 1-step procedure and 30 using the conventional 2-step procedure. A split-mouth technique of treatment was adopted. In the right side of the mandible the original 2-step surgical procedure for implant placement and abutment connection was used. In the

left jaw a 1-step procedure was employed; implants were placed and *healing abutments* were connected in one surgical session.

All implants were clinically stable at the 12-month and 19 month examinations. Radiographic analysis demonstrated that the amount of bone loss that occurred was similar in both treatment groups.


The results demonstrated that Brånemark titanium implants can obtain proper osseointegration in mandibular bone when implants are exposed in the oral cavity during the initial 3-month healing period, and when implants are installed in a 1-step procedure successfully supporting fixed bridges over a period of 18 months.

Clin Oral Impl Res 1994;5:185-189

PROSTHODONTIC

Insights

is published by Prosthodontics Intermedica and distributed without charge to qualified individuals. Please request a subscription on your organization's letterhead.



Fixed, Removable, Maxillofacial and Implant Prosthodontics

Prosthodontics Intermedica
467 Pennsylvania Avenue, Suite 201
Fort Washington, PA 19034 U.S.A.
Tel: 215-646-6334
Fax: 215-643-1149

Characteristics Associated with the Loss and Peri-Implant Tissue Health of Endosseous Dental Implants

R.J. Weyant

The object of this study was to identify from registry data variables that were correlated with implant failure and with problems in peri-implant soft tissue health. The principle data source for this study was the United States Department of Veterans Affairs (VA) Dental Implant Registry. Data was examined to determine if variables

contained in the registry or other VA data bases could be related to implant removal or problems with peri-implant soft tissue healing after implant surgery. All registry cases that met the following conditions were used in the analysis (1) the patient received cylinder (root-form) implants, and (2) the patient had at least one postsurgical evaluation of the implant(s).

Independent variables were created from registry data that characterized the implant, provider, patient, and treatment facility. Implant variables included: implant manufacturer, date of implant placement, intraoral site of implant, and type of implant surface coating. Patient variables included: demographics, medical/pharmacological history, and oral health status. Provider and facility variables included: implant surgeon's "experience" with implants, size of treatment facility,

and the treatment facility's patient flow characteristics.

Data from 598 patients fit the selection criteria and were used in this study. These patients received a total of 2,098 implants. The 60-69-year old age strata composed the largest single group to receive implant treatment. Reports of systemic disease and medication usage were widespread.

Most implant restorations involved multiple implants. Only 61 cases (10.2%) that involved a single implant were reported.

Although 15 different types of implants were contained in the registry data, there was sufficient data on only the top six brands of implants to mount a meaningful statistical analysis. All other implants were placed into an "all others" category.

Implant failures and subsequent removals were rare. Overall, 81 implants in 45 subjects failed and were removed. This results in a crude rate for implant survival of 96.1%.

Implant descriptor variables revealed that coated implants, surgical complications with bone, and implants with peri-implant soft tissue health complications were at higher risk of loss. The association of loss with peri-implant soft tissue health status suggests that the decline of an implant's health is part of a clinical continuum in which each failing implant processes from minimal pathosis to implant removal. There was nearly a three times greater crude failure rate when a provider reported a surgical complication associated with alveolar bone for that implant.

Three variables associated with systemic medical conditions were associated with implant failure: surgical risk, medical history and medication history. One systemic variable, a history of smoking, was shown to be associated with peri-implant soft tissue health.

One variable related to the nature of the treatment facility. The model indicates that as the number of outpatients treated within a dental service increases, the likelihood of implant success also increases.

The only characteristic associated with both implant failure and poor peri-implant soft tissue health status was the presence of a surface coating.

(Int) J Oral Maxillofac Implants 1994;9:95-102

Editor's note: Although the author declines endorsement of implant manufacturer, valuable information regarding the complication and failure rate related to various manufacturing processes could be beneficial to the profession and our patients.

The Pterygoid Plate Implant: . . .

(Continued from Page 3.)

medial pterygoid plate is easily palpable in the oropharynx. The implant is placed just lateral to this key landmark. If an implant is passed through the dense bone at the juncture of the palatine and sphenoid process at an angle of 45 degrees, it incorporates 8 to 9 mm of dense cortical bone (Fig 1).

Because of the 45 to 50 degree angulation of the implant, the screw access area will be in the central fossa at the first molar. The implant angle is determined by the floor of the sinus and the vertical height of bone in the tuberosity. The normal tendency when this procedure is attempted for the first time is to place the implant too far anteriorly with too little horizontal angulation.

The prosthesis can be worn immediately after surgery. The denture is relieved in the tuberosity to prevent

premature loading. At reentry in 6 months, the implant is reverse torque tested (10 Ncm) to ensure osseointegration. A standard abutment is usually placed. Where the angulation has exceeded 60 degrees, an angled abutment may be used.

Sixty-four implants were placed in 49 patients. Forty-three are in function. There were 7 failures (10.9%), all at the second stage, when their mobility was tested. No implants failed under function, indicating that implants respond well to nonaxial loading. The occlusal plane, in relation to the implant axis, seems to exert no significant influence on the periimplant health or stability. The pterygoid plate implant has been used successfully with fixed prostheses, spark erosion prostheses, and framework supported overdentures. Many of the implants have been in function over 4 years.

Int J Periodont Rest Dent 1994;14:513-523

Oral Hygiene Video For The Implant Patient

Educate your patients with a detailed film of home care techniques for implant patients.

Reinforce the hygiene instructions you have already shown your patients.

Optimize the time that your hygienist spends with home care instructions.

Legal documentation is verified by patient viewing homecare video.

1 Video \$35.00 5 Videos \$150.00

Return _____

Address _____

Please mail check and form to:

Institute for Facial Esthetics

467 Pennsylvania Avenue, Fort Washinton, PA 19034

Tel: 215-643-5881 • Fax: 215-643-1149