

Immediate Loading of Brånemark Implants



Glenn J. Wolfinger, D.M.D., F.A.C.P. Thomas J. Balshi, D.D.S., F.A.C.P.

The concept of immediate function on endosseous implants has historic precedents in dentistry. The biologic and mechanical results of treatment using endosseous implants such as blades and tripodial pins, led to their demise and a moratorium on such treatment over three decades ago. In the early 1980's the process of osseointegration was introduced to North America following a stringent protocol developed by the Swedish physician and researcher, Per Ingvar Brånemark. This protocol required the undisturbed and unloaded healing of bone around the implants for a specified period of time prior to prosthetic application. Recently, however, a small number of clinical researchers have modified Brånemark's original protocol to begin loading Brånemark implants early or even immediately (the same day as stage I surgery) in specific areas. Success rates have varied depending upon the quality and quantity of bone; however, the concept has proven to be effective for certain individuals.

This issue of *Prosthodontic Insights* reviews some of the more pertinent literature based on the concept of early and immediate loading. The following clinical treatment regime is but one example of these principles and opens the door to an opportunity for patients who cannot tolerate the concept of, or physically deal with the use of, removable dentures during the osseointegration period. The clinical example of immediate loading is highlighted with presentation of a 62 year old black male patient with the

chief complaint of extremely poor esthetics (Fig 1a) and problematic oral function. As a practicing attorney he was concerned about the social implications of tooth loss and the potential problems that could develop when using a removable denture. The patient's occupation was dependent upon an ability to speak in public; therefore, he had a definite aversion to using any form

Continued on page 2.)

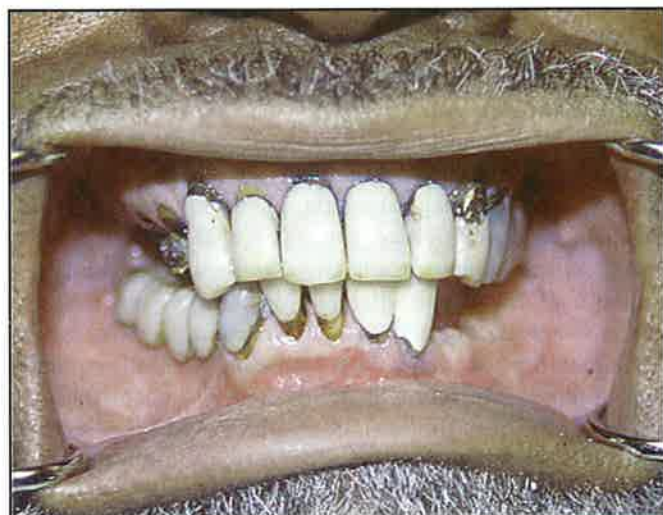

Figure 1a: Pre-op clinical view.

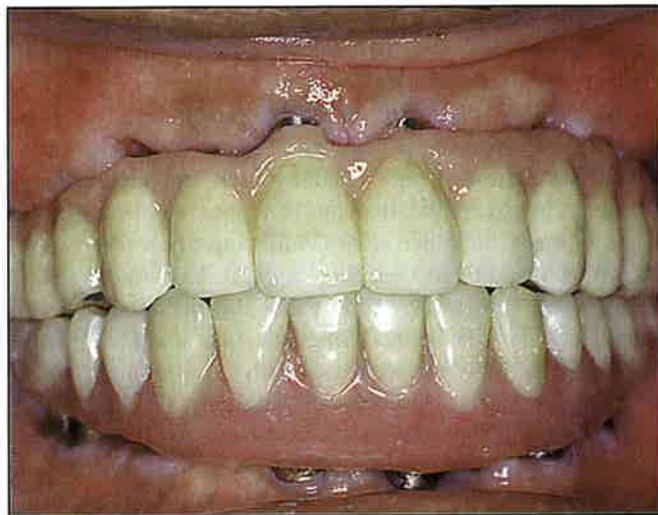

Figure 1b: Post-op clinical view.

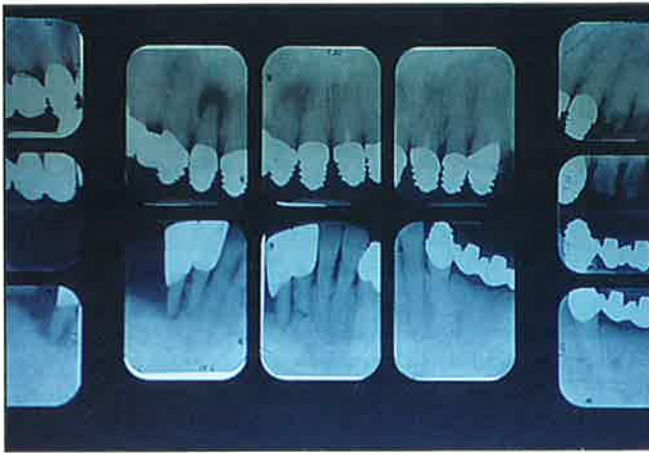


Figure 2: Preoperative intraoral full mouth series of radiographs illustrating the failing dentition.

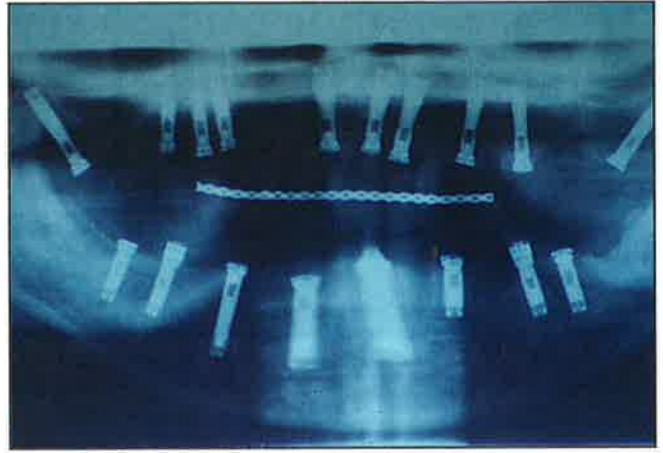


Figure 3: Post-surgical stage 1 radiograph which illustrates 3 abutments placed on the mandibular implants for immediate loading.

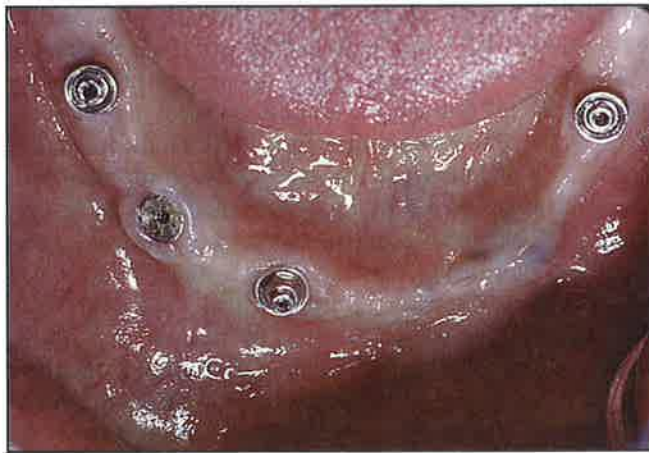

Figure 4: Occlusal view of the three immediately loaded implants following mucosal healing.

of removable prosthesis.

His clinical condition included a long standing history of moderate to advanced periodontitis, wide spread cervical caries and multiple periapical endodontic lesions (Fig 2).

At the patient's request, a treatment plan for implant supported prostheses was developed which included fixed implant restorations to be used in the healing phase of osseointegration instead of removable prostheses. This plan consisted of saving some key natural tooth abutments for an interim restoration in the maxillary arch and immediately loading three Brånemark implants to support an interim prosthesis in the mandibular arch. Following extraction of the remaining mandibular dentition, eight Brånemark implants were placed strategically throughout the mandibular arch. Selectively, three Brånemark implants, one near the midline and two in the posterior, were used with the appropriate abutments to support a conversion prosthesis (Fig 3 & 4).

The mandibular conversion prosthesis was developed from a complete removable immediate denture which had been fabricated prior to this visit and then modified to a fixed

prosthesis supported by the three immediately loaded implants (fig. 5a,b,c).

In the mandible, the five Brånemark implants that were not immediately loaded were allowed to heal undisturbed following the traditional Brånemark protocol. Following the standard three month healing time for the mandibular arch, the remaining five implants were uncovered and a final prosthesis was constructed. Two months later all of the maxillary implants were uncovered and a conversion prosthesis was constructed from the provisional prostheses at the same visit. After the few remaining natural maxillary teeth were removed, final impressions were taken for a porcelain fused to gold fixed tissue integrated prosthesis which was delivered the following week (Figs 1b, 6a,b,c).

The protocol of immediate loading in the mandibular arch raises the risk of implants not integrating due to micromovements created by occlusal function. However, in patients with good quality and quantity of bone (type 2 or 3 bone with adequate length), the potential for good primary implant stability is excellent. In addition, insurance implants can be added to the treatment plan. These extra implants which are immediately loaded function as anchors for the provisional restoration and can be considered disposable. Interestingly, the majority of implants that were loaded immediately in a pilot study of ten patients conducted at Prosthodontics Intermedica indicated a very high success rate of osseointegration (80%). Nonetheless, our protocol still warrants the use of additional implants to assure the potential for a fixed prosthesis as the final restoration. Therefore, the loss of any of the immediately loaded implants would not preclude the use of a fixed implant prosthesis as the final restoration when using this format.

Future product development will even further enhance the predictability of immediately loading dental implants. Development of computerized drilling machines (i.e. Osseocare, Nobel Biocare), computerized analysis of radiographs (SIM-Plant), and resonance frequency testing will allow for better determination of bone quality. Implants with

(Continued on page 3.)

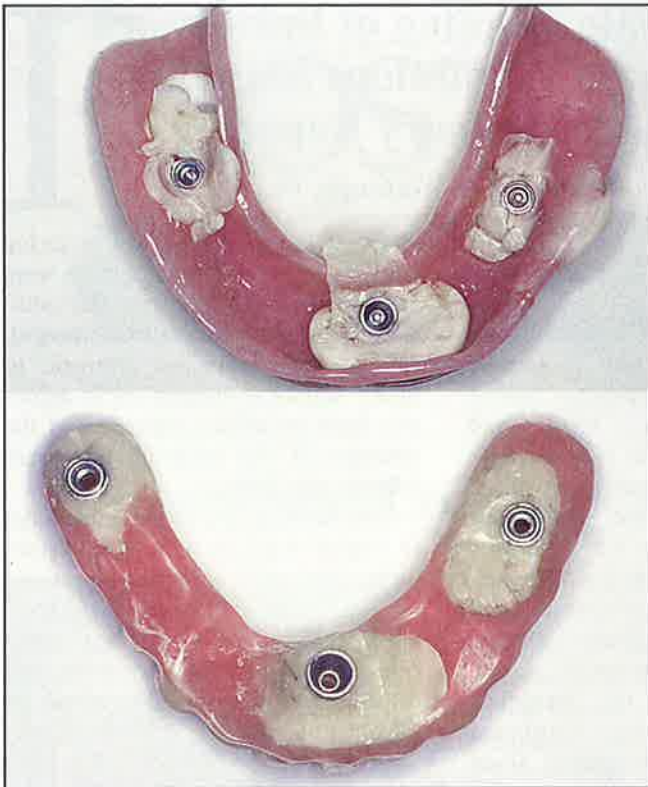


Figure 5a,b: The conversion prosthesis created from the provisional immediate removable denture showing the three prosthetic retention cylinders.

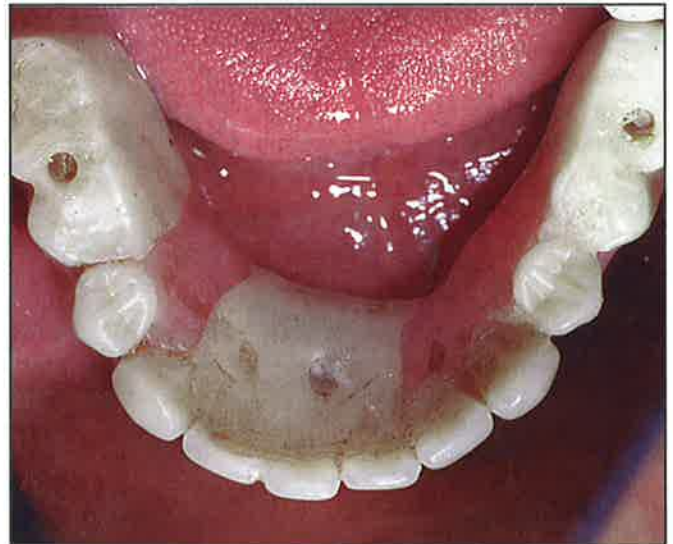

Figure 5c: Occlusal view of the conversion prosthesis supported by 3 immediately loaded implants.

improved surface areas (i.e., Brånemark Mark IV fixture, Nobel Biocare) will allow for better initial stability in poorer quality bone, and growth factor technology will help to speed up the biologic process of osseointegration.

Acknowledgment:
 Robert Winkelman, CDT, MDT
 Fort Washington Dental Lab, Inc.
 Fort Washington, PA
 215-628-4994

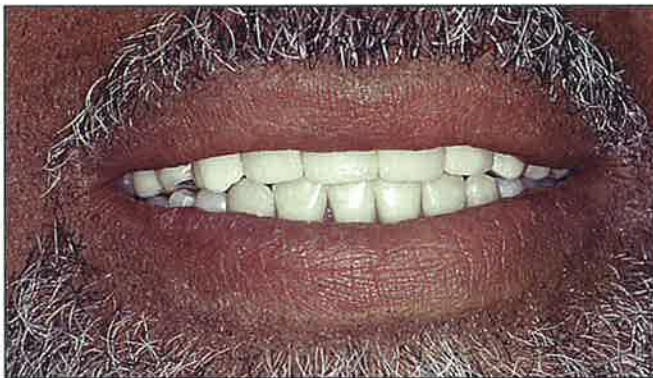

Figure 6a: Final tissue integrated prosthesis, smiling view.

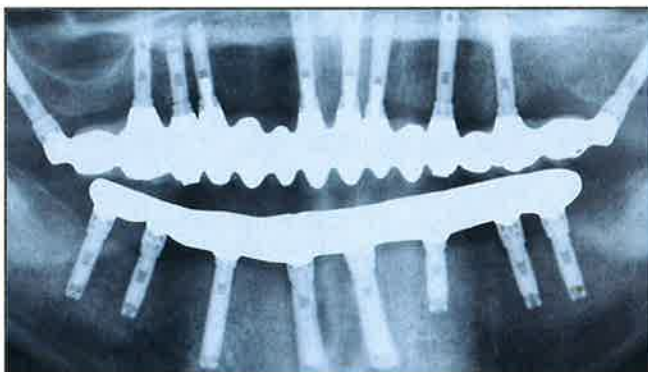


Figure 6b: Postop panoramic radiograph showing the 10 implant supported porcelain fused to gold prosthesis in the maxillary arch, and the 8 implant supported prosthesis restoring the mandibular arch including 3 implants which were immediately loaded.




Figure 6c: Patient delighted with the outcome of immediately loaded treatment regime, avoiding the use of a removable prosthesis.

Immediate Loading of Titanium Plasma-Sprayed Screw-Shaped Implants in Man: A Clinical and Histological Report of Two Cases

Piattelli et al

This study reports on the histological findings of two immediate loaded titanium plasma-sprayed (TPS) implants retrieved from humans after eight and nine months of loading. The microscopical analysis showed that mature compact cortical bone was present around both implants with the bone implant contact percentage about 60-70%. No fibrous tissues or gaps were present at the interface. No resorption was present in the peri-implant bone. On both implants a few osteoblasts were found positive at the interface for alkaline phosphates

while no cells positive for acid phosphatase were present. Immediate loading can perhaps be used in very selected cases of good bone quality with implants that have certain macro and micro structure characteristics. Good results have been reported also for machine surfaced implants. More data about different designs or coatings are needed before any firm conclusions about immediate loading can be reached.

J Periodontol 1997;68:591-597

Immediate Loading Versus Delayed Loading of Non-Submerged Implants in 20 Consecutive Mandibles

Nicolopoulos C

The purpose of this study is to compare the success rate of immediate loading versus delayed loading of non-submerged single staged threaded titanium implants placed in edentulous mandibles. A total of 110 non-submerged threaded titanium root form fixtures were assessed in the study. The requirement for case selection was that each implant had to display good primary stability of 20-32 Ncm at the time of placement.

Fifty-five implants were placed in 10 consecutive edentulous mandibles and were loaded immediately with fixed prostheses. A further 55 implants were placed in another 10 consecutive edentulous mandibles, but these were loaded only four months later.

The 20 consecutive cases were followed up from 1 1/2 to 5 years and the

success rate of the immediate loading group was compared to the delayed loading group. Ninety-five percent (52 out of 55) of the immediate loaded implants were found to be integrated, as compared to 100% (55 of 55) of the delayed loading group of implants.

Statistical analysis revealed an insignificant difference of success between immediate loading versus delayed loading groups. The conclusion of this study is that, provided good primary stability is achieved at the time of implant placement, there may be no statistically significant difference between immediate loading and delayed loading of non-submerged implants in edentulous mandibles.

Poster presentation, 14th Annual Meeting, Academy of Osseointegration, March 4-6, 1999, Palm Springs, CA

Ten year results for Brånemark implants loaded with fixed prostheses at implant placement

Schnitman PA et al

This investigation was initiated to develop a method to provide patients with a fixed provisional prosthesis placed at the time of implant placement. Sixty-three standard 3.75 mm Nobel Biocare implants of varying lengths were placed in the mandibular sites in ten patients and followed for up to ten years. Twenty-eight implants were immediately loaded at implant placement providing support for fixed provisional prostheses, while thirty-five adjacent prostheses were allowed to heal submerged, and stress free. Following a three month healing period, the submerged implants were exposed and a definitive reconstruction was accomplished. All ten prostheses supported by 28 implants placed in immediate function at the time of implant placement were successful during the three month healing period. Of these 28 implants placed into immediate function, four ultimately failed. Of the 35 submerged implants, all are osseointegrated and in function to date. Life table analysis demonstrated an overall 10-year survival rate of 93.4% for all implants. The 10-year life table analysis of survival is 84.7% for immediately loaded implants and 100% for submerged implants. Statistical analysis of the submerged versus immediately loaded implants demonstrate failure rates for immediately loaded implants to be significantly higher. These data demonstrate that although mandibular implants can be successfully placed into immediate function in the short term to support fixed provisional prostheses, long term prognosis is guarded for those implants placed into immediate function distal to the incisor region

Int J Oral Maxillofac Implants 1997;12;4:495-503

Immediate Functional Loading of Brånemark Dental Implants: An 18 Month Clinical Follow-up Study

Randow et al

A clinical and radiographic study was performed to compare the outcome of oral rehabilitation in the edentulous mandible by fixed suprastructures connected to implants installed according to either a one-stage surgical procedure and immediate loading (experimental group EG), or the original 2-stage concept (reference group RG).

The EG comprised 16 subjects with edentulous mandibles. Beyond the non-smoking criteria, the following specific inclusion criteria were adopted. All patients had to consider themselves to be in good general health. The amount of bone had to enable the installation of 5-6 fixtures, at least 10 mm. long, to be bicortically anchored (Mark II fixtures, Nobel Biocare AB, Gothenburg, Sweden) between the mental foramen. The patients had to be available for the follow-up and maintenance program.

A total of 88 implants were placed in the EG (16 patients) compared to 30 in the RG (11 patients). The EG fixed appliances were connected to the implants within 20 days following implant installation; while the fixed appliances in the RG were connected

about four months following fixture installation.

At the time of delivery of the suprastructures, all 27 patients were radiographically examined; an examination that was repeated at the 18 month follow-up. The analysis of the radiographs from the EG disclosed that during the 18 month observation period the mean loss of bone support amounted to 0.4 mm.; the corresponding value observed in the RG was 0.8 mm. During the 18 month observation period, no fixture was lost in either of the two groups examined. The implants under study, as well as those in the referenced material, were found to be clinically stable at all observation intervals.

The present clinical study demonstrated that it is possible, at least based on an 18 month observation period, to successfully load dental implants immediately following installation via a permanent fixed bridge and cross arch suprastructure. However, such a treatment approach has so far been strictly limited to the intra foramen area of the edentulous mandible.

Clin Oral Impl Res 1999;10:8-15

Immediate Loading of Threaded Implants at Stage 1 Surgery in Edentulous Arches: Ten Consecutive Case Reports With 1-to-5-Year Data

Tarnow et al

Immediate loading of threaded implants with a fixed provisional restoration at stage one was evaluated in 10 consecutive patients. The patients selected had to be completely edentulous and have adequate bone for a minimum of 10 mm. long implants. A minimum of 10 implants were placed in each patient's arch; a minimum of 5 implants were submerged initially for medical/legal reasons and allowed to heal without loading. The remaining implants were loaded at the day of stage 1 surgery. Once the provisional restoration was relined it was cemented or screw retained. A total of 107 implants were placed in these 10 patients: six in the mandible and four in

the maxilla. Six patients were treated with Nobel Biocare implants, one with ITI Bonefit implants, two with Astra Tech TiOblast and one with 3I implants. Sixty-seven of the 69 implants that were loaded integrated, and 37 of the 38 submerged implants integrated. All 10 patients have been restored with the definitive prosthesis and all have had a fixed provisional prosthesis from stage 1 surgery. The results of this study indicate that immediate loading of multiple implants rigidly splinted around a completely edentulous arch can be a viable treatment modality.

Int J Oral Maxillofac Implants 1997;12:319-324

Mobility of Standard Versus Newly Designed Experimental Brånemark Fixtures

Brunski JB and Liu C

Clinical trials on immediate loading of oral implants have typically used implants originally designed for delayed loading. However, it does not necessarily follow that implants designed for delayed loading will work equally well with immediate loading. With immediate loading, a risk is excessive micromotion and subsequent fibrous tissue formation at the healing bone implant interface, especially for implants in soft density bone.

To minimize micromotion, one strategy is to design the implant to have increased initial mechanical stability in bone while at the same time preserving design features that contributed to success in delayed loading. To this end our objective was to measure the initial axial and lateral mobility of standard versus newly designed experimental Brånemark titanium fixtures. Bone specimens consisted of 10 rectangular samples of trabecular bone cut from bovine femurs. Each sample received two implants: one standard 4X10 mm Brånemark self tapping fixture and one 4 X 10 mm experimental fixture. Newly designed experimental fixtures had a slight crestal to apical taper and a modified thread design. The maximum torque during the installation of the standard and experimental fixtures was measured with a torque transducer. Axial and lateral mobilities were measured using a miniature mechanical testing machine.

There was a decrease in mean lateral mobility and mean axial mobility in the experimental fixtures when compared to the standard Brånemark fixtures. Maximum torques during installation were also greater for the experimental fixtures when compared to the standard fixtures.

The data demonstrates that the new experimental Brånemark fixtures were

Continued on page 6.)

Mobility of Standard Versus Newly Designed . . .

(Continued from Page 5.)

tighter in bone than the standard Brånemark fixtures and required a larger peak torque during the installation procedure. The results support the design strategy of the new experimental Brånemark fixture, i.e. it is more stable in low density bone and may contribute to a decreased risk of micro-motion when used in soft bone or in immediate loading protocol.

Oral Research Presentation, 14th Annual Meeting, Academy of Osseointegration, Palm Springs CA, 1999



What do you tell your patients when they ask what they should eat after surgery and throughout treatment?

From Soup to Nuts

Originally conceived as a cookbook for dental patients embarking on implant reconstruction, FROM SOUP TO NUTS introduces gourmet anticipations for the most compromised eater, as well as a wide range of delicious novelties that eventually challenge the most securely implanted permanent teeth.

An ideal gift to help motivate a patient considering dental implants, for a patient recovering from a dental or surgical procedure, for a confirmed denture wearer, or for any person requiring a careful diet, FROM SOUP TO NUTS is the prescription for the flavors that accompany a bright healthy smile. It's just what the doctor ordered!

To order your cookbook: 215-643-5118
Costs: \$14.95 Doctors Costs: \$12.95

PROSTHODONTIC Insights

is published by Prosthodontics Intermedica and distributed without charge to qualified individuals. Please request a subscription on your organization's letterhead.



Fixed, Removable, Maxillofacial and Implant Prosthodontics

Prosthodontics Intermedica
467 Pennsylvania Avenue, Suite 201
Fort Washington, PA 19034 U.S.A.
Tel: 215-646-6334
Fax: 215-643-1149

Immediate Loading of Brånemark Implants in Edentulous Mandibles: A Preliminary Report

Balshi, TJ & Wolfinger, GJ

A study involving the immediate loading of Brånemark implants in the edentulous mandibles of ten patients is reported. The patients ranged in age from 45 to 70 years, with an average age of 55 years, and were treated between December 1993 and December 1994. Eight patients were diagnosed with moderate to advanced periodontal disease, one with failing overdenture abutments and one with a severe class II malocclusion. The natural teeth were extracted and Brånemark implants (Nobel Biocare USA Inc.) were immediately placed. The design involved the immediate loading of four widely distributed implant supported prosthesis at first stage surgery which eliminated the need for a removable prosthesis in

patients who were adverse to wearing one. A minimum of ten implants were placed in each mandible. The additional implants remained submerged, following the standard protocol, to insure sufficient support for a definitive fixed prosthesis regardless of the outcome of the implants that were immediately loaded.

The survival rate of the immediately loaded implants was 80% versus 96% for the standard protocol implants. More importantly, all ten patients functioned successfully with a fixed implant prosthesis from the day of first stage surgery without adversely effecting the outcome of the final treatment.

Implant Dent 1997;6:83-88

Brånemark System Surgical and Prosthetic Training In A Clinical Setting

Dates: April 12-14, 1999
October 4-6, 1999
January 10-12, 2000

Presenters: Thomas J. Balshi, DDS, FACP
Glenn J. Wolfinger, DMD, FACP
Robert Winkelman, CDT, MDT
Ron Dove, Nobel Biocare
System Specialist

Location: Institute For Facial Esthetics – An Official Brånemark Training Ctr
467 Pennsylvania Avenue #201
Fort Washington, PA 19034
Tel: 215-643-5881
Fax: 215-643-1149

For: General dentists, Prosthodontists, Periodontists, Oral Surgeons, Hygienists, Laboratory Technicians, assistants, Office Managers

For More Info: Tel: 215-643-1149
E-mail: PITEAM@aol.com
Web Site: <http://dentalimplants-usa.com>

- **Venue:** This course is held in an implant center. Participants will learn how to implement implant treatment into their general practice by observing the team approach in action. Participants will view all implant related treatment scheduled in the center during the 3-day program, including stage 1 and 2 surgeries, bone grafting procedures, implant prosthodontics, treatment planning, avoiding complications, and more.
- **Modalities used:** Live surgeries; prosthetic and surgical hands-on training; lectures; slides; videos
- **Hours:** 3-day program from 9:00 a.m. – 5:00 p.m.
- **Objectives:** To demonstrate the effect of osseointegrated implants on facial esthetics and general patient well being; patient management before, during and after Stage I and II surgery, Post-prosthesis maintenance.
- **IFFE is an ADA CERP recognized provider**