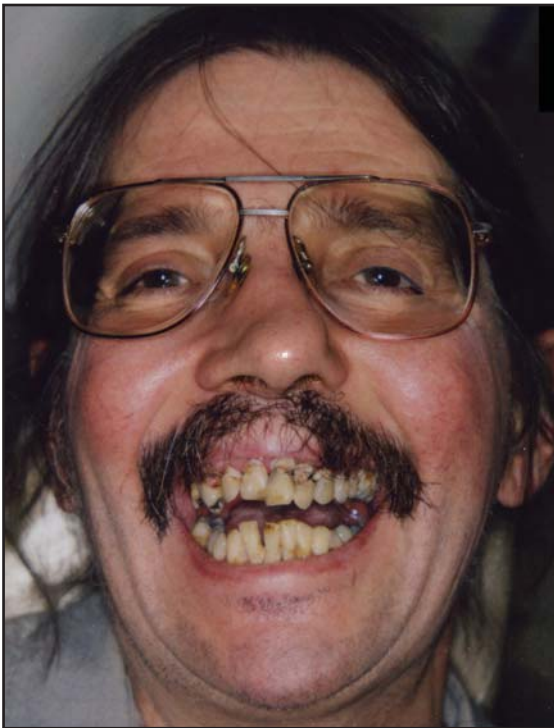

A COST EFFECTIVE APPROACH FOR FACIAL REHABILITATION WITH DENTAL IMPLANTS



Robert, a 49-year-old journalist came to Pi for an opinion on his smile. His profession required frequent face-to-face interviews.

His chief complaints were the embarrassment he experienced when smiling, painful chewing, very poor esthetics and highly mobile teeth. He wrote in his medical history, "It would be nice to smile again". Robert was in a severe auto accident in 1980, which left him with a chronic painful condition in his

neck, his back and his jaws.

Robert's initial clinical examination noted multiple fractured teeth, extensive dental caries, apical abscesses, and extruded teeth, which created a severe malocclusion. There was a heavy plaque and calculus accumulation, which combined with smoking, contributed to advanced periodontal disease. At his initial visit, he smoked one pack of cigarettes a day, but desired to stop. Robert was advised of the

effects of smoking, not only on his general health, but also on his dental condition. He was strongly advised to quit smoking immediately. Robert did admit he was "a very bad dental patient" due to his high level of anxiety.

Historically, extensive periodontal therapy followed by prosthodontic treatment may have been indicated to maintain and restore Robert's natural dentition. However, with all the clinical findings and the current condition of the patient's dentition,

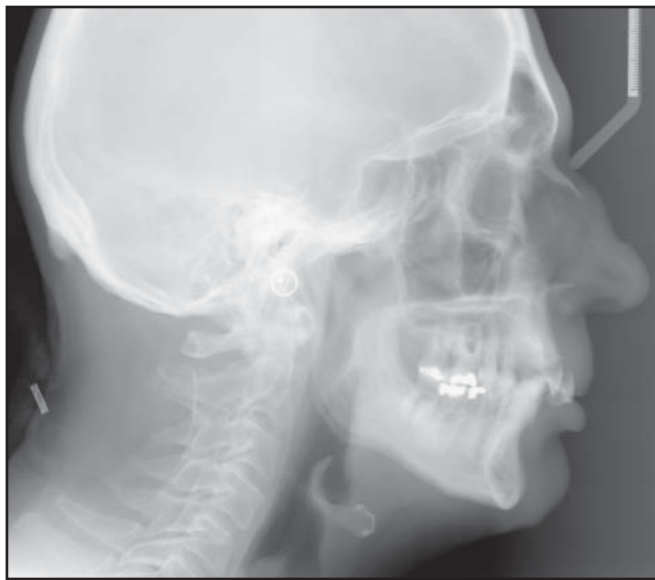
traditional dental treatment had a poor prognosis. With his advanced periodontal disease and his poor compliance, orthodontics to improve the dental malocclusion was not a viable option.

Robert was presented with a treatment plan addressing all his concerns in an expedient manner. Cost was a consideration for the full mouth reconstruction. Some doctors would recommend less expensive implant prosthetic treatment using an implant overdenture. At Pi Dental Center we have found that patients are rarely satisfied with the removable implant overdenture as they are with the fixed implant prostheses. We found that there are many additional visits, as well as added costs associated with maintenance of the overdentures. Recent studies have collaborated our findings (see abstract on page 3).

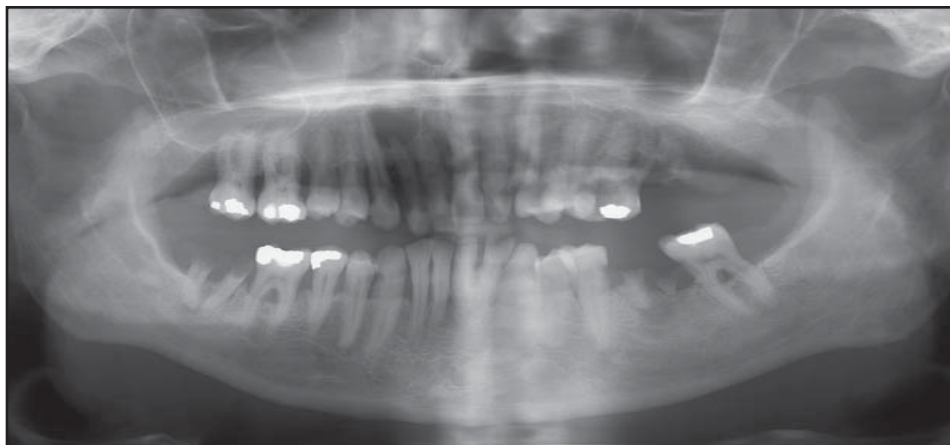The philosophy at Pi Dental Center is to provide patients with the most effective and efficient approach to solving their dental problems. The Teeth In A Day™ procedure is an excellent alternative for patients with a failing dentition who need to make the transition to an implant supported prosthesis. Historically, it would take several months or even years to see the benefits of implant treatment. Fifteen years of research pioneered at Pi Dental Center has enabled patients to enjoy the benefits of immediately loading the implant-supported teeth on the same day that their decayed teeth are removed and the implants installed. This accelerates the entire clinical process.

The early research for Teeth In A Day™ was accomplished in patients where larger numbers of implants were placed to provide a very predictable solution for prosthesis stability. Recently, studies have been published that show comparable predictability using fewer implants. The latter may prove to be a more cost effective treatment approach for patients in need of implant-reconstruction.

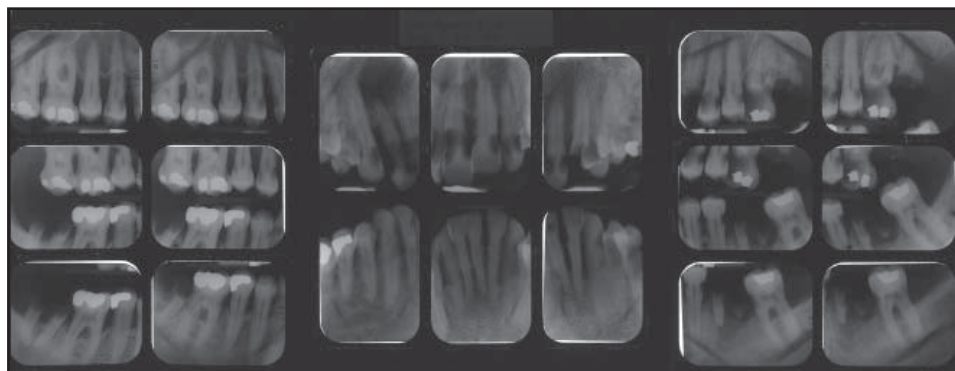
For Robert's treatment all the periodontally compromised teeth were extracted, six implants were placed in the maxillary arch, four implants were placed in the mandibular arch and prostheses for both arches were put into immediate function following the Teeth In A Day™ protocol. While the patient was encouraged to adhere to a soft diet for the first three months, the temporary teeth proved to be much stronger than Robert's natural teeth. The esthetic improvements were



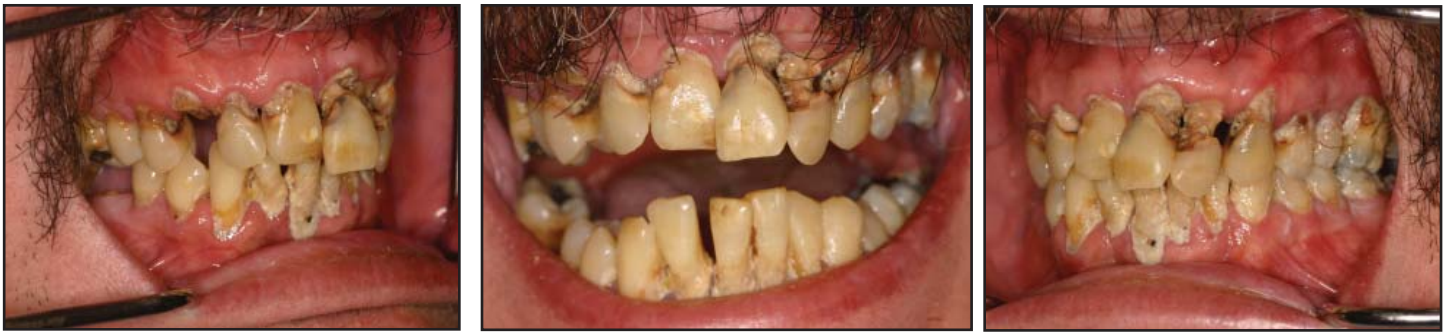Pre-treatment lateral cephalometric radiograph shows severe bite collapse



Pre-treatment panoramic radiograph reveals extensive bone loss, advanced caries and periodontal disease



Pre-treatment full mouth series of radiographs show advanced cervical caries and advanced bone loss.



Pre-treatment views prior to Teeth In A Day™

immediate. Three months after the implant placement the bone healing had stabilized and the final implant reconstructions were delivered.

The patient went through a complete makeover to improve his overall esthetics. Dr. George Zavitsanos, a board certified plastic surgeon, provided improved facial esthetics by surgically correcting the deviation in Robert's nose in conjunction with multiple soft tissue enhancements. Following facial surgery healing and the Teeth In A Day™ treatment, Robert agreed to a style makeover and experienced his first hair cut since 1969. A new prescription for corrective lenses offered yet another cosmetic improvement with his stylish new glasses. Robert's satisfaction with the Teeth In A Day™ procedure is extremely high. He has noticed a dramatic improvement in his psychological well-being and has found it easy to smile and be more outgoing. As a news journalist for a Washington, DC newspaper, he feels more comfortable at press conferences in the highly political public eye.

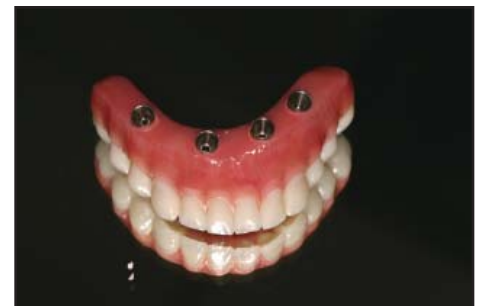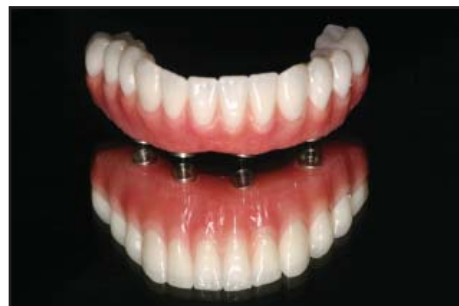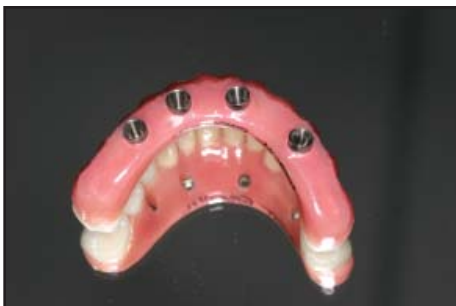From a dental standpoint, the periodontal disease has been eliminated and the patient now has a completely healthy, functional, stable and esthetically pleasing reconstruction.

Prosthetic complications with dental implants: from an up-to-8-year experience in private practice.

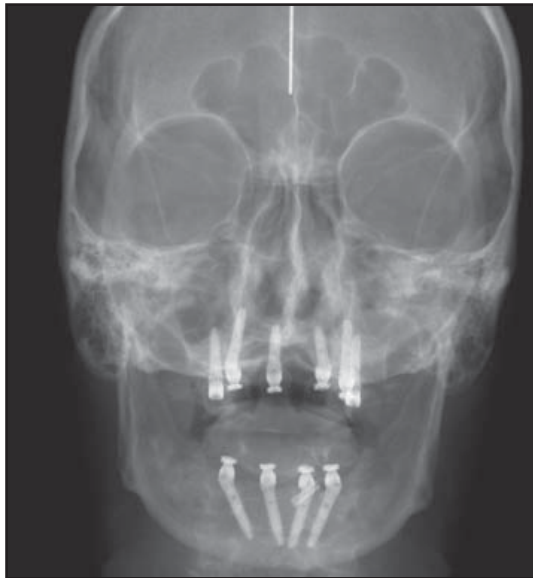Int J Oral Maxillofac Implants. 2006 Nov-Dec;21(6):919-28.

Nedir R, Bischof M, Szmukler-Moncler S,
Belser UC, Samson J.

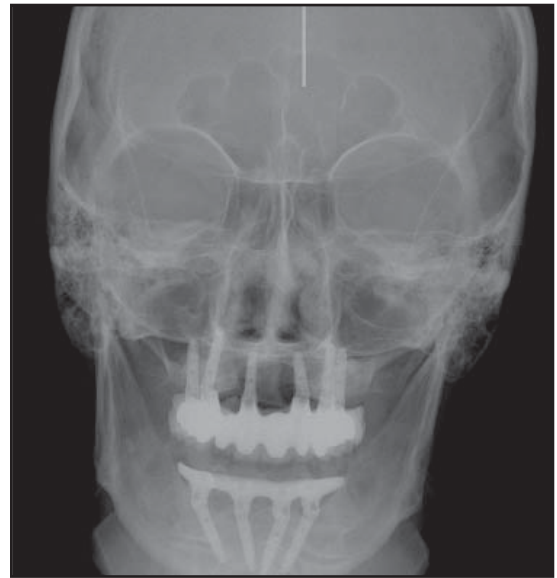A study was conducted at Department of Stomatology and Oral Surgery, School of Dental Medicine at the University of Geneva, Switzerland. An evaluation of prosthetic complication was performed on 236 patients treated with 528 implants in an 8-year private practice experience. The study sample included 55 overdentures and 265 fixed partial dentures. The study found that patients with removable prostheses had more complications than those with fixed ones, 66.0% versus 11.5%; the difference was significant ($P < .001$). In the overdenture group, the ball-retained prostheses had a significantly higher rate of complications than the bar-retained ones (77.5% versus 42.9%; $P = .04$). In the fixed partial denture group, complications were not recurrent; most occurred during the first 2 years, and the rate of complications did not increase with time. In the OD group, 1.3 incidents per prosthesis were recorded. Incidents were often recurrent, and the rate of complications did not decrease with time. In the removable group, adjustments and foreseeable complications were numerous, recurrent, and usually easy to manage. Bar-retained prostheses had fewer complications than ball-retained ones. In the fixed group, complications were limited in number and did not increase with time.



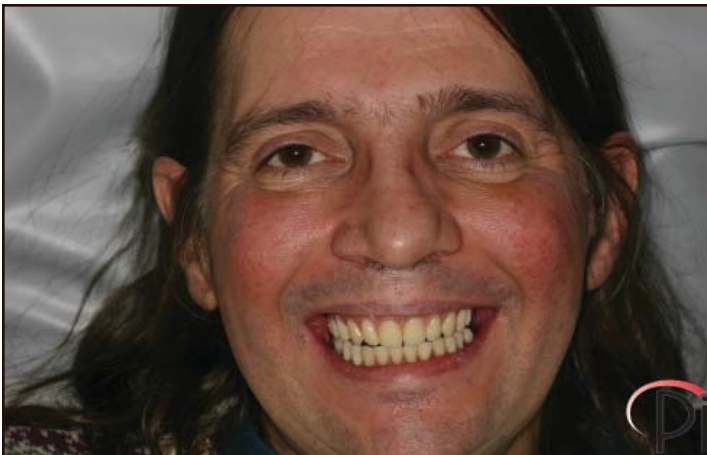All-On-Four Mandibular Prosthesis



AP Cephalometric Radiograph taken after the Teeth In A Day procedure and prior to plastic surgery shows deviated septum



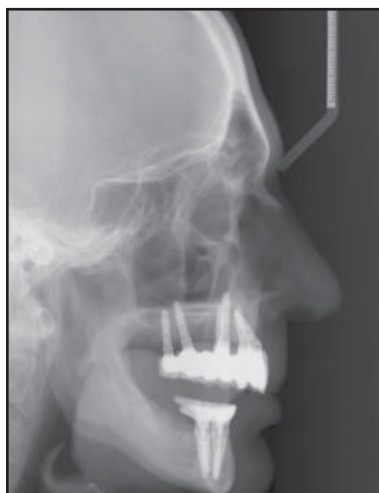Post-operative AP cephalometric radiograph with corrected deviated septum and final implant reconstructions



Patient smiles wearing the final restoration with handsome esthetics.



Time for a change!



Post-operative lateral cephalometric radiograph showing improved facial support

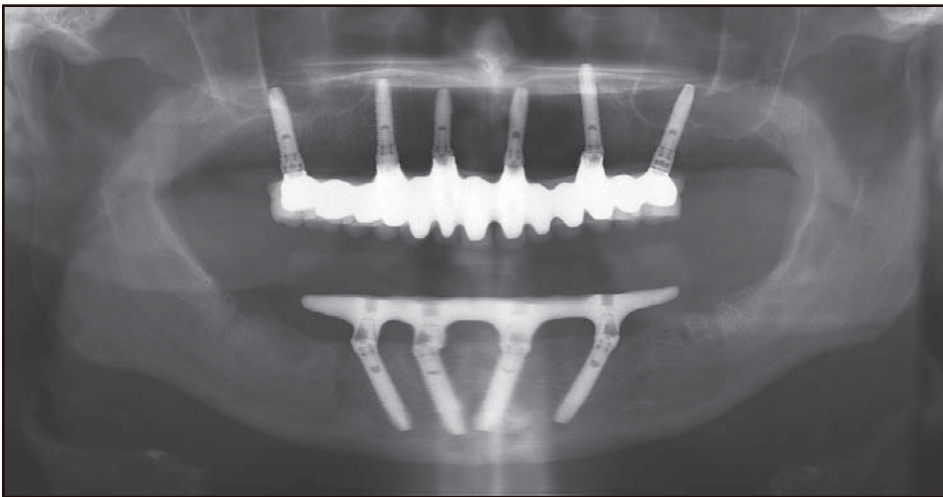
Immediate rehabilitation of the completely edentulous jaw with fixed prostheses supported by either upright or tilted implants: a multicenter clinical study.

Int J Oral Maxillofac Implants. 2007 Jul-Aug;22(4):639-44.

Capelli M, Zuffetti F, Del Fabbro M, Testori T.

The aims of this study were to assess the treatment outcome of immediately loaded full-arch screw-retained prostheses with distal extensions supported by both upright and tilted implants for the rehabilitation of edentulous jaws and to compare the outcomes of upright versus tilted implants. At 4 study centers, 342 implants were consecutively placed in 65 patients (96 implants were placed in 24 mandibles and 246 implants in 41 maxillae). The 2 distal implants were tilted by 25 to 35 degrees. Provisional full-arch restorations made of a titanium framework and acrylic resin teeth were delivered within 48 hours of surgery and immediately loaded. The final prosthesis was delivered after 3 months of healing. Three implants failed during the first year and another 2 within 18 months of loading in the maxilla. The cumulative implant survival rate for the maxilla was 97.59% for up to 40 months of follow-up. No implant failure was recorded for the mandible. The prosthetic success rate was 100%. Marginal bone loss around upright and tilted implants was similar. Patients were satisfied with their esthetics,

phonetics, and function. The preliminary results of this study suggest that immediate rehabilitation of the edentulous maxilla and mandible by a hybrid prosthesis supported by 6 or 4 implants, respectively, may represent a viable treatment alternative with respect to more demanding surgical procedures. The clinical results indicate that immediately loaded tilted implants may achieve the same outcome as upright implants in both jaws.



Post-operative panoramic radiograph

Vol. 20, No. 1 Summer 2007
PROSTHODONTIC
Insights
A Digest of Recent Trends, Techniques and Clinical Concepts of Dental and Facial Esthetics

Prosthodontic Insights is published by Pi Dental Center and distributed without charge to individuals. Please request a subscription on your organization's letterhead.

Pi Dental Center
467 Pennsylvania Avenue, Suite 201
Fort Washington, PA 19034 USA
TEL: 215-643-5881
FAX: 215-643-1149
piteam@pidentalcenter.com

Acknowledgement

Pi thanks Robert Winkelman, CDT, MDT, director of Fort Washington Dental Lab for making an exquisite porcelain fused to gold prosthesis. Thanks to CM Ceramics for making a superb mandibular prosthesis.

Insights Newsletter Staff and Contributors

Thomas J. Balshi, DDS, FACP
Glenn J. Wolfinger, DMD, FACP
John J. Thaler II, DDS
James R. Bowers, DDS
Stephen F. Balshi, MBE
Robert Winkelman, CDT, MDT
Christine Raines, Layout Editor



*Thomas J. Balshi,
DDS, FACP*




*Glenn J. Wolfinger,
DMD, FACP*



*John J. Thaler II,
DDS*



*James R. Bowers,
DDS*



FEATURING



THOMAS J. BALSCHI, DDS, FACP
Board Certified Prosthodontist



GLENN J. WOLFINGER, DMD, FACP
Board Certified Prosthodontist



STEPHEN F. BALSCHI, M.B.E.
Biomedical Engineer



ROBERT WINKELMAN, CDT, MDT
Master Dental Technician



Course Listing:



Immediate Loading of Implants With The Teeth In A Day[®] Protocol

This course reviews traditional dental implant surgery and current scientifically based techniques including Teeth In A Day[®] using lectures, computer presentation, and videos, as well as hands-on training and observation of live surgeries. Intraoral live video gives participants the "Surgeon's Eye View" of the procedure and interactive discussion. Courses are presented in a private practice clinical facility with full laboratory support.

Nobel Guide Concept[™] and Teeth In An Hour[™] 3D Computerized Implant Guided Surgery and Prosthetics Course

The NOBELGUIDE[™] Concept and the Procera[®] System is a treatment modality that uses virtual surgical planning on a computer to treat patients with a minimally invasive protocol. Evolutionary advances in CT scanning have made it possible to fully recreate the surgical site in three dimensions. A robotics factory uses CAD-CAM technology to create a surgical template that is based on the virtual planning. A prefabricated provisional can be constructed from these planning files.

The combination of surgical template, immediate loading concept and the definitive prosthesis make it possible to provide a flapless surgical procedure with a final restoration in place. This protocol is called Teeth In An Hour[™]. It shortens the patient's healing time and minimizes bruising and swelling. In one surgical visit that is less than sixty minutes, patients can enjoy a brand new fully functional smile.

Advanced Guided Surgery

This advanced course is for the clinician who is already certified and experienced with the NobelGuide[™] / Teeth in an Hour[™] protocol. Course participants are asked to bring their laptops with the Procera[®] software, as a portion of the program will require its use. More challenging tasks with the Procera[®] Software like placing implants that are tilted off axis, such as the posterior implants of the All-on-4 technique, pterygomaxillary implants, and zygoma implants are reviewed. An advanced guided surgery case is covered. Then, live patient CT data will be distributed to the course participants for conversion and 3D planning of the case. Live surgery of the same patient will follow. The live treated case will deviate from the standard NobelGuide[™] protocol and the course will emphasize the necessary steps to avoid potential inaccuracies with those deviations.

The Severely Atrophic Maxilla: Stabilizing Implants in the Pterygomaxillary and Zygoma Regions

This course will include a live surgery showing the placement of the implants along with hands-on mannequin laboratory workshop. Course highlights will include presentations on treatment planning, as well as the surgical, radiological, biomechanical, and restorative aspects of new approaches to treat the compromised maxilla.

Visit our web site: <http://pidentalcenter.com>

For more information and registration, contact Tricia at 215-643-5881 or at iffe@pidentalcenter.com

Sponsored by The Institute For Facial Esthetics and Nobel Biocare