

Complications of Mandibular Molar Replacement with a Single Implant: A Case Report

- Vicki C. Petropoulos, DMD, MS •
- Glenn J. Wolfinger, DMD, FACP •
- Thomas J. Balshi, DDS, FACP •

A b s t r a c t

This case report describes prosthodontic complications resulting from the surgical placement of a single implant and treatment following these complications. Both the surgical and prosthodontic procedures are described for the treatment of a 57-year-old man who had previously received a single implant for the replacement of a missing molar. Using 2 implants, 1 mesial and 1 distal to the previously placed single implant proved reliable. A logical treatment solution is to use 2 implants for the replacement of a single molar to avoid prosthodontic complications.

MeSH Key Words: dental implants, single-tooth; dental prosthesis, implant-supported; dental restoration failure; treatment outcome

© J Can Dent Assoc 2004; 70(4):238–42
This article has been peer reviewed.

The replacement of a single molar with 1 implant has been shown to be an effective treatment modality in short-term studies;^{1,2} however, this presents a biomechanical challenge. Occlusal forces are greatest in the molar region, leading to possible increased stress on the implant components as well as the surrounding bone.³ The screw joint for a single implant is susceptible to loosening because a torque relative to the implant axis must be counteracted by the screw joint itself.⁴ One way of controlling this load is to support a single molar replacement with 2 implants.⁴ The clinical feasibility of using 2 implants to support a molar restoration has been reported previously.⁵

Case Report

Patient History

A 57-year-old man in excellent health, with no known allergies or sensitivities to medications, presented to Prosthodontics Intermedica (Fort Washington, Pa.) with the chief complaint “my crown and post came off” (Figs. 1a and 1b). He desired an estimate for an implant. In general, the patient sought dental care only when dental emergencies occurred.

Clinical and Radiographic Examination

Initial clinical evaluation revealed parafunctional habits. Abfraction lesions were present on teeth 13, 14, 15, 24, 25, 34, 35 and 43, and incisor wear patterns were consistent with parafunction. The patient’s general periodontal condition was healthy, despite the fact that he did not seek regular professional oral hygiene. Tooth 36 had a history of endodontic therapy. Its crown was absent, there was extensive decay in the pulp chamber and a periapical radiolucency appeared at the apex of the mesial root. The tooth was determined to be nonrestorable (Fig. 2).

Treatment Options

The patient was presented with the following treatment options for the replacement of the mandibular left first molar. One option was a 3-unit fixed partial denture using teeth 37 and 35 as abutments. However, an implant restoration for the replacement of the edentulous space at tooth 36 was determined to be a more conservative option. An alternative option was to use 2 Brånemark System implants (Nobel Biocare, USA, Inc., Yorba Linda, Calif.) to support a ceramo-metal crown.

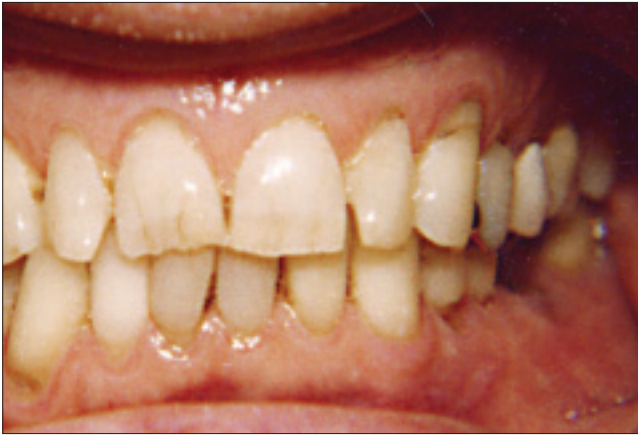

Figure 1a: Preoperative frontal view showing missing crown on tooth 36.

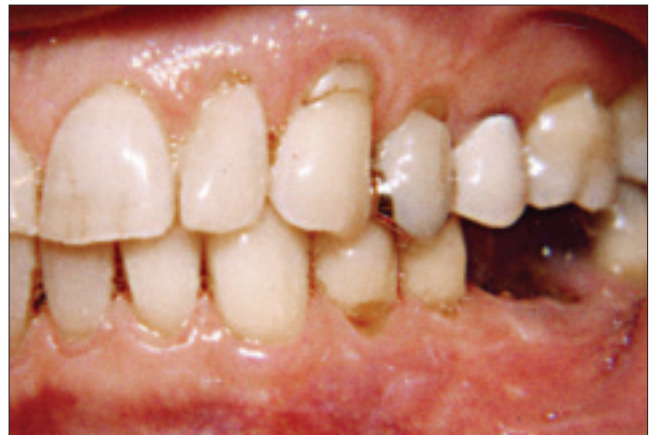

Figure 1b: Preoperative left view of tooth 36.

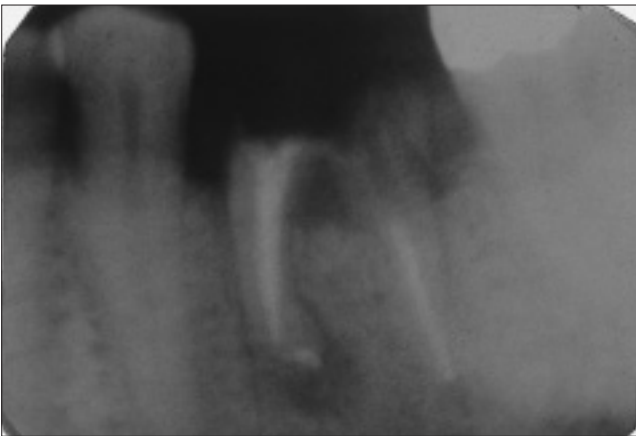


Figure 2: Preoperative periapical radiograph of tooth 36.

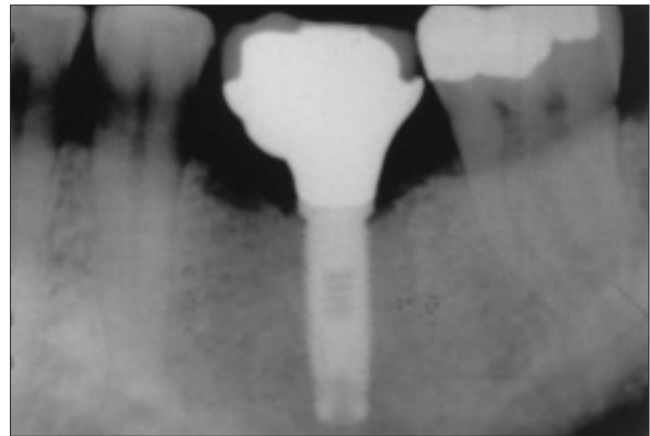


Figure 3: Radiograph of single-implant ceramic crown retained with a metal screw.

The patient was interested in the implant option; however, for financial reasons, he sought a second opinion regarding a “cheaper solution.” Within a year of his initial visit, another treating dentist had extracted tooth 36 and had restored it with a single standard-diameter implant supporting a screw-retained ceramo-metal crown (**Fig. 3**).

Two years after his initial visit, the patient returned to Prosthodontics Intermedica complaining, “my crown and screw are loose.” He returned to the clinic for several visits because of a loosening of the abutment screw. Eventually, it was recommended that an additional implant be placed and a 2-implant-supported molar crown be constructed to address the chronic screw loosening problem. The patient declined treatment due to cost.

Fifteen months after the patient’s first return visit, he presented to the clinic wearing a 2-unit ceramo-metal fixed partial denture supported by tooth 37 and an implant in the area of tooth 36 (**Fig. 4**). The retainer of the fixed partial denture was not seated on the implant replacing tooth 36, but was cantilevered off tooth 37. The abutment

screw had fractured. The patient was advised of the risk of complications that might arise from such a prosthetic design, including damage to the implant and fracture of the solder joint. Approximately 2 months later, the patient returned with the complaint of a fractured restoration. Further evaluation revealed that the solder joint between tooth 37 and the implant at tooth 36 had fractured (**Fig. 5a**).

Treatment

The abutment screw had fractured because of the biomechanical overload on the prosthesis. After removal of the fractured abutment screw (**Fig. 5b**), it was observed that the internal threads of the Brånemark System implant were damaged. In addition, the hexagonal portion of the implant was damaged due to friction caused by the ill-fitting splinted prosthesis (**Fig. 6**). Thus, it would not be possible to use the existing implant for the final restoration.

Recommendation was made for the placement of 2 new implants to support a ceramo-metal screw-retained restoration replacing the mandibular left first molar, bypassing the

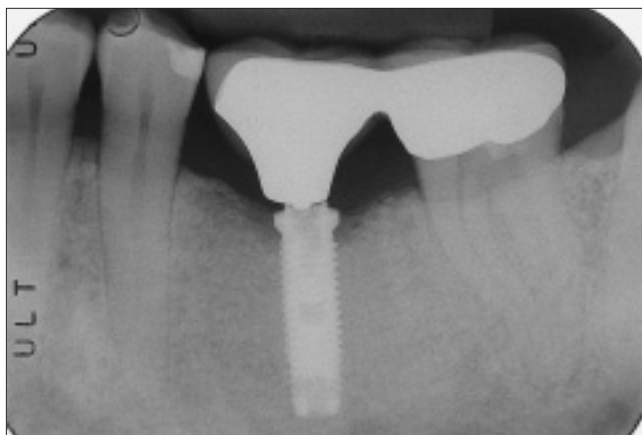


Figure 4: Periapical radiograph of splinted tissue-integrated prosthesis to tooth 37 with a ceramo-metal retainer.

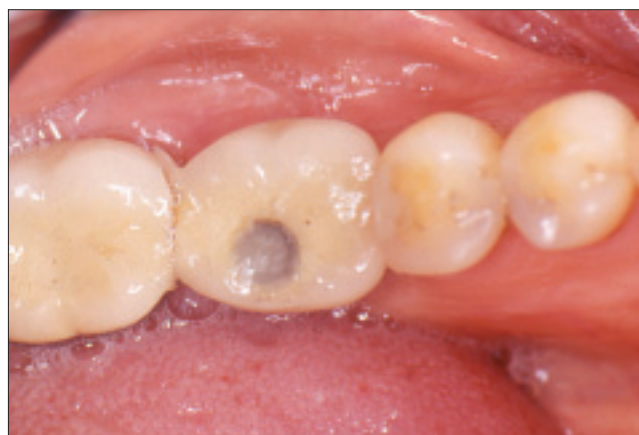

Figure 5a: Occlusal view of solder joint fracture between tissue-integrated prosthesis and tooth 37.

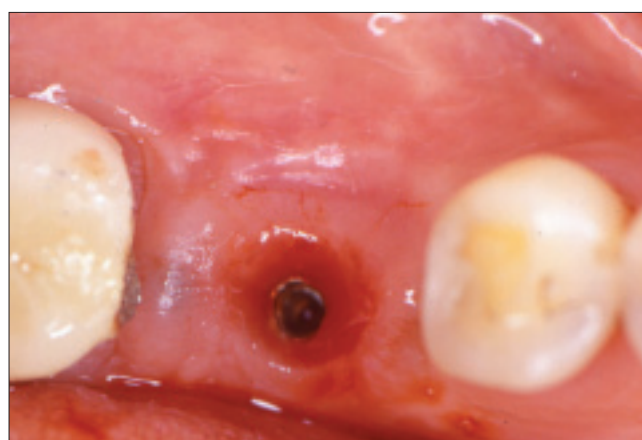

Figure 5b: Solder joint fracture between tooth 37 and implant at 36 with soft tissue irritation.

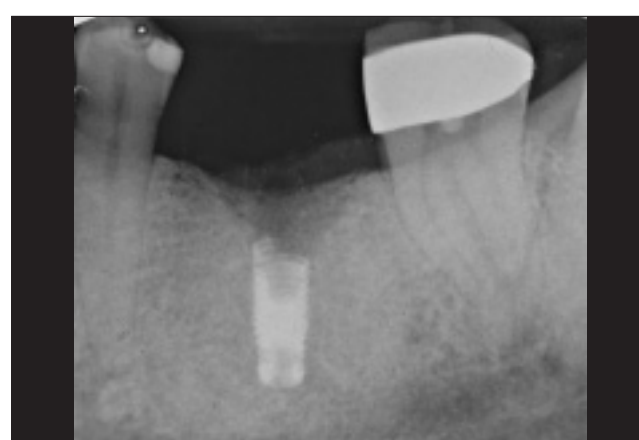

Figure 6: Fractured abutment screw in implant at site 36 with hexagonal portion of implant damaged.

previously placed implant. Consideration was given to trephining out the existing implant; however, significant bone loss and bone damage from heat generation along with paresthesia were of major concern in this patient. Instead, the implant, which was not fractured, was shortened, using copious amounts of saline irrigation, to create more room for the mesial and distal implants while preserving the bone. This was the least invasive form of treatment for this failed implant. Informed consent was obtained from the patient after all options for retreatment were explained.

In stage I of the procedure, 2 carpules of Marcaine (Cooke-Waite, Abbott Laboratories, North Chicago, Ill.) 1:200 000 were administered. A crestal incision was made, and 1 (13 mm by 3.75 mm) Brånemark System implant was placed mesially and 1 wide-diameter (12 mm by 5 mm) Brånemark System implant was placed distal to the existing modified implant. Autogenous bone from the osteotomy sites was used to graft between the 2 implants. The interdental space was 12 mm. Two standard-diameter

implants (3.75 mm) can successfully be placed in sites with as little as 10 mm of interproximal space to support a molar restoration.⁶

Eight months after the initial surgery, the abutments were connected. A 3-mm 17-degree angulated abutment was used for the distal fixture, and a 1-mm Estheticone abutment (Nobel Biocare, USA, Inc.) was used for the mesial fixture. Radiographic verification of the newly fitted abutments was obtained (Fig. 7). Screw-retained impression copings were modified for the impression procedure and, for the fabrication of a conversion prosthesis, a fixed provisional acrylic restoration was made.⁷ The fixed provisional acrylic restoration would provide for loading during stage II of surgery, and was used as an interim restoration until the final restoration was fabricated.

Laboratory procedures included the fabrication of the crown, which was made of a porcelain fused to high-gold-content alloy. The 2-implant porcelain-gold restoration was retained by 2 gold prosthetic screws, which were torqued to 10 Ncm to prevent loosening. Delivery of

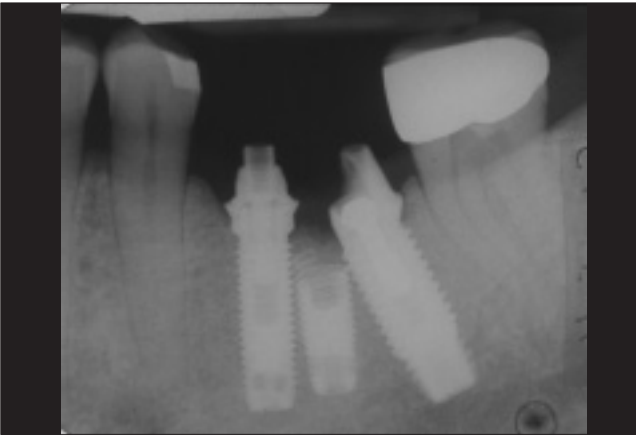


Figure 7: A periapical radiograph was taken at time of delivery to verify the abutments.

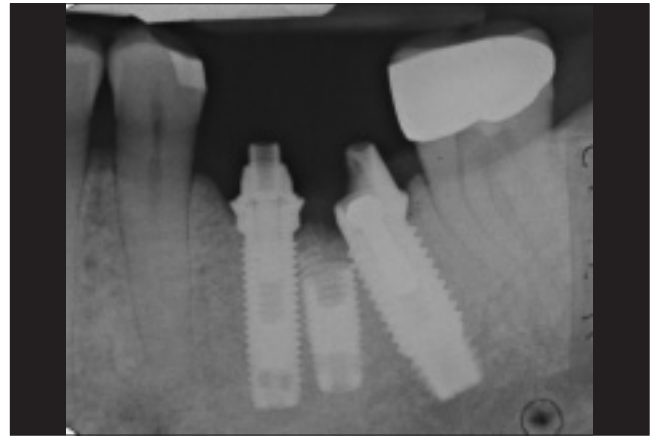


Figure 8: Periapical radiograph of tissue-integrated prosthesis taken at time of delivery.

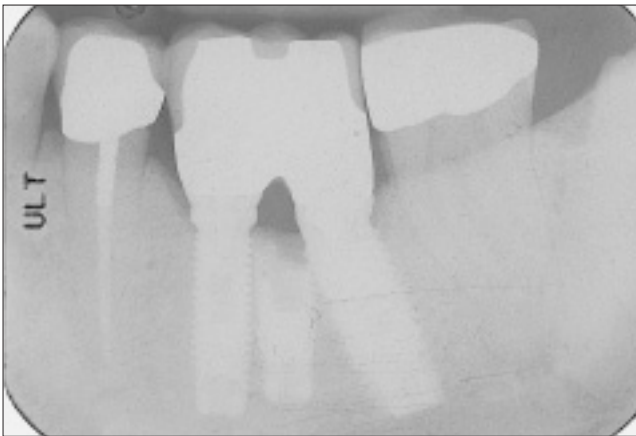


Figure 9: Periapical radiograph at 6.5-year follow-up. There is bone regeneration between the 2 functioning implants and above the sectioned implant.

the final restoration included confirmation that proximal contact allowed the patient to perform normal oral hygiene procedures using dental floss between the teeth. The buccal and lingual contours of the 2-implant-supported molar restoration and the recontouring of the left second molar restored not only the arch alignment, but also the occlusal plane, function and esthetics. The occlusal scheme for all molars was evaluated to ensure a firm centric contact with no contact in lateral excursions. A postoperative periapical radiograph (**Fig. 8**) confirmed the seating of the 2-implant-supported molar restoration at the time of delivery. Oral hygiene instructions were reinforced and the importance of periodic recall visits was emphasized.

For the past 6.5 years, the patient has been monitored at recall visits and has been doing well with the prosthesis. Radiographic evaluation has indicated a stable periodontal condition with little or no bone loss associated with the osseointegrated implants (**Fig. 9**).

Discussion

Previous studies have shown that prosthesis mobility and screw loosening are the most frequent complications associated with single-implant molar restorations.⁸ The high incidence of screw loosening may be a warning sign of potentially more serious complications, including fracture of the implant fixture, that may arise over time with these restorations, as observed by Rangert and others.⁹

This case demonstrates the biomechanical advantage of using 2 implants to replace a single molar. At the onset of treatment, the patient was trying to reduce costs by opting for a single fixture, but in the long term this was not cost effective for the patient or for the treating dentist. The use of 2 implants is especially indicated in patients who have been identified as pronounced bruxers or clenchers to overcome the masticatory overload. Dental implants are intended to replace the missing roots of teeth. For a molar, a single implant does not provide the crown-to-root ratio that previously existed and may subject the implant to overload.^{5,6} Even a wide-diameter, wide-platform implant fails to replace the crown-to-root ratio. Furthermore, wide-diameter implants leave cantilevered portions of the restoration that may create biomechanical problems.⁶ The use of 2 implants provides more surface area for osseointegration and spreads the occlusal loading forces over a wider area while reducing the potential bending forces that would exist in a single-implant molar restoration.^{6,10} Wide-diameter implants may be indicated in molar areas where space does not permit the placement of 2 implants.

A logical solution to implant overload is the use of 2 implants to replace the roots of a missing molar.⁶ Most frequently problems are observed when an implant prosthesis is underengineered. Properly engineered, this design is a more conservative and beneficial approach for both the patient and the treating dentist in the long-term. ♦



Dr. Petropoulos is assistant professor of restorative dentistry, department of restorative dentistry, University of Pennsylvania School of Dental Medicine, and consultant prosthodontist, VA Medical Center, Philadelphia, Pennsylvania.



Dr. Wolfinger is in private practice, Prosthodontics Intermedica, Institute for Facial Esthetics, Fort Washington, Pennsylvania, and staff prosthodontist, VA Medical Center, Philadelphia, Pennsylvania.



Dr. Balshi is in private practice, Prosthodontics Intermedica, Institute for Facial Esthetics, Fort Washington, Pennsylvania.

Correspondence to: Dr. Vicki C. Petropoulos, 240 South 40th Street, Suite 201C, Department of Restorative Dentistry, University of Pennsylvania School of Dental Medicine, Philadelphia, PA 19104-6003. E-mail: VPetropoulos@aol.com.

The authors have no declared financial interests in any company manufacturing the types of products mentioned in this article.

References

1. Schmitt A, Zarb GA. The longitudinal clinical effectiveness of osseointegrated dental implants for single-tooth replacement. *Int J Prosthodont* 1993; 6(2):197–202.
2. Lancy WR, Jemt T, Harris D, Henry PJ, Krogh PH, Polizzi G, and others. Osseointegrated implants for single-tooth replacement: progress report from a multicenter prospective study after 3 years. *Int J Oral Maxillofac Implants* 1994; 9(1):49–54.
3. Haraldson T, Carlsson GE, Ingervall B. Functional state, bite force and postural activity in patients with osseointegrated oral implant bridges. *Acta Odontol Scand* 1979; 37(4):195–206.
4. Balshi TJ, Hernandez RE, Pryzlak MC, Rangert B. A comparative study of one implant versus two replacing a single molar. *Int J Oral Maxillofac Implants* 1996; 11(3):372–8.
5. Balshi TJ. First molar replacement with osseointegrated implants. *Quintessence Int* 1990; 21(1):61–5.
6. Balshi TJ, Wolfinger GJ. Two-implant-supported single molar replacement: interdental space requirements and comparison to alternative options. *Int J Periodontics Restorative Dent* 1997; 17(5):427–35.
7. Balshi TJ, Wolfinger GJ. Conversion prosthesis: a transitional fixed implant-supported prosthesis for an edentulous arch — a technical note. *Int J Oral Maxillofac Implants* 1996; 11(1):106–11.
8. Becker W, Becker BE. Replacement of maxillary and mandibular molars with single endosseous implant restorations: a retrospective study. *J Prosthet Dent* 1995; 74(1):51–5.
9. Rangert B, Krogh PH, Langer B, Van Roekel N. Bending overload and implant fracture: a retrospective clinical analysis. *Int J Oral Maxillofac Implants* 1995; 10(3):326–34.
10. Bahat O, Handelsman M. Use of wide implants and double implants in the posterior jaw: a clinical report. *Int J Oral Maxillofac Implants* 1996; 11(3):379–86.