

Case of the Month

No Bone Solution™ Computer Guided Implant Surgery Protocol for Prosthodontic Rehabilitation of the Severely Atrophic Maxilla

Thomas J. Balshi, DDS, FACP¹ • Glenn J. Wolfinger, DDS, FACP¹
John J. Thaler II, DDS¹ • James R. Bowers, DDS¹
Stephen F. Balshi, MBE²

Abstract

Background: Prosthodontic rehabilitation of the severely atrophic maxilla presents significant challenges to the restoring dental team. Inadequate bone quantity often necessitates time dependent augmentation procedures that considerably delay delivery of the final dental prostheses. This case report demonstrates a newly developed specialized computer guided dental implant surgery protocol for prosthetic rehabilitation of the severely atrophic maxilla: the No Bone Solution.™

Methods: A 67 year old Indian male with a somewhat compromised medical history and severely atrophic maxilla presented for rehabilitation with dental implants. The patient was treated with the No Bone Solution™ protocol for delivery of 5 standard Brånemark implants and 4 Bråne-

mark System® Zygoma implants. The patient received an immediate fixed screw retained provisional prosthesis on the day of surgery and was restored with a final prosthesis 5 months later.

Results: Surgical treatment and implant delivery utilizing the No Bone Solution™ protocol were uneventful. The patient's maxillary prosthetic rehabilitation has been without complication for 3 years following surgery.

Conclusion: The No Bone Solution™ computer guided implant surgery protocol provides a restorative option for patients with severely atrophic maxillary bone. This protocol does not require bone augmentation and significantly reduces total treatment time.

KEY WORDS: Dental implants, zygoma, maxilla, cone beam computed tomography, CAD/CAM, osseointegration

1. Pi Dental Center, Fort Washington, PA, USA.

2. CM Ceramics, Mahwah, NJ, USA

CASE REPORT

Long-term success of osseointegrated implants depends on the length of the implants used and the quality and quantity of bone surrounding these implants. As surgical and prosthetic techniques have evolved, the success rate for routine implant treatment has improved and implant prosthodontics has become the standard of care.

A 67 year-old retired surgeon was referred to the Pi Dental Implant Center by his periodontist and restorative dentist in April 2007 with a prior diagnosis of "no bone in the maxilla." This patient's desire for treatment included "fixed teeth" with improved oral function and esthetics. Some of his medical conditions were potentially detrimental to the long-term prognosis of complex dental treatment, but not insurmountable. The patient was diagnosed with diabetes, emphysema, high blood pressure and dry mouth syndrome. To further complicate matters, he smoked two packs of cigarettes a day and admitted to an intense parafunctional bruxing and clenching habit.

Initial Clinical and Radiographic Assessment

After a thorough oral examination, which included evaluation of the existing prosthetics, articulated diagnostic casts, panorex radiograph, lateral cephalometric radiograph and preoperative clinical photographs, the following treatment plan was developed using the No Bone Solution™ protocol.

Treatment Plan

(1) Removal of the non-integrated "mini" implants in the area of teeth 14 and 15. (2) Fabrication of a new maxillary denture that incorporated radiographic markers to be used in conjunction with an i-Cat cone beam scan. (3) NobelGuide™ guided

surgery for placement of five traditional Brånemark implants and freehand placement of four zygomatic implants to support an interim all acrylic screw-retained fixed prosthesis. After 12 weeks of healing and osseointegration, the fixed screw retained titanium and ceramic prosthesis was fabricated.

Computer Plan

A virtual plan of the intended surgery was completed using the Nobel Biocare Procera software. Computer data was transmitted to a rapid prototype machine for production of the surgical template. Using this template, a master cast was constructed and articulated. The screw retained provisional prosthesis was then constructed prior to dental implant surgery.

Surgical Protocol

Blood was drawn prior to surgery, transferred to the Harvest cell separator unit and Platelet Rich Plasma was prepared. General anesthesia was then administered and the patient was fully draped using the standard sterile protocol. Local anesthesia was also used for hemostasis. Following the guided portion of the surgery, which assists in the placement of 5 Brånemark implants, the surgical template was removed. A crestal incision and vertical releasing incisions were made bilaterally and full thickness flaps were elevated to the level of the superior aspect of the zygomatic bone. The transantral osteotomies, using graduated diameter drills, were completed to permit the apex of the implants to penetrate through the lateral surface of the zygoma. A total of four Brånemark System® Zygoma implants were installed—two in each zygoma. Finally, using the Teeth In A Day® conversion protocol, the previously constructed prosthesis was installed on the standard Bråne-

mark implants and then connected intraorally to the zygomatic implants. The prosthesis was then removed, adjusted, polished and reinstalled.

The Final Prosthesis

Osseointegration, under immediate loading conditions is paramount to the success of this prosthesis. Research on immediate loading has shown that after eight weeks, osseointegration should be mature to allow for a predictable outcome. Due to this patient's numerous medical conditions, the final impression was taken after a 12-week healing time. He was restored using CM Ceramics technology produced in Mahwah, New Jersey. The final prosthesis for the maxilla consisted of a CAD/CAM robotically milled titanium frame with individual zirconium ceramic crowns using the Nobel Biocare Procera Technology.

CONCLUSION

Patients with extreme maxillary atrophy generally suffer with ill-fitting removable prostheses that chronically irritate the mucosa and insult what little underlying bone remains. For patients with no remaining alveolar bone, the No Bone Solution™ protocol demonstrated in this article is an ideal treatment that avoids major bone grafting and the long associated healing and treatment time. The No Bone Solution™ potentially shortens treatment time to only 3 visits over a 3-month period. It also provides patients with little or no bone with a non-removable solid set of teeth in just one day.

No Bone Solution™ is a special treatment protocol developed at the Pi Dental Center. It combines unique computer guided implant surgery with precision screw retained fixed prosthodontic rehabilitation of the severely atrophic maxilla. The protocol eliminates the need for invasive bone grafting and extensive procedures ●

Correspondence:

Dr. Thomas J. Balshi
467 Pennsylvania Avenue, Suite 201
Fort Washington, PA 19034 USA
TEL: 215-643-5881
FAX: 215-643-1149
piteam@pidentalcenter.com

Disclosure:

The authors of this article disclose that they have agreements and/or financial arrangements with the Pi Dental Center and Nobel Biocare®.

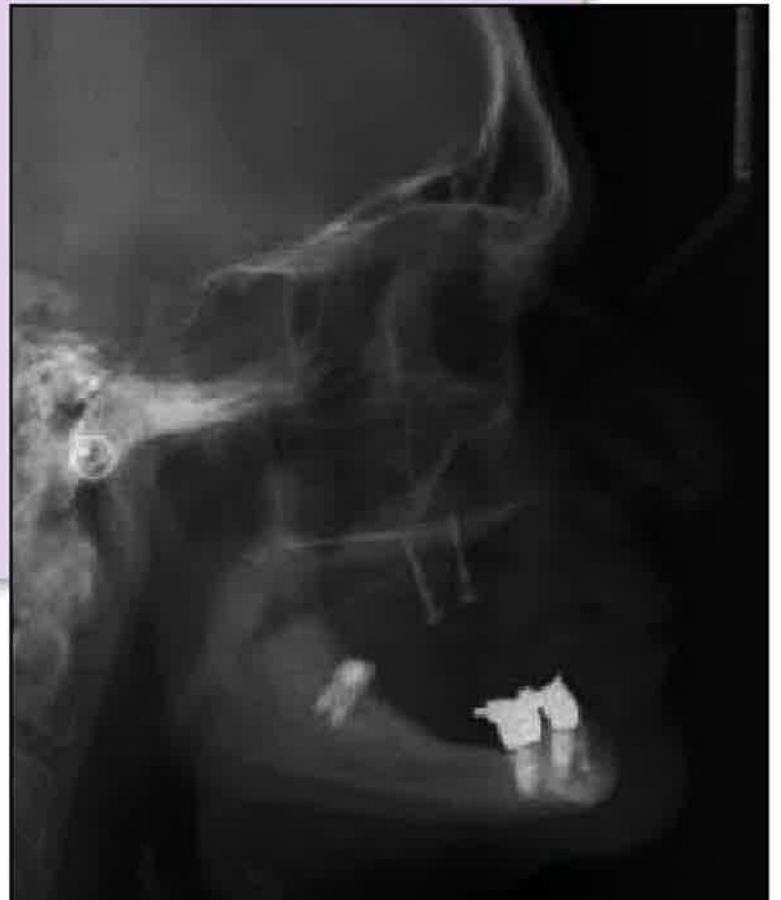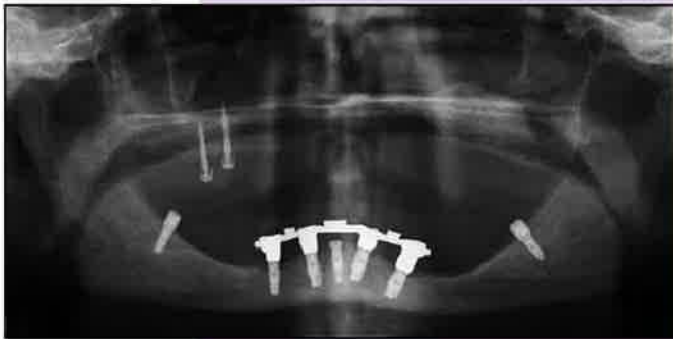
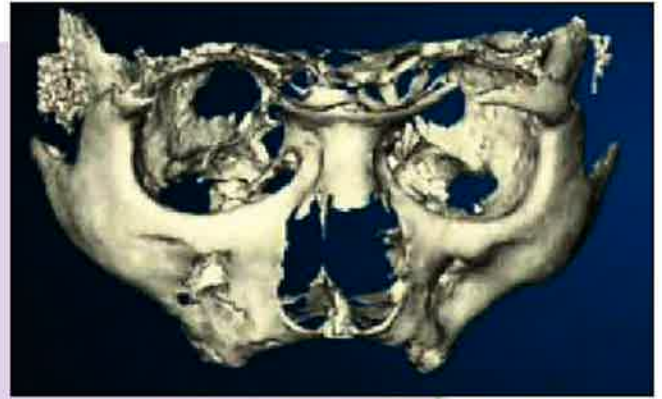
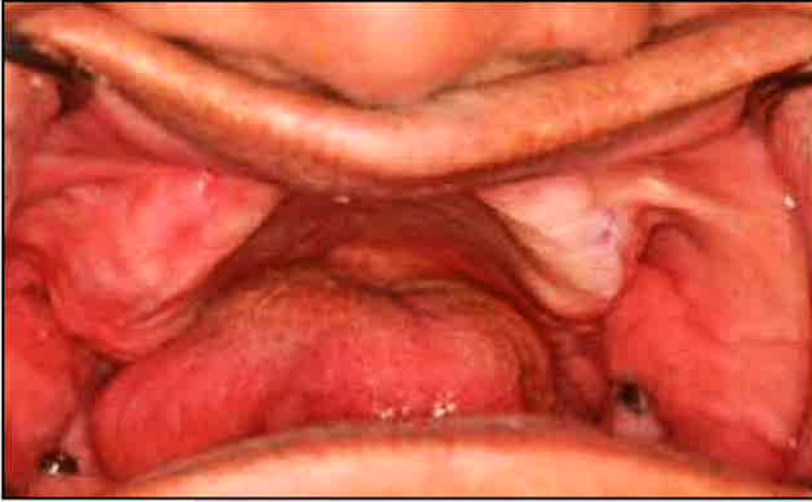Acknowledgement

The Pi team gratefully thanks two dedicated dental specialists, Dr. Russell Morgan, Restorative Dentist and Dr. Gregory Felthousen, Periodontist (both of Salisbury, MD) for extraordinary "insights" in their encouragement and genuine concern for the patient illustrated in this issue. Likewise, we also acknowledge numerous colleagues who have provided similar guidance to clinically "hopeless" patients.

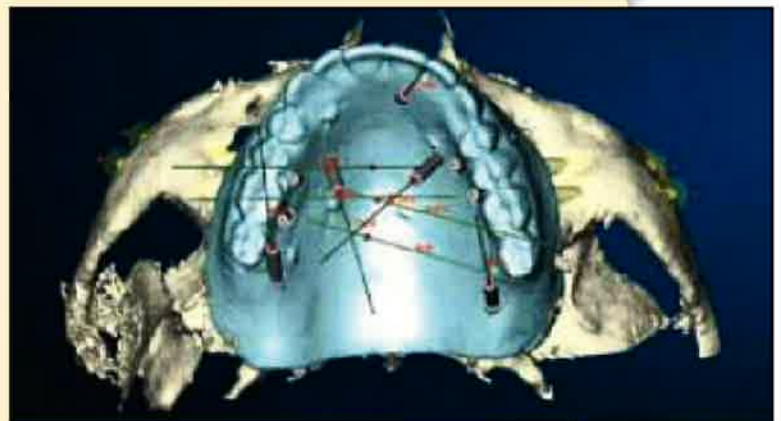
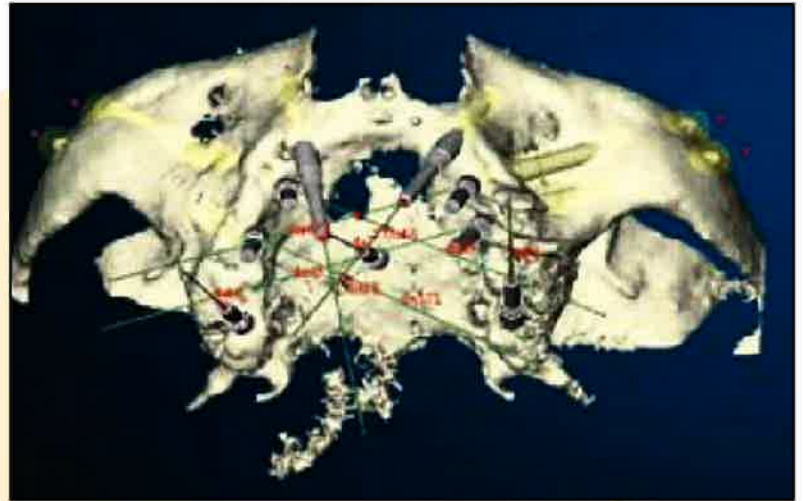
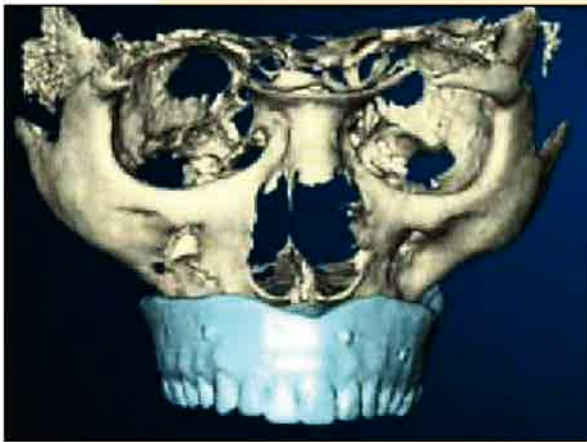Lab Support:

Stephen F. Balshi, MBE
CM Ceramics, LLC

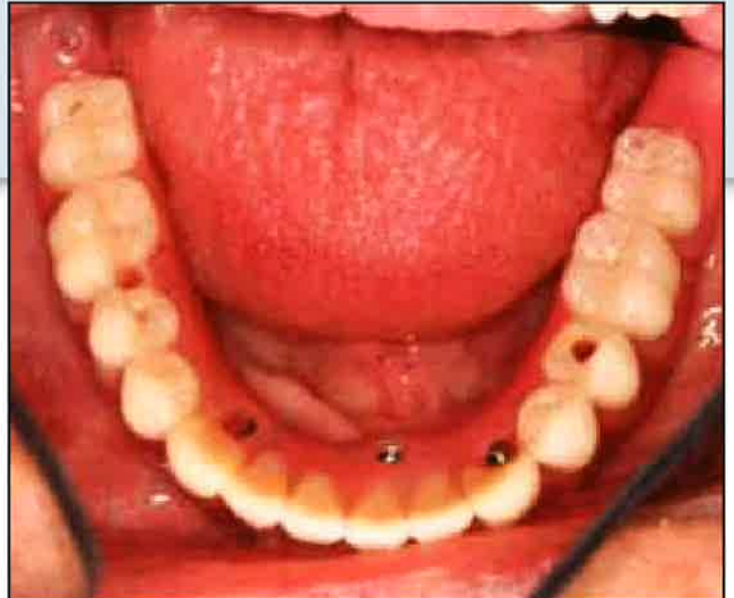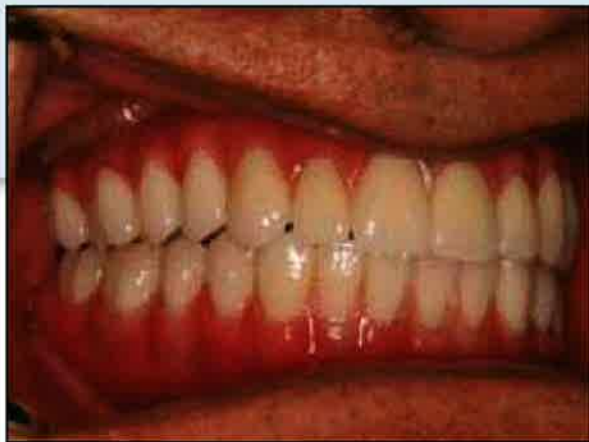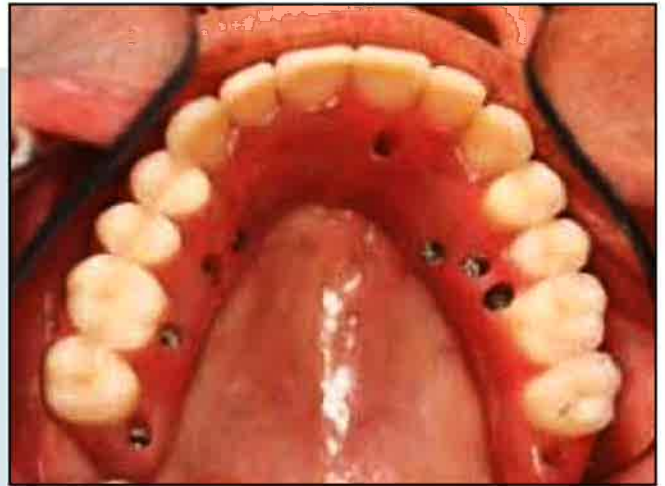
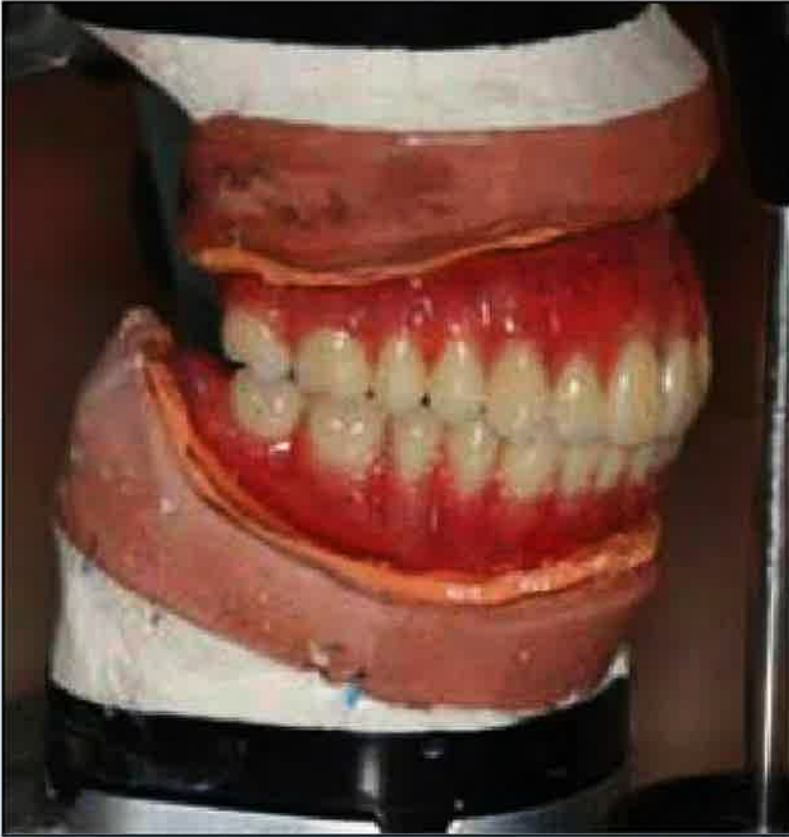INITIAL PRESENTATION



PRE-SURGICAL PLANNING



FINAL PROSTHESES



POST-SURGICAL RESTORATION

