



### Chlorhexidine in Prosthodontics

Thomas J. Balshi, D.D.S., F.A.C.P.

In dental practices today, antimicrobial agents are rapidly becoming accepted as an adjunct to traditional mechanical oral hygiene measures. These oral rinses have a potential impact on plaque control, the basis for most dental disease today. The most powerful agent is chlorhexidine, marketed as Peridex (chlorhexidine gluconate 0.12%), which is the only prescription oral rinse accepted by the ADA's Council on Dental Therapeutics under its guidelines for chemotherapeutic control of supragingival plaque and gingivitis. Chlorhexidine gluconate at 0.12% has been prescribed for the control of gingival inflammation and bleeding and related oral conditions. These benefits can contribute to improved success rates in prosthodontic procedures, serving to increase patient benefits.

Recently, chlorhexidine has been used in conjunction with crown and bridge procedures, which can be compromised by patients with gingival inflammation and bleeding. Specifically, the compound has been shown to be beneficial as a pre-therapy for impression procedures, during the interim period before final crown seating, and after the procedure to facilitate the patient's return to optimal gingival health.<sup>1</sup>

<sup>1</sup>Sorensen J, Doherty F, Flemmig T, et al: Gingival enhancement in fixed prosthodontics. *J. Dent Res.* 1988;67 (special issue): Abstract 2901.

continued on page 5

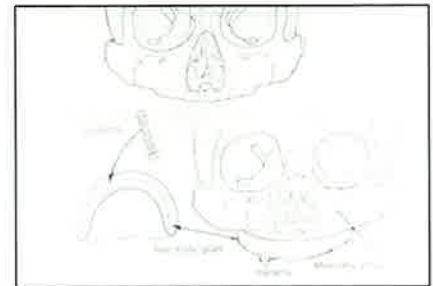
## Academy of Osseointegration Annual Scientific Session, Dallas 1988

### Composite Grafts in Maxillary and Mandibular Reconstruction

E. E. Keller, D.D.S.

The literature pertaining to placement of dental implants into bone grafts is quite limited. Two papers which deserve attention and should be read by those interested in pursuing this field are published by our Swedish colleagues at the Institute of Biotechnology in Goteborg and appeared in the *Scandinavian Journal of Plastic and Reconstructive Surgery* in 1980 and 1981. The paper reports on 245 operated jaws and placement of 1,145 Branemark implants. In this group there were 10 maxillary patients and 6 mandibular patients involving bone grafting in concert with titanium (Branemark) implants.

Maxillary cases were divided into two groups: the first group entitled "immediate placement" consists of five patients where autogenous onlay iliac bone graft is placed simultaneously with (Branemark) implants. The implant extends through



Bone graft with immediate implant placement.

the onlay bone graft into the residual atrophic maxilla. The implant provides graft stabilization and eventually functions as bone anchorage for the maxillary osseoprosthesis. This technique utilizes lateral cortex iliac bone. This method of iliac graft procurement differs from traditional procedures and deserves special mention. The graft is obtained from the medial cortex and superior aspect of the iliac crest just posterior to the anterior-superior spine. The lateral-superior crest cortex and associated musculature is left intact

continued on page 5

### "Osseointegrated" Interfaces— Biomechanical Testing and Histological Evaluation

J. B. Brunski, J. A. Hipp,  
G. V. B. Cochran, and K. W. Higuchi

Clinical success over 15 years with "osseointegrated" dental implants in Sweden has been achieved with direct, or nearly direct, interfacial apposition of mineralized tissue to implant surfaces. Most dental and orthopedic implants are intended to bear loads and require that the implant-tissue interface be capable of transmitting loads without adverse interfacial responses. This study's goal was to quantitatively investigate the relationship between interfacial responses and implant-tissue biomechanics. Bone-implant interfaces exposed to known loaded and control conditions in an animal model were analyzed by histomorphometric methods.

Twenty-four screw shaped, pure titanium implants were placed bilaterally in

continued on page 6

### Biomaterial and Implant Surfaces: A Surface Science Approach

Kengt Kasemo and Jukka Lausmaa

When a biological system encounters an implant, reactions are induced at the implant-tissue interface. This paper deals with various surface properties that are expected to influence the tissue-implant reactions, and with methods that are available for implant surface characterization.

The authors have emphasized that the primary interaction between an implant and its host tissue takes place on the atomic/molecular level at their interface. The biological reactions on the cellular and macroscopic levels that are implant-related are a consequence of the molecular-level interactions. For these reasons the status of implant surfaces is of central importance in biological evaluation of implants, as well as in clinical use of implants. The surface properties of interest are chemical composition, microstructure,

continued on page 6

**The Use of Chlorhexidine Gluconate (Peridex) to Establish and Maintain Gingival Health Associated with Teeth Treatment Planned for Fixed Prosthesis**

G. T. Terezhalmay, D.D.S., M.A.  
C. Farah, D.D.S., M.S.D.  
Case Western Reserve University,  
School of Dentistry

It is well established in the literature that there is a direct relationship between gingival health and the prognosis of fixed prostheses. Their success is significantly influenced by plaque retention, gingival inflammation, and gingival bleeding. The efficacy of 0.12% chlorhexidine gluconate (Peridex) to significantly reduce plaque retention, gingival inflammation, and gingival bleeding in a variety of clinical settings prompted the authors to include Peridex rinses in the protocol to be followed with patients' treatment planned for fixed prostheses. Five phases of fixed prosthodontic procedures were defined: I—priority treatment, such as emergency care; II—disease control and selected procedures such as (a) oral hygiene instruction, (b) extraction of non-restorable teeth, and (c) management of periodontal condition; III—restoration of function and aesthetics; IV—reevaluation; and V—recall phase. In the second phase, following initial periodontal preparation, patients were instructed to rinse with ½ oz.

**Educational Opportunities Sponsored By The Institute For Facial Esthetics— Pennsylvania's Official Branemark Training Center**

**Prosthetic Training Program For The Branemark Method Of Osseointegration**

—Two day session includes hands-on instruction.

Feb. 24 & 25, 1989; Plymouth Meeting, PA  
Apr. 28 & 29, 1989; Plymouth Meeting, PA  
July 28 & 29, 1989; Plymouth Meeting, PA  
Nov. 17 & 18, 1989; Plymouth Meeting, PA

**Travel Course:**

June 19-21, 1989; Denmark  
"Advances in Prosthodontics Using Branemark Implants"

**Advanced Osseointegration Course:**

1 day, May 12, 1989; Ft. Washington, PA  
1 day, Sept. 22, 1989; Ft. Washington, PA

**Special 6-Day Clinical Course:**

Your patient will undergo examination, fixture installation and all prosthetic procedures. Course will be held on September 6, 7, 8 and December 6, 7, 8, 1989; in Fort Washington, PA.

For more information call:  
215-643-5881

of Peridex twice daily, after breakfast and before bedtime following brushing and flossing. This regimen is followed for a minimum to two weeks before initiating the prosthetic restoration. The longer a patient remains in phase II, the more significant is the reduction in plaque retention, gingival bleeding, and gingival inflammation. The above regimen is continued through the crown preparations, making of impressions, temporization of abutments, and delivery of the fixed prosthesis. Clinical observations indicate continued improvement in gingival health through the reevaluation phase. The entire evolution, from the initial appointment to the final treatment is approximately three months. Following reevaluation, if no further treatment is indicated, the treatment plan progresses to the recall phase.

The adjunctive use of an antimicrobial agent, such as 0.12% chlorhexidine gluconate (Peridex), significantly enhances the clinician's ability to optimally improve and maintain gingival health before, during, and immediately after the fabrication and cementation of fixed prostheses. This enhancement is germinal to clinical success.

**Gingival Enhancement in Fixed Prosthodontics: 1. Clinical Findings**

J. A. Sorensen  
UCLA School of Dentistry

The effectiveness of 0.12% chlorhexidine gluconate (Peridex) in reducing plaque and subsequent gingival inflammation is well documented. The purpose of this study is to assess the usefulness of Peridex in the enhancement and maintenance of gingival health in patients receiving fixed prosthodontic treatment. Nine of 30 patients were matched into two groups, with one group using Peridex 15 ml bid in addition to normal hygiene. The product was used for 2 weeks prior to crown preparation, 3 weeks during provisional crown placement and 2 weeks after definitive crown cementation.

Plaque, gingivitis and bleeding indices were measured initially and at the 3 aforementioned points during the 7 week period. Plaque indices for control patients remained unchanged (.38 - .21) while Peridex patients were reduced from .68 to undetectable at 7 weeks. The gingival index of Peridex patients was reduced throughout the entire study period (BL = 1.87, 7 wks = .65). Subjective responses of the doctors highlighted the increased ease of prosthodontic procedures especially during crown preparation and impression phases in patients using Peridex.

*The adjunctive use of peridex with fixed prosthodontic procedures improves gingival health making the crown fabrication process easier, more expedient,*

*ultimately improving the quality of the crown margin.*

This study was funded by a grant from Procter & Gamble Co.

\* Gingival enhancement in fixed prosthodontics. *J. Dent Res* 1988:67 (special issue): Abstract 2901.

**Hydroxyapatite and Osseointegrated Implants**

The Institute for Facial Esthetics would like to thank the staff of Insights and all the surgeons and prosthodontists who responded to the hydroxyapatite survey conducted earlier this year. The data is being correlated and a summary will be published in the near future.

**Advanced Implant Course**

June 19-21, 1989

**Advances in Prosthetics Using Branemark Osseointegrated Implants**

Skagen, Denmark

Faculty:

Prof. P-I Branemark, M.D., Ph.D.  
Thomas J. Balshi, D.D.S., F.A.C.P.  
Torsten Jemt, D.D.S., Ph.D.  
William R. Laney, D.D.S.  
Hans Nilson, D.D.S.  
Bo Rangert, Ph.D., Mech. Eng.

For information call:  
The Institute For Facial Esthetics  
215-643-5881,  
or write  
IFFE, Box 1141,  
Fort Washington, PA 19034

**Osseointegration for the Periodontally Compromised Patient**

Thomas J. Balshi, D.D.S., F.A.C.P.

Osseointegrated titanium implants as developed by Branemark have proven effective in the treatment of complete edentulism. Titanium fixtures with a specific screw-shaped configuration and special surface finish, according to the "osseointegration procedure" prescribed by Branemark et al, can produce a strong, intimate, and long-lasting connection between the implanted fixture and living bone.

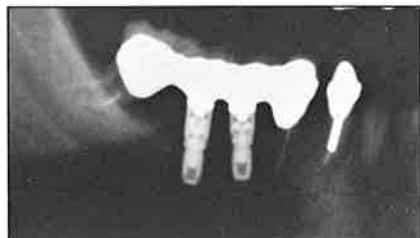Since 1965, patients have been restored with bone anchored fixed partial dentures that approach or equal the function of dentate individuals with the same quality and distribution of teeth. More recently, osseointegrated titanium fixtures

have been used for the restoration of the partially edentulous dentition, as well as the use of the Branemark tissue integrated prosthesis to restore the hemidentate arch.

The use of the tissue integrated prosthesis supported by Branemark fixtures for the restoration of the partially edentulous periodontally compromised dentition has been demonstrated with a patient study. Clinical and laboratory aspects of treatment include the diagnosis and treatment planning required for the use of the tissue integrated prosthesis to stabilize adjacent mobile teeth.

Laboratory points important to note include: casting design and fabrication, porcelain application, and especially the avoidance of porcelain particles in the access screw holes. Clinical points important to note include: the master impression technique, modification of the provisional restoration, verification of fit, delivery of the final tissue integrated prosthesis, and oral hygiene maintenance.

In the author's experience, all patients who have received a sectional tissue integrated prosthesis to restore partial edentulism have responded favorably to treatment and identify comfort and function as the most important aspects. In addition, many of these patients felt that the elimination of a removable prosthesis and its replacement with the osseointegrated fixed prosthesis had positive psychologic benefits and a definite improvement in the quality of their lives.



*Adjacent teeth stabilized with osseointegrated implants.*

\* *Int. J. of Pros.* V1, #1; 1988:51-58.

## **N.I.H. Consensus Development Conference**

### **Dental Implants—June, 1988**

The use of dental implants to provide support for replacement of missing teeth is becoming an important component of modern dentistry. It has been estimated that the overall number of dental implants inserted in the United States increased fourfold from 1983 to 1987, and during that same period, the number of practitioners who perform implant therapy increased tenfold.

According to the 1985-1986 National Institute of Dental Research's (NIDR) national survey of oral health, approximately 42 percent of those 35 to 64 years of age are totally edentulous.

Traditional removable dentures or fixed bridges are not satisfactory for a significant number of individuals who have lost the tooth-bearing portions of the bone and simply cannot manage removable appliances. Moreover, there is a strong suggestion that a substantial number of patients prefer implant-supported prostheses over soft tissue supported prostheses.

The NIDR in conjunction with the National Institutes of Health (NIH) Office of Medical Applications of Research and the Food and Drug Administration convened a consensus development conference on June 13-15, 1988. They reported:

There is evidence from a number of case series studies that a large proportion of specific types of dental implants remain in place for periods of 10 years or more when inserted by clinicians experienced with the respective techniques. Additional knowledge about the biology of hard and soft tissues, coupled with technological advances in the construction and insertion of various implants, will likely result in a trend toward improved long-term success rates. The best reported long-term survival rates have been achieved with systems that have bone at the interface (such as the Branemark system of osseointegration\*).

With regard to indications for a specific implant type, the bone available to support the implant is the primary factor after prosthodontic diagnosis and treatment plan. Other factors affecting indications for implant type are the degree and location of the edentulism of the patient.

The panel recommends that the individual who assumes the surgical treatment phase be well prepared in accepted surgical methodologies. The panel also recommends advanced instruction in the prosthodontic phase of implantology.

This program also should include expertise in short and long-term tissue maintenance addressing gingival status as well as radiographic evaluation of tissue support.

Patient selection should be restricted to those patients who show a need and motivation for the implant procedures.

The panel supports the need for a multidisciplinary approach and recommended a pre-implant consultation involving professional participants with the patient. Post-implant procedures should include communication, monitoring, and collection of recorded data by the professional team. The panel recommended that the patient be thoroughly instructed in maintenance therapy with the understanding that the patient do oral self care.

Before surgery, a medical history should be taken to evaluate the history of the presenting problem and chief complaints. A review of the current status of the organ systems should be made. Factors related to prediction of health risks need to be continuously assessed before the surgical decision, after implantation, and at 6-month intervals throughout the followup period.

The release of constituent material from the implant may influence biocompatibility. To achieve a more complete understanding of tissue response to the implant, basic experiments in host implant physiology must be continued.

Among the factors involved in the design of an implant are the force components produced during loading, the dynamic nature of loading, and the mechanical and structural properties of the prosthesis. Such information is essential for appropriate design of implants.

The panel feels that one important method of accumulating accurate data on implant performance is to establish a National Dental Implant Registry, which will standardize reporting forms to collect information on this activity in the United States. Consideration also should be given to the establishment of centers for training, treatment, and research in dental implantology.

The public is entitled to educational materials that enable informed participation in implant treatment decisions.

The panel concluded that the indications and contraindications of various types of dental implants have been described. The complexity of the surgical, prosthodontic, and periodontal procedures used to successfully insert and maintain dental implants demonstrate the need for a multidisciplinary approach in this field. Long-term studies that concurrently compare various types of implants are needed to provide information beyond mere survival rates. Functional success of various implants should include such criteria as ability to support fixed or removable prostheses in the absence of discomfort, the presence of satisfactory esthetics, and clinical and radiographic evidence of tissue health.

\* Editor's comment.

## **PROSTHODONTIC** *Insights*

is published by Prosthodontics Intermedica and distributed without charge to qualified individuals. Please request a subscription on your organization's letterhead.



*Fixed, Removable,  
and Implant Prosthodontics*

Prosthodontics Intermedica  
467 Pennsylvania Avenue  
Fort Washington, PA 19034 U.S.A.  
Telephone: 215-646-6334

## Single Tooth Implant Supported Restorations

Steven G. Lewis, D.M.D.  
John Beumer III, D.D.S.  
George R. Perri, D.D.S.  
Wynn P. Hornburg

The initial concept of the Branemark implant system provides adequate treatment designs for the edentulous mandible and maxilla with predictably successful results. However, the single tooth implant supported restoration has been an especially difficult one to achieve successfully because of problems of rotation and loosening, as well as esthetic compromises in the anterior region. The titanium abutment cylinder, as it emerges above the gingiva, is visible and often esthetically unacceptable.

A plastic cylinder that connects directly onto the Branemark implant fixture has been developed. Known as the "UCLA" abutment, this cylinder eliminates the use of the abutment cylinder and gold cylinder assembly. The plastic cylinder is incorporated within the wax pattern and allows the completed restoration to fit directly onto the implant fixture. The plastic abutment and wax pattern may be designed for porcelain-fused-to-metal, resin-to-metal, or an all-metal restoration.

The "UCLA" abutment allows placement of porcelain subgingivally on the final restoration and the final casting includes a hexagonal base to prevent rotation of the restoration.

The single tooth implant supported restoration fabricated with the "UCLA" abutment provides function and excellent esthetics, and maintains proper contours for oral hygiene.

When used appropriately, this technique can provide an extremely esthetic restoration with less opportunity for rotation and loosening when compared to the conventional method of connecting the restoration to the abutment cylinder.

\* *Int. J. Oral Maxillofacial Implants* 1988; 3:25-30.

## A Retrospective Multicenter Evaluation of Osseointegrated Implant Supporting Overdentures

Bo Engquist, D.D.S.  
Tom Bergendal, D.D.S., Ph.D.  
Thomas Kallus, D.D.S.  
Ulf Linden, D.D.S.

Fixed prostheses supported by osseointegrated implants ad modum Branemark have been used for many years in oral rehabilitation with excellent results. Varying clinical situations have also resulted in a demand for overdentures supported by fixtures.

An improvement in oral function, approaching the level of dentate individuals,

has been reported after rehabilitation of edentulous patients with fixed partial dentures supported by osseointegrated implants. In addition, the functional benefits of retaining and supporting complete dentures by radicular attachments have been clinically documented. Preliminary results indicate the functional benefits of this technique, by which it would be possible to provide the edentulous patient with a stable denture and increased load-bearing capacity with a limited clinical and financial effort. Furthermore, the overdenture concept may be advantageous in certain clinical situations, eg, severely resorbed upper jaws, unfavorable jaw relations, cosmetic enhancement, for phonetic reasons, and where maximal soft-tissue support is required.

This article summarizes the knowledge and clinical experience of different Swedish teams treating patients with overdentures supported by osseointegrated implants. It also constitutes a basis for further prospective studies on overdentures supported by fixtures. Eleven Swedish centers responsible for treating the majority of patients with overdentures supported by fixtures were invited to participate in this study. All teams were trained in the endosseous implant technique ad modum Branemark and used approximately the same follow-up routines.

The results indicate that the anatomic prerequisites are of utmost importance for the outcome of overdenture therapy. A lower and upper jaw with a resorption and bone quality gradation of 1 to 3 seems to be reasonably favorable. The development of more reliable diagnostic criteria for assessment of jawbone quantity and quality as a basis for implant treatment is therefore an important future project.

The results of the study showed that the investigated material exhibited a high occurrence of fixture losses prior to loading with prostheses and that failure rates on patients with inferior bone quality were considerably higher in overdenture therapy than earlier reported with fixed prostheses. However, in lower jaws, the failure rates were low, and well in accordance with failure rates reported for fixed prostheses. The study revealed that extreme bone resorption and poor bone quality were the reasons for choosing an overdenture as an alternative to fixed prostheses in two thirds of the cases. Unfortunately, the limited number of patients and length of the observation period did not permit a definite assessment of the success rate in relation to different attachment systems. As a complement to the investigation results, prospective comparative studies of different attachment systems for overdentures supported by fixtures are necessary.

\* *The International Journal Maxillofacial Implants* 1988; 3:129-134.

## Forces and Moments on Implant Pillars

B. Rangert, Mech. Eng., Ph.D.  
T. Jemt, D.D.S., Ph.D.  
L. Jorneus, Mech. Eng., M.Sc.

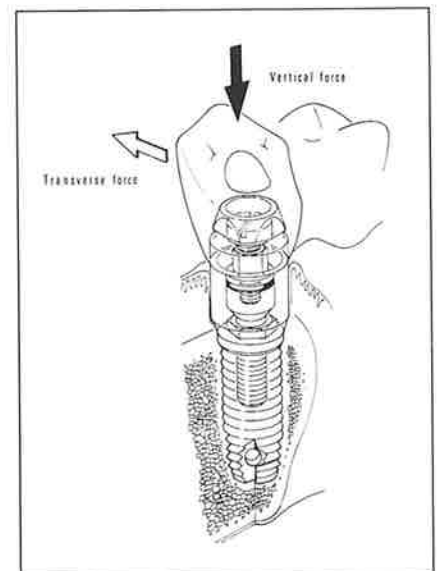
The dental implant developed by Branemark is extremely well documented as regards success rates. In order to maintain these good results when the system is used in an increased variety of clinical situations it is essential to consider the mechanical (engineering) aspects of the prosthetic bridgework.

The implant pillar consists of the fixture, the abutment and the gold cylinder, which are joined together by the abutment screw and the gold screw. This pillar has to transfer the occlusal forces into bone stresses. The design of the bridgework and the positions of the fixtures have a great influence on these stresses as well as on the stresses of the screws themselves.

In this article the fundamental mechanical parameters determining the load on the implant pillar are described. This paper concentrates on giving simple guidelines that can be used clinically, while taking the mechanical aspects of the system into account.

### Types of Load:

Mastication mainly induces vertical forces on the dentition. Transverse forces are also created due to the horizontal motion of the jaw and the inclination of the cusps.



Two main types of loading of the pillar should be considered:

- (1) Axial force
- (2) Bending moment

The axial loading is the preferred type as it distributes the stresses more evenly throughout the pillar while the bending moment exerts stress gradients both on the gold and abutment screws as well as on the bone.

### Force and Bending Moment:

$$(1) \text{ Force} \times \text{Lever Arm} = \text{Bending Moment}$$

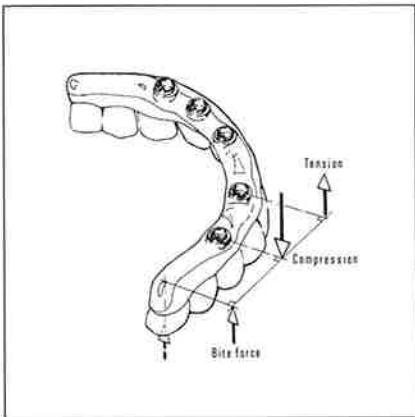
The resulting force on the pivot is the sum of the two forces acting on both sides.

To obtain an exact calculation of forces and moments on the implant pillar many mechanical parameters have to be considered. These include bridge, bone and implant rigidities. To solve such a problem a computer is needed.

Even if such a calculation should be carried out, one of the most important factors is still lacking in the analysis, namely the occlusion force itself.

The approach in this article is therefore to establish a basic approach by using the see-saw analogy so that a clinician can evaluate the fixture position and prosthetic design by simple means both prior to and during patient treatment. This simplification is conservative, which means that the real forces and moments are less than those estimated.

One design rule indicates that maximum leverage is about two times in the molar region corresponding to the clinical experience of approximately 20 mm extension in a full arch mandibular T.I.P. provided there is an inter-fixture distance in a posterior anterior direction of about 10 mm.



### Summary:

Important engineering concepts in implant prosthodontics:

1. With the use of the see-saw analogy, the loading of the implant pillar can easily be estimated.
2. If axial forces are mainly encountered, no component failures will normally occur.
3. If the loading mainly consists of bending moments, the mechanical load on the system may be excessive.
4. The placement of the fixtures is the key parameter for limiting the bending moments.
5. For well integrated fixtures, the weakest point in the system will be the gold or abutment screw, which should be regarded as a safety feature.

\* Submitted for publication.

### Chlorhexidine continued from page 1

Using chlorhexidine in each step of the process can help improve the long term success of the prosthesis, as well as make the procedure easier to perform.

The agent's clinical effectiveness against gingival inflammation is seen between the time patients agree to have crown or bridge treatment and the abutment preparation appointment. Since retraction cord placement is necessary to properly define the margins of the crown in the final impression, good tissue health is essential. Crown and bridge appointments are often set up at least two weeks in advance, which allows time to prescribe chlorhexidine to improve the gingival health of patients with inflammation and bleeding. This assistance in reducing disease prior to the crown preparation appointment reduces complications which saves time and frustration for both the patient and the clinician.

Provisional restorations can be a source of gingival irritation, which can increase the difficulty of cementing final crowns. Chlorhexidine can make the seating process easier and quicker by minimizing the plaque causing inflammation and bleeding around the provisionals. Patient use of Peridex during the time between the placement of the provisional crown and the final crown helps improve tissue health. This results in less discomfort

for the patient and a healthier and cleaner operating field. Upon procedure completion, prescribing an antimicrobial agent can help facilitate the return to optimal gingival health while the patient grows accustomed to proper plaque control methods around the new prosthesis.

Patients undergoing implant procedures can also benefit from chlorhexidine therapy. These patients can develop inflammation and plaque build up, which would increase the risk of implant failure. The formation of a biological seal is needed to seal off the endosseous part of the implant from the bacteria of the oral cavity, thus protecting the underlying bone and soft tissue. Since chlorhexidine is an excellent anti-plaque agent, regular use of the agent can help patients maintain their soft tissues while helping prevent plaque from accumulating on the titanium abutment. This regimen is especially applicable for patients who are unable or unwilling to perform adequate home care, such as those patients with poor hand-eye coordination or other disabilities.

In conclusion, oral antimicrobial agents such as chlorhexidine can provide the short term benefit to the prosthodontic practice of improving the quality of procedures, while providing the long term benefit of improved patient oral health and overall satisfaction with procedures.

### Composite Grafts continued from page 1

A review of 160 consecutive iliac crest bone grafting procedures found reduced donor site morbidity with the medial versus the lateral ilium harvesting approach, and found the bone quality, quantity and contours equal to the lateral iliac crest bone. In the immediate placement group, two of the five cases have been in function without complication for 10 months and 36 months respectively. A third patient has experienced loss of a portion of the bone graft and associated implants and is scheduled for re-operation in the near future. The fourth and fifth cases are without complication and scheduled for Stage II surgery in the near future.

The second maxillary group entitled "delayed placement" consists of five patients where interpositional iliac bone grafts were placed after LeFort I osteotomy down fracture of the residual maxilla.



Interpositional bone graft

Following 6 to 12 months of bone healing Branemark implants are placed through the residual ridge into the previously placed iliac bone grafts. Three out of five of these patients have been functioning without complication for over two years and a fourth patient is scheduled for Stage II surgery in the near future. A fifth patient has recently received her prosthesis.

Five mandibular patients were operated where iliac bone grafts and Branemark implants were placed in combination. Four of the five patients involve mandibular discontinuity which have been treated initially by blocks of iliac corticocancellous bone grafts followed in 6-9 months by Branemark implant placement. The fifth patient involves a severely atrophic mandible where simultaneous placement of an onlay bone graft and Branemark implants were placed. Three of the five patients have been in function without complication 12 months, 20 months and 36 months respectively. The remaining two patients are awaiting Stage II surgery.

In summary, 15 patients were operated where implants have been placed in combination with autogenous iliac bone grafts. In ten maxillary cases, only 10 of

Continued on page 6

**Composite Grafts** Continued from page 5

the 54 placed implants were removed. Five of the ten removed implants involved onlay type grafts with simultaneous implant placement where the implant did not extend into host bone. All of the patients where implants were removed were nonintegrated at State II surgery and all patients who lost implants are functioning well with a prosthesis on the remaining implants. Loss of the remaining five implants were in the delayed placement group and involved areas where the previously placed bone graft had undergone partial resorption prior to implant placement. The increased loss of implants in this group of grafted patients has justified the practice of placing an additional number of implants when feasible than generally placed in non-graft patients. It is important to also place implants through the bone graft into residual host bone whenever possible. To date, the author has lost all implants (5) which contacted only grafted bone.

In the five mandibular patients involving 28 implants, no implants were removed and three of the five patients have been in function 12, 20 and 36 months respectively.

In this group, the donor and recipient site surgical technique required a demanding and exacting attention to detail. Long operating time, increased graft handling and shaping, and excessive heat generation are all negative factors influencing bone graft survival. The grafted bone must be firmly fixed to the residual bone and covered with well vascularized soft tissue. The bone graft should ideally contain both cortical and medullary graft material and bone cutting must preserve vital cells in both the graft bone and residual jaw. Adequate healing time must be allowed prior to prosthetic loading, currently, 6-12 months healing time from bone grafting to implant placement (in the delayed placement group) and 6-12 months from the time the implants are placed in bone graft to uncovering and prosthetic loading. It is noted from previous clinical research in Goteborg, Sweden and this clinical study that implants which engage both the grafted and residual jaw bone appear to fare much better than the implants which engage only the grafted bone. In mandibular discontinuity cases, implant placement must be placed entirely in grafted material, which is one critical factor favoring the procedure where graft placement and implant placement are separated by a 6-12 month healing period. In contrast, onlay bone grafts for severely resorbed maxillary and mandibular ridges can be reconstructed in one step as the implant can engage both grafted and recipient site bone.

Initial results are optimistic in the belief that bone grafting and implant

placement into grafted bone if properly staged can give predictable results. The prosthetic success from the patients' viewpoint has been dramatically improved since implants have been added to the bone grafting protocol. Long term results await further study and follow up documentation.

\* Presented at the Annual Scientific Session of the Academy of Osseointegration, Dallas 1988.

.....  
"Osseointegrated" continued from page 1

radial and mandibular sites in mature dogs. Implants were left submerged in bone for 4-7 months to allow healing in the absence of direct loading. Half of the implants in each dog then were subjected to 5-7 days of cyclic axial loading, applied *in vivo* by computer controlled pneumatic devices. Axial loads (50 to 110 N) were applied at 1/2 Hz for 500 cycles/day. Fluorochrome bone labels were given pre- and post-loading. Interfacial tissues of loaded and control implants were studied via light microscopy and SEM (analysis done at approximately 3 weeks after the loading period). Histomorphometry of interfacial tissues were performed using hardware and

software developed for this purpose. Measurements were made of these descriptors of interfacial tissue morphology: % direct bone implant contact, % soft tissue in interfacial regions, and % interfacial bone having pre and post load fluorochrome.

All implants showed appreciable regions of close bone apposition to titanium without detectable interfacial soft tissue. On average, there were no statistical differences between loaded and control interfaces. Furthermore, there were no statistical differences between loaded vs. control cases in terms of the average % interfacial soft tissue and % labeled bone in the interfacial region. There was about 66 times more labeled bone at the interface compared to regions of bone a few millimeters away from the interface. In conclusion, the known biomechanical differences between loaded and control interfaces apparently were not sufficient to provoke differences in the measured descriptors on the interfaces, under the experimental conditions used in this study. Unanswered, however, is the question concerning interfacial responses to larger axial (and lateral) forces.

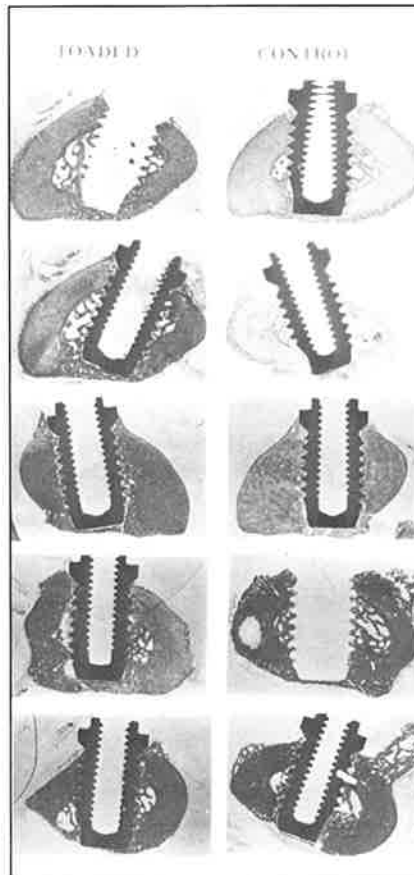
\* Presented at the Annual Scientific Session of the Academy of Osseointegration, Dallas 1988.

.....  
**Biomaterial** continued from page 1

interaction properties with respect to water and biomolecules.

The surface chemical composition and microstructure can be analyzed down to atomic level resolution by employing state-of-the-art surface analysis instrumentation and electron microscopy. Preparation methods are available that can be used in combination with the analytical techniques to tailor implant surfaces for different applications. The major obstacle towards using this potential is the lack of knowledge about how different surface properties influence the tissue response. Systematic search for correlations between implant surface properties and tissue response is therefore one of the most important tasks in current implant/biomaterials research.

\* Presented at the Annual Scientific Session of the Academy of Osseointegration, Dallas 1988.



*Representative histologic sections of the interfacial regions of loaded and control fixtures in canine radii. The sections are made from embedded, undecalcified specimens using a modified hand grinding technique.*

**3rd International  
College of Prosthodontists  
Meeting**

Toronto, Canada  
July 9-12, 1989

Information contact T. J. Balshi  
215-646-6334