



“Will Implants Work for Me?”

Thomas J. Balshi, D.D.S., F.A.C.P.

Over the years family dentists, specialists and physicians have referred patients for osseointegrated implant treatment, many of whom were well informed and had numerous excellent questions.

Some of the more frequently asked questions focus on the prime query, “Am I a candidate for dental implants?” Numerous patients tell us they have been informed in the past that implants are impossible because they have no bone, and still others are concerned about their age, general health, or that they may need to go without teeth for a period of time. Some patients repeat hearsay stories about antiquated techniques and wonder if the procedures are still the same. Beyond their questions, concerns, fears and apprehensions, they all have one common desire—“permanent teeth” and the restoration of oral function and esthetics.

The following abbreviated list highlights conditions of patients who are often excellent candidates for osseointegrated implants.

1. **Insufficient denture retention due to extreme resorption of the jaw bone(s).**
2. **Emotional inability to wear a denture, even where ridge retention is technically adequate.**
3. **Functional disturbances such as severe nausea and vomiting**

continued on page 4

Bruxism—Understand, Diagnose and Treat This Problem Early

J.C. Nel

There are two main reasons for tooth destruction namely, plaque and abnormal stress. Plaque control techniques are well known and highly effective. Bruxism is the main cause of abnormal stress in the mouth and this should be diagnosed by the dentist at a very early age. Predisposing, psychological and local factors are present in all individuals. Should the level of either the psychological stress or local interferences, or both, increase, the level of the combined stimulus could rise above the “Bruxism threshold value” leading to a start or increase in bruxing activity. By decreasing or eliminating any one of the two stimuli, the combined level will drop to below the bruxing threshold, and the patient may stop his bruxing habit.

It very seldom happens that the patient approaches the dentist with the complaint of bruxism. Normally when he does so it is because of the aesthetic appearance of the worn down teeth or the sharp enamel edges traumatizing his lips or tongue. Symptoms of the myofascial

pain dysfunction syndrome (MPDS) can often be related back to bruxism.

There are four objectives in the treatment of bruxism (Mikami, 1977):

1. *Breaking the neuromuscular habit pattern.* This can be accomplished by the wearing of a nightguard, such as the modified Hawley appliance (Nel 1980);
2. *Reducing occlusal irritations.* By eliminating the occlusal factor, the stimulus may be decreased below the “Bruxing Threshold” and the bruxing habit will be reduced/eliminated;
3. *Reducing psychic tension.* The prosthodontist must establish a relationship of trust with his patient, and assist the patient in recognizing sources of stress in his life;
4. *Treating signs and symptoms.* After all acute pains and symptoms of bruxism have been removed, lost tooth structure can be replaced by means of restorative procedures.

The early diagnosis and treatment of bruxism is of major importance. The prosthodontist should always be on the lookout for the first signs of bruxism. Any sign of attrition, especially in the young individual, needs further investigation.

* Presented at ICP Interlaken, Switzerland, 9/87.

Cast Framework for Branemark Implants

Graham White

The casting of required frameworks that are clinically unbreakable and have a passive connection to their supporting implants is a vexed problem. The literature insists that the insertion of misfitting prostheses is a certain precursor to micro-cracking and resorption of the host bone and possible fracture of implant parts.

The Nobelpharma Instruction Manual suggests several methods of framework manufacture including its casting in pieces, reassembly in the mouth and investment soldering. This is both laborious and expensive. No alloys or other materials are recommended.

Research in the University of Sheffield Dental School, England has developed a system for producing cast lightweight

single-piece gold alloy beams of great strength which fit without soldering. Conventional dental technology is used.

The Sheffield definition of passive fit is that obtained when only *one* gold retaining screw is placed alternatively in each of the most distal fixtures. Under these circumstances the casting must perfectly fit all fixtures, both on the cast and in the mouth with only one fixing screw.

The fatigue strength of the casting was determined by repeatedly loading the ends of the cantilevers with a stress equal to that maximally exerted between upper and lower natural teeth. The cantilevers *WITHSTOOD OVER TEN MILLION STRESSES WITHOUT DETERIORATION*. When the cantilevers were subjected to an increasing static load stress, the casting withstood a maximum load 21 times maximum biting force.

* Presented at the Academy of Osseointegration, Dallas, 1989.

3rd Meeting of the ICP, Toronto

Development of a Two-Piece Artificial Resin Tooth Specially Designed for a Metal Occlusal Surface

Y. Tanaka and K. Hiranuma

The clinical selection of artificial teeth depends on the characteristics of each case because each case requires different function, durability and characteristics in manipulation. The porcelain or resin tooth is generally the first choice but there are problems: Porcelain teeth are brittle, and resin teeth are rapidly worn out under oral functions. It is well known that changes in the occlusal surfaces will cause poor chewing efficiency and trouble in the intermaxillary relationship.

A newly designed two piece resin tooth has been developed for upper and lower molars and premolars. Each tooth consists of two parts, an occlusal portion and a base portion. A 45 μm nylon sheet is sandwiched between them as a separator. The occlusal portion is connected to the base with thin horizontal belts bulged at the buccal and lingual side margins. Instead of using an adhesive, the belts are made of the same material as the parent portions of the teeth.

At the manufacturer, the occlusal portion is press-formed in a metal mold first, and before the resin sets completely, continued on page 4

Osteoporosis and Osseointegrated Implants

C. Baxter

Osteoporosis, a lack of bone density, occurs in almost 1/3 of Caucasian women by 60 years of age and more than 1/2 by the age of 75. A patient with a bone density loss of over 30% of normal is at risk for bone fracture. Type I osteoporosis characteristically effects women 5 to 15 years after menopause. Type II osteoporosis is directly related to hormonal fluctuations, so it may also be seen in younger women with surgical hysterectomies, endometriosis, or anorexia-bulimia. Hip fractures are the main result of this form of the disease. Calcium deficiency is a contributing factor to all types of osteoporosis.

Actual diagnosis using dual photon absorptiometry tests (DPA) is non-invasive, low cost and emits a minimal radiation dose. Suspect patients should be referred to an endocrinologist. Treatment can include, estrogen therapy, calcium supplements, exercise and fluoride treatment.

Treatment with osseointegrated fixtures is not contraindicated in osteoporotic patients and *in fact may be of great benefit* to the patient for future bone maintenance.

continued on page 4

Prosthetic Rehabilitation of the Head and Neck Cancer Patient

Gerald J. O'Keefe, et al.

Maxillofacial prosthetic rehabilitation has become an essential part of the treatment of head and neck cancer patients because of the functional and cosmetic defects that can result from the surgical procedures required to eradicate the disease. In some cases, plastic and reconstructive surgery can rehabilitate these people, but in others, a prosthesis is the only solution. Patients with gross facial disfigurement require physical and psychological support. The prosthodontist, by restoring missing body parts, provides this much needed mental therapy as well.

The restoration of facial aesthetics is paramount in the total rehabilitation of a patient with noticeable defects. By replacing missing parts, such as an eye, ear, nose, chin, etc., the patient can achieve a degree of normalcy and a will to get back into society. Depression can be a serious drawback to a patient's recovery. Being able to look whole is a very uplifting experience. Restorations that restore or improve communicative ability and speech, chewing, and swallowing enable these individuals to function as close to their former selves as possible. The primary objective in each treatment is to construct a prosthesis that restores the defect, improves appearance, and changes the patient's morale. Restoring normal appearance and function can give the patient the hope and desire necessary to lead a productive life.

* Presented at ICP, Toronto, July 1989.

Alternative Denture-Base Polymers

R. Mac Gregor

In spite of the undoubted and excellent properties of standard heat-cured polymethylmethacrylate as a denture base material there is occasionally a need for a different polymer, either because of limitations in the mechanical properties of PMMA or because of the possibility of a hypersensitivity or allergy to one or other of its components. Three such materials were investigated: Pus-h; Flexiplast; and Makrolon 2808. These are injection moulded by a Protomat machine at temperatures appropriate to the particular material (the temperature ranges from 245 to 335°C) at an air pressure of 150 psi. These materials (in the form of granules) are contained in aluminum cartridges, inserted into the chamber, electrically softened and injected into the warm dental flask. The mould is fed by a single

continued on page 5

Initial Interface Structure of a New Ceramic Zirconia Endosseous Implant Under Two Different Occlusal Loading Conditions

Yasumasa Akagawa, et al.

The purpose of this study is to evaluate the initial interface structure of a new ceramic zirconia endosseous implant under occlusal loading and non-occlusal loading conditions. Four beagle dogs were edentulated at the right premolar region. After 12 weeks, three screw shaped, 4mm in diameter, 18 mm in length, zirconia ceramic implants (Goe Manufacture Co. Ltd., Japan) were inserted into the edentulous area by a one stage procedure.

The animals were divided into two groups: (1) implants free standing, without a superstructure, under no occlusal load, with a powdered diet for 3 months; (2) implants with superstructure placed immediately postinsertion, with immediate occlusal loading with a hard dry pellet diet for 3 months. Plaque control was performed in both groups 5 days a week.

After 3 months of implant insertion, the implant and surrounding tissue were excised from the jaw and prepared for light microscopic examination. Direct bone implant interface was generally observed in both groups. Marginal bone loss continued on page 4

Esthetic Evaluation of All Ceramic Crowns

A.P. Tripodakis and A. Grous

The ultimate goal of dental esthetics in restorative dentistry should be the reproduction of reality and beauty of natural teeth. What lies within the restorative possibilities today is to produce restorations that aim to be in context and harmony with the surrounding environment of the oral cavity. A major factor is to establish a depth of translucency that is compatible to natural teeth, especially in the cervical third.

In all ceramic restorations the absence of a metal framework offers increased possibilities for improved esthetic results. Different systems of fabrication of these restorations present various esthetic advantages and at present can be classified as: (1) All ceramic crowns that involve the construction of high strength core on a refractory die (i.e. Hi-Ceram) and a porcelain built up on top of it; (2) Castable ceramic restorations (i.e. Dicor) that present a uniform high translucency optical behavior; (3) Crowns that involve the application of a porcelain build up (Vitadur-N) on a cast glass core (Dicor)

continued on page 5

The Willi's Glas Crown

John N. Nasedkin

Willi Geller has developed a technique for full crowns using a Dicor cast ceramic substrate and an overlay of Vidur N porcelain. This approach overcomes the grey hue commonly associated with the superficially shaded Dicor restorations and also allows for light transmission through the crown to the root and tissues, thereby preventing the dark or blue ring associated with PFM crowns.

High strength foundations like Shofu GlasIonomer base of posterior composite restorative are needed. Adequate tooth reduction is required to 1.75 mm or greater on the occlusal and 1.25 mm on the proximal surfaces.

While these crowns may be cemented with any luting agent, resin cementation is preferred. The advent of the Mirage dentin/enamel bonding system allows for simplified pretreatment with a thin adhesive layer. Unfilled resin is used to coat the tooth prior to insertion of the crown filled with a dual-cure resin. Custom tinting and staining allow for both hue and value alterations, making it possible to match both adjacent teeth and restorations. Willi's crowns have become the crown of choice for experienced dentists with very low failure rates. Dentsply will market their own version of this crown system in late 1989.

* Presented to the June 1989 Pacific Coast Society of Prosthodontics Mtg., Silverado, CA.

Bone Formation Rate in Osseointegrated Titanium Implants

Kalebo; Buch; Albrektsson

The influence of local application of haemostasis peripheral blood, autologous bone marrow and Fibrin Adhesive System (FAS) on bone formation rate in osseointegrated titanium implants, were studied. The Bone Harvest Chamber (BHC) implant utilized a penetrating canal which enabled osseous ingrowth in situ. After integration of one implant into the cortex of the proximal tibial metaphysis of a rabbit, newly formed bone was harvested in repetitive three week periods. The specimens were quantified by microradiography-videodensitometry and subjected to further histological examination. The amounts of bone formed in two equally treated chambers in the same animal were compared. It was concluded that the conditions for bone regeneration in an osseointegrated titanium implant are excellent, minimally influenced by locally applied haemostasis, peripheral blood and autologous bone marrow. FAS pretreatment, on the other hand, was found to impair bone formation.

* Scan J Plastic Reconstr Surg 22: 53-60, 1988.

Microbiota Associated with Periimplant Health and Disease

Flemmig; et al.

The clinical status of dental implants is generally categorized as successful or failed. There are, however, intermediary stages between implant success and failure, the compromised success and the failing implant. *Compromised* successful implants are characterized by soft tissue alterations such as "gingivitis," gingival hyperplasia, and fistula. *Failing* implants demonstrate progressing bone loss, but enough bone anchorage to serve its function. *Failed* implants, on the other hand, have lost all their bony support and their function and are considered to have a hopeless prognosis.

In natural teeth the microflora in periodontal health is different from periodontal disease and varies among the different disease forms. Specific microorganisms are associated with specific periodontal disease entities. Similarly in periimplant complications, elevated levels of

specific periodontopathic microorganisms are found. Test results demonstrate that in different forms of periimplant complications, specific periodontopathic microorganisms can be found in elevated levels.

The analogy to the periodontal disease of natural teeth suggests that the same principles for prevention and treatment of natural periodontal disease can be applied successfully in endosseous implants. Three months maintenance of implant patients prevented the colonization of bacteria that are associated with periimplant complications. Hence, a regular maintenance may reduce the incidence of periimplant complications and prolong implant longevity. There is clinical evidence that soft tissue alterations are amenable to treatment directed against the bacterial plaque. Current knowledge suggests that treatment and prevention of periimplant complications has to be primarily aimed towards plaque control and reduction of mechanical stress.

* Presented at the Academy of Osseointegration, Dallas, 1989.

Bioactive Coatings

J.F. Kay

Over the last few years, an exciting materials concept has been applied to the clinical practice of oral implantology, or hydroxyapatite coating of metallic implants. The rationale for the use of an HA coating is based on observations of direct biochemical bonding between bone and the hydroxyapatite surface. This is a result of the chemical similarity between synthetic HA and the natural bone mineral phase which has the following advantages: faster bony adaptation; absence of fibrous tissue seams; firmer implant-bone attachment; reduced healing time; increased tolerance of surgical inaccuracies; and inhibition of ion release. An additional and most important advantage *may be* the potential for increased long term implant success.

The clinical experience of HA coated endosseous cylindrical implants approaches four years. Short term positive features have been realized. The history of HA coating on blade type dental implants is short, and unavailable, primarily due to the difficulties involved with blade implant practice and the nature of the HA coated metal system.

Currently available coatings and those that will soon be available are not cure alls. They cannot salvage existing inferior designs, nor should all current metallic implant designs be coated. The coatings should not be used to compensate for gross inaccuracies in initial fit, nor to foster nonprecision installations in the hands of inexperienced practitioners. The biological coatings available today represent an incremental increase from yesterday's

metals technology and an interim step towards more tailorable, biologically active systems. We must proceed cautiously, especially when utilizing the currently available systems, as they may be susceptible to inconsistency, damage or misuse. Proper education in the history, background, and limitations of bioactive coatings will allow them to be used effectively and promote their use into the 1990's.

* Presented at the Academy of Osseointegration, Dallas, 1989.

PROSTHODONTIC
Insights

is published by Prosthodontics Intermedica and distributed without charge to qualified individuals. Please request a subscription on your organization's letterhead.



Fixed, Removable,
and Implant Prosthodontics

Prosthodontics Intermedica
467 Pennsylvania Avenue
Fort Washington, PA 19034 U.S.A.
Telephone: 215-646-6334

Structural Failure of Osseointegrated Implants at the Time of Restoration: A Clinical Report

J.A. Lewandowski and C.M. Johnson

This report describes a 62 year old Caucasian woman with a squamous cell carcinoma of the anterior floor of the mouth and the anterior mandible. At the time of the surgical resection in September 1985, a right deltopectoral flap was elevated and placed to fill the soft tissue defect. After appropriate healing, 5880 rad of radiation therapy were given to the head and neck. The surgery resulted in a discontinuity defect of the mandible extending from the right mental foramen to the left mental foramen. Because of the discontinuity defect there was greater difficulty in taking food by mouth, and a feeding gastrostomy tube was placed in April of 1986. By August of 1986 hyperbaric oxygen treatment had been completed.

The mandibular defect was reconstructed in September of 1986 by using a

titanium tray filled with particulate cancellous bone from the iliac crest. Upon completion of postsurgical care the patient was referred to the Maxillofacial Prosthodontic Service for restoration in January 1987. Since the bone graft matured and remained stable, 4 osseointegrated implants were placed in March 1987. In June of 1987 the implants were uncovered and impressions were made for fabrication of a fixed cast prosthesis base. When placement of the implant abutment heads was attempted the two midline implants were mobile and spontaneously separated from the bone.

When closely examined, it appeared that the hydroxyapatite had separated from the implant metal base. Impressions were then made for both a maxillary denture and a mandibular cast prosthesis base by using two remaining implants. This construction was used for one year (June 1988) when the recurrent tumor was found.

* Journal of Prosthetic Dentistry V62, No. 1.

Initial Interface

cont. from page 2

was, however, predominant and slight inflammation was seen in the group of implants under occlusal loading. These results suggest that this zirconia implant is compatible to the bone tissue and that initial exclusion of occlusal loading might be preferable to achieve direct implant interface with minimum marginal bone loss.

Presented at ICP, Toronto, July 1989.

Osteoporosis

cont. from page 2

Osseointegration can be achieved with the same success rate in osteoporosis patients if cautious techniques are utilized. These techniques include leaving an increased time span after removal of teeth, leaving increased time between fixture installation and abutment connection surgery, using extra caution when tightening abutment connectors, as well as loading the case gradually over a period of time.

"Will Implants Work?"

Cont. from page 1

reflexes that are caused by removable dentures.

4. Loss of posterior teeth requiring removable partial dentures.
5. Periodontally loose teeth, about to be lost.
6. Congenitally missing teeth.
7. Loss of single or several teeth.
8. Accidental or traumatic loss of teeth.
9. Loss of teeth and/or jaw bone due to cancer treatment.

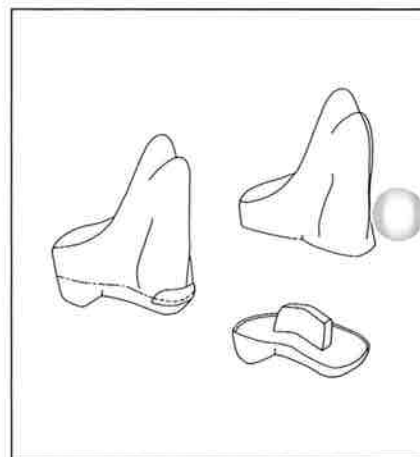
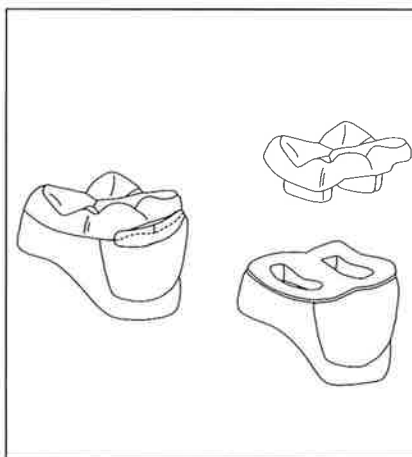
Addressing other questions concerning general health, there are very few medical contraindications to osseointegrated implants. Each patient, however, must have a comprehensive review of their medical history and should have a recent physical, especially if they are subjected to chronic systematic ailments.

Lastly, the age of the patient does not inhibit implant treatment. Our experience with patients from 9 to 90 has produced positive and rewarding results . . . admittedly, the last statistical analysis of our patients indicates that over 60% of the patients are in the age range from 60 to 80 with from 40 to 59 being the next largest group.

In all instances, successful osseointegration requires a careful diagnosis, a comprehensive treatment plan and the cooperative effort of a highly experienced and trained team of doctors, nurses, assistants, hygienists and dental technicians. The remarkable success of the Branemark method of osseointegrated implants is attested to by the planned testimonial scheduled for June to celebrate the 25th year of continued clinical success of osseointegrated implants.

Artificial Resin Tooth

Cont. from page 2



Schematic of the two-piece resin teeth

the base portion is injected onto it with a separating sheet. Since the sheet avoids the connecting belt portions, the resin continues from the occlusal portion to the base through the belts, creating a small and thin, yet strong connection. The two portions can be easily separated by removing the connecting belts, as the schematic illustrates. The sprues are fixed directly on the separated occlusal portions to be invested as the resin patterns for casting to metal.

The first molars and the lower second molars have two projections and the other teeth have only one projection each. They play an important role in resetting the cast portion onto the base. These teeth can be arranged on the wax base. Then the denture can be processed for occlusal adjustment on an articulator. The doctor sets the finished dentures in the patient's mouth and asks him to use them for a

couple of weeks, making routine occlusal and base adjustments.

After clinical use, functional occlusal facets are reproduced in the metal casting. Dental alloys such as platinum gold or palladium gold may be used. The polished metal occlusal portions are set on the base portion with dental adhesive. The metal can be precisely seated on the base by retention projections and orienting shelves made on the shoulder around the base portions. These new teeth are applicable to either a full denture or a removable partial denture except in certain cases requiring extensive occlusal adjustment of the teeth. From the results of basic experiments and clinical trials, they have proven to possess enough strength, stability and also good dimensional accuracy.

* Presented at ICP, Toronto, July 1989

**Osseointegration:
Advanced Surgical and
Prosthetic Considerations**

**Snowbird Ski & Summer Resort
Snowbird, Utah**

Date: February 24-27, 1990

Location: Snowbird Ski & Summer
Resort
Snowbird, Utah

Faculty: Thomas J. Balshi, D.D.S.,
F.A.C.P.
Prosthodontics
Intermedica/IFFE
Fort Washington, PA

Robert A. Jaffin, D.M.D.
New York, NY

Graham E. White, M.Med,
Sci., Ph.D., CGI
Sheffield, England

Major

Topics: Single Tooth

Maxilla & Posterior
Mandible

Esthetics

Surgical Aspects

Special Oral Hygiene
Procedures

For: Doctors, Technicians,
Hygienists, Assistants

For Info: Call IFFE 215-643-5881

**Historic, Current and Future of
Maxillofacial Prosthodontics**

Patrick J. Henry

Historically, maxillofacial prostheses have relied on principles of mechanical attachment and subsequently the use of adhesive systems to provide retention for facial prostheses. With the advent of direct prosthetic anchorage to underlying bone as provided by the extra oral placement of osseointegrated fixtures, patients can now be rehabilitated to a level hitherto not considered possible and many such individuals enjoy greatly improved lifestyles. However, long-term success is dependent on an intimate understanding of the variables involved and a total commitment to the multidisciplinary teamwork philosophy of treatment.

In cases where surgical reconstruction is not possible and where conventional maxillofacial prosthetic rehabilitation is counterproductive, the decision can be taken to consider tissue integrated prostheses (T.I.P.). The etiology of craniofacial defects falls into three groups: congenital absence, traumatic loss, and surgical removal.

Because the ramifications at the assessment, diagnostic and actual treatment stages may be many and varied, it is mandatory that case management is properly controlled. The maxillofacial prosthodontist is probably the person of choice to coordinate treatment because of the life-long responsibility for maintenance that is inherent to this type of therapy. Various oncological personnel, social

Various oncological personnel, social workers, audiologists, psychologists or psychiatrists that have been or should have been involved with the case may be invited to participate in the team approach to rehabilitation. The T.I.P. team has the responsibility to adequately inform all patients, irrespective of status as to what the long-term possibilities of rehabilitation actually are. In some cases the knowledge of possible things to come can do much to encourage patient motivation and boost morale under circumstances that are at the very best psychologically devastating.

The summarized surgical approach to the case will be presented by the maxillofacial prosthodontist. On completion of the treatment plan presentation and discussion the patient will be furnished with an informed consent document to be signed and witnessed prior to scheduling of the case. The treatment planning flow chart coordinates the technicalities of the surgical prosthetic interrelationship and offers a disciplined approach aimed at minimizing the number of complications which inadvertently occur despite the most careful planning.

Radiographic analysis of the bone bed prior to surgery is mandatory to ensure that there is no reason to exclude the patient from treatment. Computerized tomography can be a valuable diagnostic tool in assessing bone volume and morphology. Another criteria of case selection is the cause of the defect. The etiology of the defect is often reflected in the difficulties encountered during case management.

The maintenance of anchorage function in dental implants is controlled by

continued on page 6

Esthetic Evaluation

cont. from page 2

as improvised by Willi Geller (Willi's Glas Crown).

The esthetic evaluation of these systems was related to the measurement of the % transmittance values. Samples of 1.5 mm thickness of Hi-Ceram, Vitadur-N, Dicor & Vitadur-N (with and without glaze) and plain Dicor (with and without shading porcelain) were evaluated with a single beam spectrometer. Hi-Ceram samples were found to be rather opaque (transmittance 3.0%, opacity 99.5). Dicor presented increased translucency (transmittance 24.5%, opacity 84) that was slightly reduced after shading porcelain was applied (transmittance 14.5%, opacity 91.5).

In order to project these findings on the clinical level esthetic comparisons (Ceramometal vs. HiCeram; Hi-Ceram vs. Dicor; Dicor vs. Willi's Glas; and Hi-Ceram vs. Willi's Glas) were made intra-orally between anterior crowns (incisors) and comparable natural teeth. In conclusion, the state of the art in all ceramic restorations was presented by the Willi's crown. It produced adequate depth translucency cervically, and provided adequate masking of the underlying tooth when cemented with an opacous cement

(if required). Moreover the internal optical structure of natural teeth incisally can adequately be reproduced within the porcelain build up.

* Presented at ICP, Toronto, July 1989.

Denture-Base Polymers

cont. from page 2

ingate sprue with an air escape on the opposite side.

Laboratory methods still need to be perfected with these three materials. The Pus-h acrylic is satisfactory; the Flexiplast nylon can occasionally produce dimensional errors and sometimes internal voids; the Makrolon polycarbonate produces problems with breakage of porcelain denture teeth, probably due to the high injection temperature. The possible cytotoxic effects of all these materials, while probably nonexistent, will be investigated partly with an animal model and partly with an in vitro cell culture technique which can be a very sensitive parameter of cytotoxicity.

* Presented at ICP, Toronto, July 1989.

**Educational Opportunities
Sponsored By The Institute
For Facial Esthetics—
Pennsylvania's Official
Branemark Training Center**

**Prosthetic Training Program
For The Branemark Method
Of Osseointegration**

**Advanced Osseointegration/
Ski Course:**

Feb. 24-27, 1990
Snowbird, Utah

**Two Day Course, Includes
Hands-on Instruction:**

Apr. 27-28, 1990
Plymouth Meeting, PA
July 27-28, 1990
Plymouth Meeting, PA
Nov. 16-17, 1990
Plymouth Meeting, PA

All courses are AGD accredited.
For more information call:
215-643-5881

long lasting osseointegration and the preservation of marginal bone height. The assessment of adequate anchorage function is essentially an empirical one whereby clinical practice is based on formulae which have stood the test of time. The status of osseointegration is determined intraorally by clinical and radiographic assessment. Strict radiographic criteria of success have been established for the assessment of intraoral fixtures.

Assessment of soft tissue health is made using the criteria for cardinal signs of inflammation, namely oedema, color change, soreness and suppuration. It is imperative that the skin abutment junction be in tissue thinned as much as possible and with little capability of mobility. Attempts to correlate clinical signs of inflammation and complication to specific types of microorganism have not proven successful in our laboratory at this point in time.

Although craniofacial implants inserted into irradiated beds show an increased failure rate, previous irradiation is not necessarily a contraindication for implant insertion, particularly if a one year delay after the radiating exposure is recommended before insertion of an osseointegrated implant.

While titanium appears to be an inert material with excellent biological properties, some inflammation related to mechanical irritation at the skin abutment interface cannot be avoided. The significance of such low grade chronic inflammation

over periods in excess of thirty or forty years is yet to be determined. Because sensitivity to titanium has yet to be reported, it would appear that the use of skin penetrating titanium implants is a well tolerated and safe procedure.

Two types of retentive systems are used to connect the prosthesis to the bone anchorage unit. They are mechanical or magnetic, used either separately or in combination. The degree of retention for the prosthesis will determine what type of retentive system is required. Much individual empirical preference, based on cynical judgment and experience is employed with respect to retention prescription for the craniofacial prosthesis.

While many implants systems may have a potential application in the craniofacial area, only the Branemark system has been in service for ten years with long-term follow up results. Before purchasing or using any implant system it is vitally important to demand to see satisfactory evidence of research, including animal studies, and a significant clinical trial that has been published in reputable journals and relates specifically to the implant being promoted. In the absence of such evidence, the implant must be considered to be experimental and should only be used on the basis of "human experimentation with fully informed consent."

* The American Academy of Crown and Bridge Prosthodontics 38th Annual Meeting, February 1989.

Integration of Titanium Implants in Irradiated Bone: Histologic and Clinical Study

Mangus Jacobsson, et al.

A combination of radiotherapy and surgery is the treatment of choice for malignant tumors of the maxillofacial region and the ear. Since 1979, 61 patients have had fixtures installed in the maxillo-temporal area at the University of Goteborg, Sweden. Of these patients, nine had undergone irradiation treatment prior to fixture installation. The time span between irradiation and insertion of the titanium fixture ranged from 9 months to 37 years.

Preoperatively, the head and neck surgeon, the prosthodontist, and the prosthodontic technician conferred to determine the best site and the best direction of the retention elements. A surgical technique to ensure minimal tissue trauma was used. The number of implants varied according to the demands of the host site, but in most cases three to five fixtures were used. The bone surface was exposed, the hole was gently threaded with a titanium tap, a titanium implant was inserted, the periosteum was sutured over the implant and the skin was closed. A minimum of 9 months was allowed before the second stage was performed. At that time subcutaneous

tissue reduction was performed, a hole was punched over each implant through the skin and a skin-penetrating abutment was applied and kept in place by an internal screw. Three to four weeks after the second stage the prosthodontists and the technicians started their work on the prosthesis. The aim of this effort was to supply the patient with a stable facial prosthesis.

A total of 35 fixtures were inserted. Twenty-nine of the fixtures were stable in the bone after an average follow-up time of 25 months. There have been no signs of adverse tissue reactions in these patients. No macroscopic signs of infection were observed in the bone tissue adjacent to any of the titanium fixtures. Thus, no implants had to be removed for reasons of soft tissue infection or osteomyelitis.

This study shows that titanium implants may become integrated in bone tissue and that titanium abutments may penetrate the skin in patients who have undergone previous radiotherapy at high dose levels. In the samples investigated with histology of intact tissue-to-metal specimens, it was demonstrated that a direct bone contact was achieved with out any interposed soft tissue coats.

* Ann Otol Rhinol Laryngol 07:1988, Gothenburg, Sweden.

Clinical and Microbial Evaluation of Treatment Regimens to Reduce Denture Stomatitis

L.G. Depaola, et al.

This 28 day study evaluated the effect of Listerine Antiseptic (L), and Placebo (C) rinses/denture soaks or tissue conditioning relines (R) on palatal inflammation and microbial flora of 78 patients with denture stomatitis (DS). Hour long denture soaks and 3 daily oral rinses of 20 ml for 30 sec were performed by L and C; while R maxillary dentures were relined (Coe-Comfort) every 7 days. During the study period no other denture hygiene techniques were employed. Prior to, and after the 28 days and at each reline palatal inflammation, denture stability and denture plaque were scored. Denture plaque, palatal mucosa swabs, and saliva samples were also taken and cultured on both selective and non-selective media. The microbial data were recorded as the ratio of the # of colonies recovered on selective media converted to a percent. The mean severity of DS was significantly less in both the L (p < .01) and R (p < .05) as compared to C. Analysis of variance revealed significant differences in ranked adjusted percentage counts in 2/13 organisms investigated, *F. nucleatum* (p < .05) and total Bacteroides (p < .05). Yeast populations were reduced but not significantly. L and R were equally effective in reducing DS and denture plaque flora. Bacterial pathogens may play a significant role in the development of DS. Supported by Warner-Lambert Study 931-378.

* Presented at ICP Toronto, 1989.

Mandibular Bone Resorption in Patients Treated with Tissue Integrated Prostheses and in Complete Denture Wearers

L. Sennerby, et al.

The mandibular bone resorption of patients who had received tissue integrated prostheses (TIP) following short (x = 2.4 years) and long (x = 23.9 years) periods of edentulism were compared with the resorption previously reported in complete denture patients. Bone height measurements were made from standardized cephalometric radiographs, while area measurements were made using a digitized video image analyzed by a computer. The patients were followed for 5 to 13 years. The results of the comparison suggest that treatment with TIP may reduce mandibular bone resorption in the areas adjacent to the most distal fixture. The results also suggest that a functional difference between basal and alveolar bone may be present and account for some of the differences in resorption (Gerrow).

* The International J of Oral & Maxillo Imp. V4, #1, 1989.