



Advanced Periodontitis Treated With Osseointegrated Implants

Thomas J. Balshi, D.D.S., F.A.C.P.

In presenting the concept of complex implant prosthodontic restorations, the transition of patients suffering from advanced periodontitis and oral debilitation presents a challenging environment for creating a rehabilitation treatment plan. If one adds to this process the patient demands of avoiding a complete removable denture at all cost, the treatment becomes even more complex. The following example of a patient history fits neatly into the category of the Class III modification of the Brånemark method of osseointegration (published in February 1988 in the *International Journal of Periodontics and Restorative Dentistry, Quintessence Int.*) where periodontally hopeless teeth are maintained during the osseointegration process.

The patient's notable history begins in 1983 when she was initially diagnosed with advanced periodontal disease and underwent a series of periodontal therapies. Archival radiographs from October 1983 (figure 1) clearly demonstrate the advanced periodontal disease associated with the remaining maxillary dentition. Over the next half decade she continued to experience diminished periodontal support. When the patient was first referred to our center in May of 1986, she presented with a hopeless condition in the

continued on page 2

Etiology and Therapy of the Burning Mouth Syndrome

I - V Wagner

Burning mouth syndrome has multi-causal origins and is therefore not easily treatable. Identifiable signs of burning mouth syndrome are oral dysesthesia and dry mouth, with no disorder of the oral mucosa. Medical and/or psychological disorders are not etiological factors but may reinforce the patients pain. Parafunctions such as bruxing, desolate dentition, and myoarthropathias, periodontal disease, corrosive reactions of restorative materials and a plicated tongue are intraoral causes of burning mouth syndrome.

In order to learn more about the etiology of the syndrome, the quantity of both resting and stimulated saliva secretion was compared to control subjects with burning mouth syndrome. Results show that the secretion of resting saliva is

significantly lower for patients with burning mouth syndrome as compared to defined control subjects. This accounts for the mouth dryness of which patients complain. Stimulated saliva was about 1/3 greater as compared to the control subjects. Tests also revealed that burning mouth patients have a significantly lower sensitivity threshold of the oral mucosa as well as a significantly reduced capacity for oral stereognosis when compared to control subjects.

Greater secretion of stimulated saliva, a lower sensitivity threshold, and reduced capacity for oral stereognosis can be understood as a special psychophysiological disposition. This kind of disorder does not represent a psychological disease.

continued on page 5

Framework design for bone-anchored fixed prosthesis

S.N. White & S.G. Lewis

Fixed implant supported restorations for edentulous patients provide excellent function but can often be difficult to maintain. Complications can be avoided provided certain design principles are followed. One common complication is the patients inability to maintain oral hygiene. Framework design is important, enabling the patient to maintain optimal longevity, comfort and oral hygiene while complimenting and enhancing the structural integrity of the prosthesis.

With the Brånemark System, the bottom part of the 4mm gold cylinder is taller than that of the 3mm gold cylinder, it is easier to keep wax away from the lower 2mm of the 4mm gold cylinders when waxing the framework. Should

wax be placed near the base of the cylinders, the metal may flow to the base of the undersurface of the gold cylinders at the time of casting. This unwanted metal is almost impossible to remove and will prevent the gold cylinders from correctly seating on the abutment cylinders.

The surface of the framework over the tissue on the crest of the ridge should be as narrow as possible, especially between the gold cylinders. This tissue surface facing the ridge should be convex in a facial-lingual dimension and should be concave in a mesiodistal direction. The surface facing the ridge should always be made of highly polished metal (preferably a gold alloy*), not acrylic resin.

Continued on page 5

maxillary arch. The four remaining maxillary anterior teeth and the two remaining maxillary molars all had advanced mobility. The patient was wearing an acrylic temporary restoration which had fractured on multiple occasions over the previous three years. The patient's chief request at that time was to provide her with a maxillary implant prosthesis without using an interim complete removable denture. A treatment plan was developed in cooperation with a surgery team. The remaining periodontally hopeless maxillary teeth were reprepared in January of 1987 and a high impact acrylic provisional restoration was delivered extending from tooth #2 through and including #14.

After much procrastination, in June of that same year the patient finally scheduled an appointment for fixture (implant) placement with a surgeon, unfortunately without the benefit of a guidestint nor in concert with the prosthodontic treatment plan. Four Brånemark implants were placed in the maxillary anterior (figure 3). Following the surgery the fixed provisional restoration required readaptation.

Six months later the second stage surgery was performed to uncover the four anterior fixtures. The oral surgeon noted that one fixture rotated slightly when the abutment was applied however he made the decision to maintain that fixture until the remaining teeth were extracted and additional fixtures could be placed. A conversion prosthesis was made following that abutment connection visit. The patient wore the conversion prosthesis (figure 4) supported by the four fixtures until September of the following year (1988). At that time five additional fixtures were added between the existing fixtures, two 7mm fixtures in the molar region on the right and left sides, and three 10mm fixtures in the anterior. The most posterior fixture on the left side, which was initially loose at the time of its uncovering, was removed.

Nine months later, in June of 1989, the second stage surgery was performed to uncover the remaining fixtures. A new conversion prosthesis was adapted and the failed fixture (the most distal fixture on the right side) was removed. A porcelain fused to gold fixed prosthesis was constructed, without the use of distal cantilevers, extending posteriorly from the 7mm fixtures (figure 5 a & b).

Approximately 1 1/2 years later (November 1990) the patient was reevaluated. Both 7mm fixtures had lost osseointegration and demonstrated a fibrous encapsulation.

continued on page 3

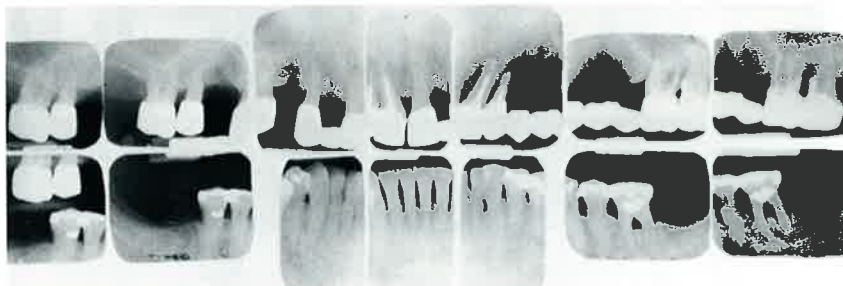


Figure 1: 1983 periapical radiographs demonstrate periapical abscesses and advanced periodontal disease.

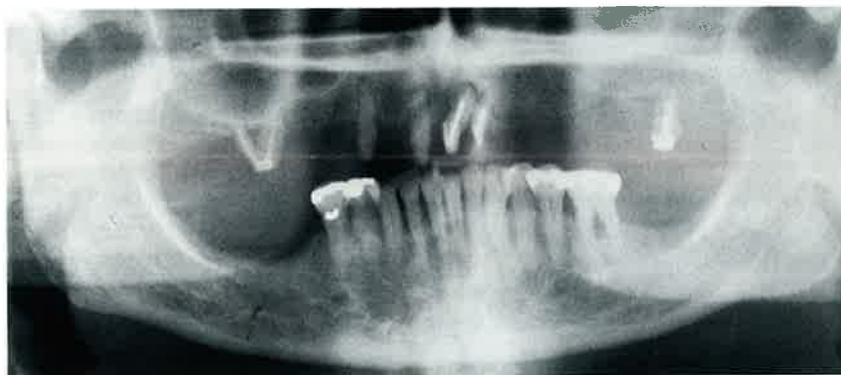


Figure 2: Panoradiograph illustrates 5 maxillary periodontally hopeless teeth prior to implant prosthodontic reconstruction.

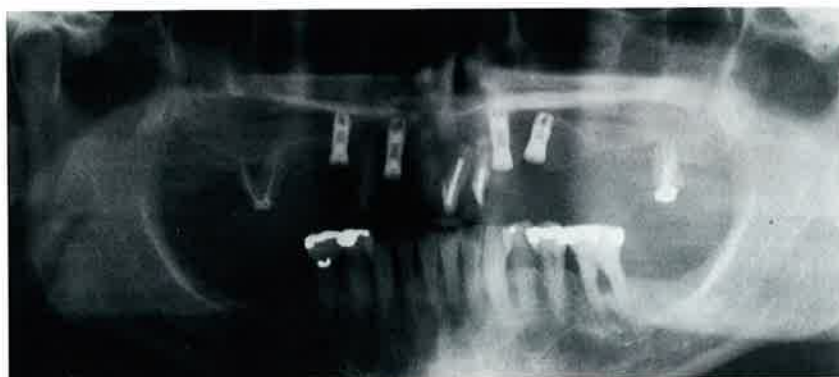

Figure 3: Placement of four Brånemark titanium fixtures in the maxillary anterior. Note the available bone distal to the maxillary right terminal abutment.

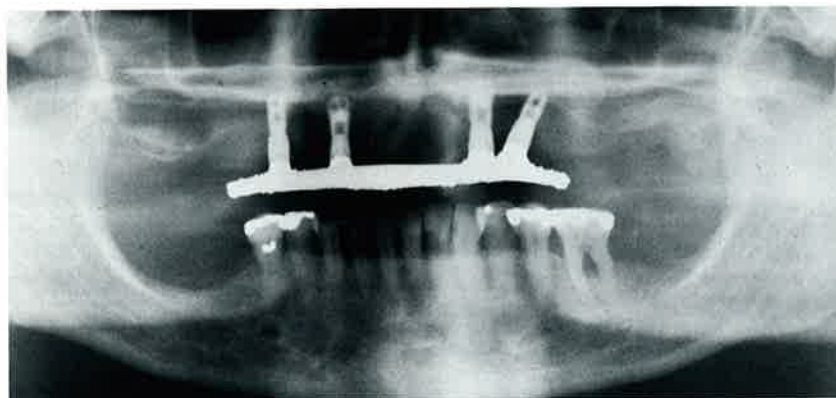


Figure 4: A custom cast gold bar with passive fit supports a temporary (conversion prosthesis) restoration to be used during the healing period of the extraction sites.

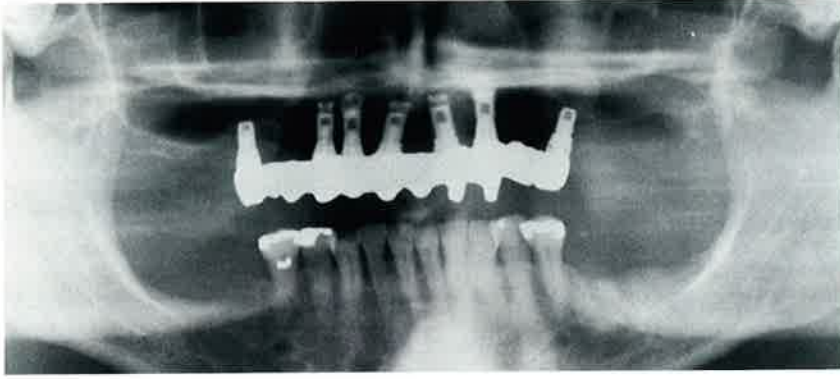


Figure 5a: The panradiograph shows the porcelain fused to gold tissue integrated prosthesis supported by 7 maxillary fixtures.

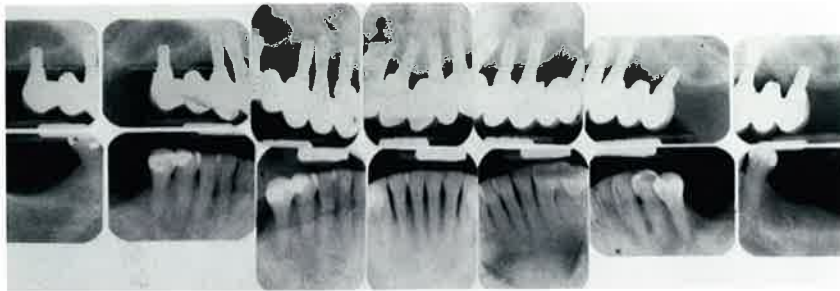


Figure 5b: Intraoral radiographs (11/90) clearly illustrate the fibrous encapsulation surrounding the most posterior fixture bilaterally (7 mm fixture.)

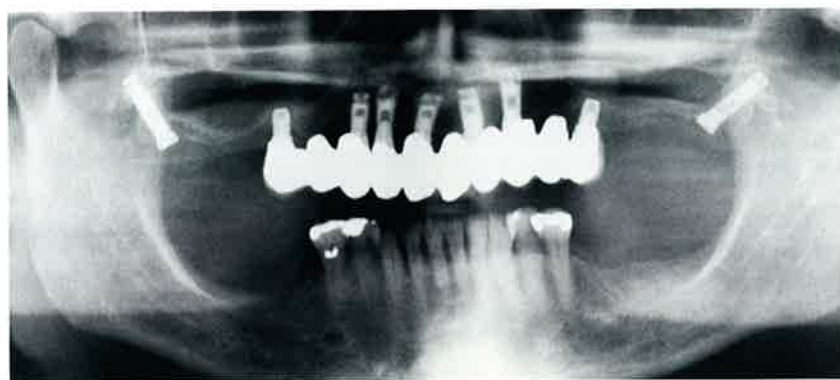


Figure 6: Panradiograph immediately following the maxillary pterygoid fixture installation November 1990. The 7mm fixtures continue to provide minimal support to the anterior prosthesis.

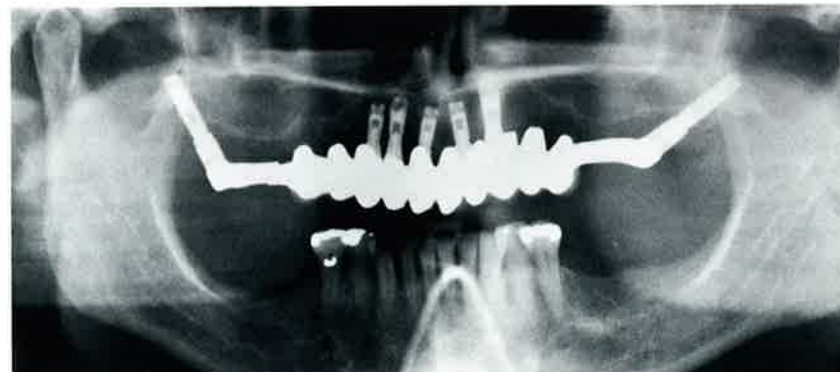


Figure 7: Modification of the existing porcelain fused to gold prosthesis with gold bar extensions obtaining support from the osseointegrated pterygomaxillary fixtures to stabilize the entire maxillary implant reconstruction.

The patient now understood that removal of the 7mm fixtures would be required in order to avoid a posterior cantilevered situation. Placement of pterygomaxillary fixtures bilaterally were recommended and placed in November of 1990 (figure 6). The 7mm fixtures were allowed to remain in place until the new fixtures osseointegrated. In June 1991 the patient returned for second stage surgery, uncovering the pterygomaxillary fixtures. Both fixtures appeared stable. The existing 7mm fixtures were removed and the porcelain fused to gold tissue integrated prosthesis was modified with an extension bar obtaining support from the posterior fixtures (figure 7).

The patient has had stability and no additional change in the osseous support of the fixtures over the past eight months.

continued on page 4

Date	PROCEDURE
1983	Patient diagnosed with advanced periodontal disease.
5/86	Referred to Prosthodontics Intermedica. Hopeless condition of the maxillary arch. TTP developed.
1/87	Delivery of a high impact acrylic restoration extending from tooth #2 to #14.
6/87	4 Fixtures placed in maxillary anterior. Without the use of a guidestint, against TTP recommendations.
12/87	Uncovering of 4 fixtures. One fixture was mobile. Conversion prosthesis prepared.
9/88	5 additional fixtures added between the existing fixtures. <ul style="list-style-type: none"> • two 7 mm fixtures in the molar region, right and left sides • three 10 mm fixtures in the anterior.
6/89	Uncovering of the additional 5 fixtures. New conversion prosthesis adapted. Failed fixture removed. Fixed prosthesis w/o the distal cantilevers.
11/90	Reevaluation. Both 7 mm fixtures deintegrated. Placement of pterygomaxillary fixtures bilaterally.
6/91	Uncovering of pterygomaxillary fixtures. Both 7 mm fixtures removed. Final tissue integrated prosthesis modified with an extension bar supported by the pterygomaxillary fixtures.
2/92	Continued stability of the fixed prosthesis. No change in the osseous support of the fixtures.

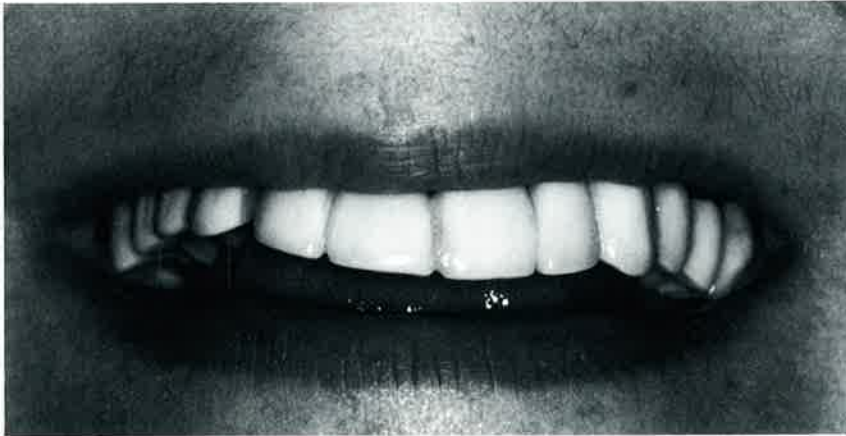

Figure 8: Preoperative smiling view (1987).

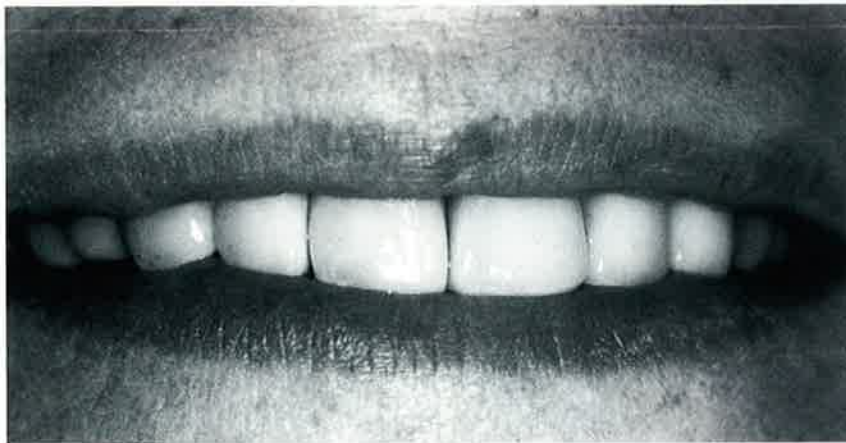

Figure 9: Postoperative smile (1991).

In conclusion, the management of patients with advanced periodontal disease proceeding through various transitions of prosthetic reconstruction can be accomplished. It is my recommendation that unless extremely dense cortical bone is present, that the use of 7mm fixtures in

the maxilla should be avoided. Use of long pterygomaxillary fixtures appears to be a reasonable approach for posterior stabilization. This procedure is clinically more difficult and requires intense coordination between various specialists treating the patient. ■

Osseointegration of Irradiated Tissue

G. Granstrom

Earlier investigations show that there is an impaired osseointegration in irradiated bone, especially in the orbital and zygoma regions. This could lead to several problems when performing surgery in the irradiated patient. The use of hyperbaric oxygenation (HBO) is known to neutralize several of the negative effects of irradiation in experimental studies.

In a clinical study, osseointegration was enhanced in a series of patients after pretreatment with HBO. Eighteen of 61 patients who had extroral titanium fixtures had undergone irradiation prior to surgery. Thirty of the 35 fixtures were stable at follow-up; five were not stable and were removed. Fixture loss in irradiated bone was 16.6% compared to a 2.5% in nonirradiated bone. More fixtures were lost in the orbita and zygoma than in the maxilla and temporal bones.

Patients who had irradiation in the area intended for fixture placement received 20 preoperative dives at 2.4 atmospheres, 90 minutes daily and 10 post-op dives. The chamber used was a multichamber type designed for treatment of up to 8 patients simultaneously. Routinely 3-4 patients are treated at the same schedule. The table below shows the results of patients treated with HBO to date.

% FIXTURE LOSS WITH TIME		
Irradiated group	Nonirradiated Control group	Irradiated HBO group
16.6%	2.5%	5.8%

Int. Workshop on Osseointegration in Skeletal Reconstruction and Joint Replacement, April 24-27, 1990, Aruba



Oral Hygiene Video For the Implant Patient

Educate your patients with a detailed film of home care techniques for implant patients.

Reinforce the hygiene instructions you have already shown your patients.

Optimize the time that your hygienist spends with home care instructions.

Legal documentation is verified by patient viewing homecare video.

1 Video \$ 25.00 5 Videos \$100.00

Return _____
Address _____

Please mail check and form to:
Institute for Facial Esthetics
467 Pennsylvania Avenue, Fort Washington, PA 19034
Tel: 215-643-5881 • Fax: 215-643-1149

PROSTHODONTIC Insights

is published by Prosthodontics Intermedica and distributed without charge to qualified individuals. Please request a subscription on your organization's letterhead.



*Fixed, Removable, Maxillofacial
and Implant Prosthodontics*

Prosthodontics Intermedica
467 Pennsylvania Avenue
Fort Washington, PA 19034 U.S.A.
Telephone: 215-646-6334

Burning Mouth Syndrome (continued)

Because the dentist cannot observe any signs on the oral mucosa and patients are persistent in their complaints, patients are often sent from the dentist to multiple specialists. In many cases the patients are increasingly considered to be "fakes" (or hypochondriacs*). Therefore it is important that these patients are treated by one and the same dentist. A prerequisite is that the dentist be capable of giving the patient psychological and pedagogical

guidance. A specialist in internal medicine or a psychiatrist should be consulted only if the medical history shows that there are general disorders.

The stomatological treatment plan prescribes appropriate hygiene, endodontic, cariologic, periodontal and prosthodontic therapy. Special hygiene measures, such as massaging the tongue and the oral mucosa stimulates the blood flow for removing plaque and debris. These

massages must be done with vitamin containing oils.

32% of all patients treated in this manner became completely free of symptoms; another 31% had clearly improved situations. It must be pointed out however that all burning mouth patients need a life long recall schedule, preferably by the same dentist.

* Editors comment

Center for Human-Computer Studies,
Uppsala University, Sweden

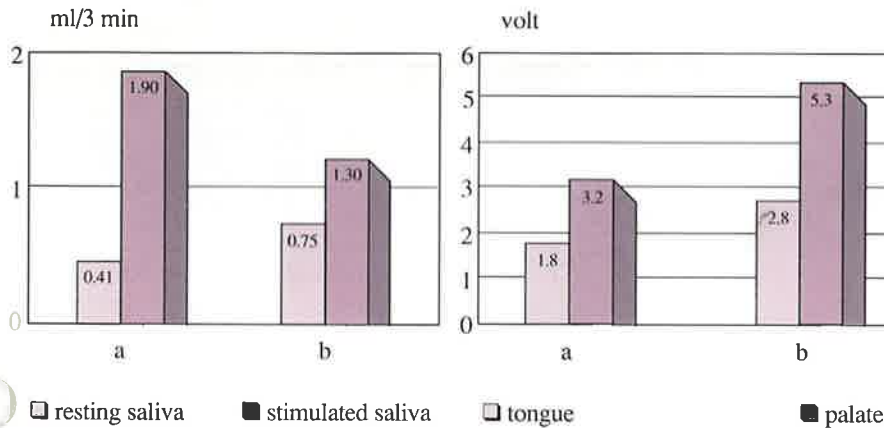


Fig. 1: Saliva secretion (registered in ml/3mi)
a - Pat. with burning mouth syndrome
b - control group

Fig. 2: Sensitivity threshold (registered in volt)
a - Pat. with burning mouth syndrome
b - control group

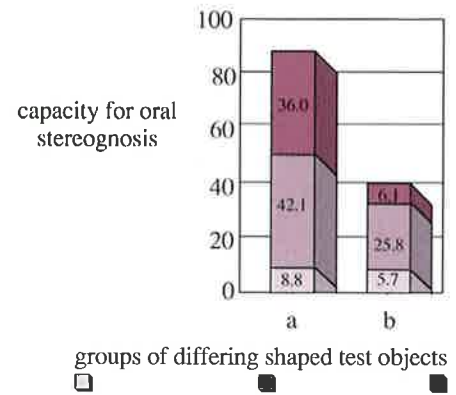


Fig. 3: Capacity for oral stereognosis
a - Pat. with burning mouth syndrome
b - control group

Framework Design (continued)

The metal-acrylic resin finish line should be placed as far coronally on the lingual surface as possible. Metal surfaces are more easily cleaned and maintained than acrylic resin surfaces. Plaque tends to accumulate at the metal-acrylic resin junction. Therefore, placing the junction as far coronally as possible will make it further away from the soft tissue, and the implants, and will facilitate cleaning the restoration.

Whereas access for hygiene is promoted by designing the restoration to be small and narrow, it may well compromise the strength of the prosthesis. Certain minimum dimensions and design principles are necessary to obtain adequate strength and stiffness in the prosthesis. The faciolingual width at the abutment cylinders should be approximately 5.5mm for strength and castabili-

ty. The faciolingual width between cylinders may be narrower when there is sufficient occlusogingival thickness for rigidity.

The height of the framework should be a minimum of 3mm between cylinders, but preferably higher to maximize stiffness and strength. *Stiffness is proportional to the cube of the height, but only directly proportional to the width according to the law of beams. Therefore, it is desirable to increase the height of the framework as much as possible.*

Factors enhancing hygiene form and strength of the implant bridge framework are mutually interdependent and play an important role in the long term success of the restoration

* Editors opinion
J Prosthet Dent 1992:67



Educational Opportunities
Sponsored By The Institute
For Facial Esthetics-
Pennsylvania's First Official
Brånemark Training Center

Prosthetic Training Program
For The Brånemark Method
Of Osseointegration

* Two Day Course, Includes
Hands-on Instructions

April 3-4, 1992
July 17-18, 1992
November 20-21, 1992

* All courses are AGD accredited

For More Information:
215-643-5881

The Bone-Implant Interface in Osseointegration

L - M Bjursten

Biomechanics and Osseointegration

R. Brånemark

1. Evaluation of implant performance

The clinical experience of the implant for the intended application and the intended implantation time is the only important parameter for any implant procedure. Patient selection may be critical as there are many clinical conditions in which the tissue to implant interaction may be impaired eg. rheumatoid arthritis, diabetes or those who have received therapeutic irradiation for cancer.

Our knowledge of interfacial processes between implant and tissue is very sparse and does not allow predictions for new materials or for applications that are not close to established ones. An experiment may be successful from a morphological point of view however the clinical experience may fail for mechanical reasons.

2. Osseointegration

From a clinical perspective, osseointegration means acute stability in a mechanical sense over the expected life time of the implant. Additional obstacles like passage through skin or mucous membranes adds to the specific requirements involved in the implantation procedure.

Following only the morphological criteria, "implant-bone contact without other intervening tissues", many implant materials meet the criteria for osseointegration. In order to determine the details of the morphology in osseointegration preparation techniques allowing the analysis of the intact interface must be established.

3. Methods to study the tissue interface to metallic implants

The first method allowing such analysis is the grinding technique where the implant and surrounding tissue is embedded en bloc and then milled to thin slices. A recent technique to overcome the problems associated with separating the metal from the bone tissue is based on electrochemical dissolution of the metal in the implant after embedding.

4. The interface between tissue and titanium

A thin oxide layer covering the surface of titanium is spontaneously formed at atmospheric conditions. Inflammatory cells, especially macrophages, have been shown to be present close to titanium implants in soft tissue. When H_2O_2 excreted by these cells was allowed to react with metallic titanium *in vitro*, an increased oxidation of the titanium was demonstrated and titanium-peroxy compounds were formed as gel on the surface.

When human polymorphonuclear leukocytes (PMNL:s) were incubated with the titanium-peroxy gel *in vitro* the cells bound avidly to the gel surface without loss of viability. The healing response may be modified positively by exposing the implant to hydrogen peroxide prior to implantation.

5. Hypothesis for the titanium - tissue interaction

The *in vitro* conditions for formation of a hydrated matrix containing titanium peroxy-compounds are likely to be present also *in vivo*. If this is true the actual interface of the titanium implant to the living tissue is a hydrated titanium peroxy matrix. This may explain transportation of titanium in a soluble form from the implant to deposits in surrounding tissues, and therefore the proven excellent biocompatibility of titanium.

6. Possible disadvantages of titanium as a biomaterial

Adverse effects due to large amounts of inhaled titanium seems to be lacking. This may be explained by its low solubility and low toxicity. One case report of alleged allergy to titanium is reported. However the patient was also allergic to nickel which has tested as a coinciding allergy for titanium.

Joint prostheses with titanium as a sliding surface often show a high wear rate and massive discoloration of the surrounding tissues which may be an esthetic problem.

What load can an osseointegrated fixture tolerate? Is there a difference between normal bone and bone in rheumatoid arthritis?

Three fixtures were inserted in the proximal metaphyseal region of the tibia in an animal model for mechanical evaluation. After osseointegration, the fixtures were mechanically tested in pull-out, torsion and lateral loading. The tests were performed to failure. The following values average were obtained:

Failure pull-out force	1500 N
Failure torque	0.5 Nm
Failure lateral load	200 N

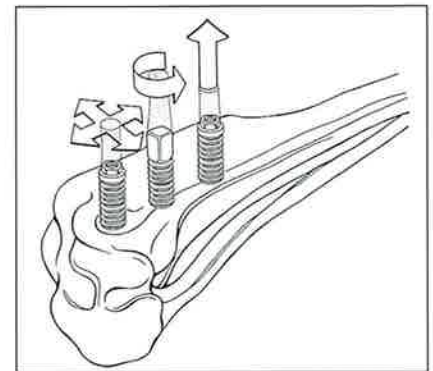


Figure 1: Schematic drawing of the test arrangement of fixtures installed in dog tibia. Tests were performed in pull-out, torsion and lateral loading as indicated.

The torque test did not reveal any major elastic deformation in the interface, but surprisingly a plastic deformation was observed beginning at very low torque. The shear stress at failure in the interface was 5MPa (torque test), and 35MPa in the surrounding bone (pull-out test).

Torque tests were performed on fixtures installed in the proximal metaphysis of the human tibia to evaluate possible differences of osseointegration between normal bone and patients suffering from osteoarthritis or rheumatoid arthritis. The mechanical capacity varied up to 8 times.

The prognosis for a successful treatment outcome is likely to be based on the bone quality of the individual patient, determining whether or not it will be possible to achieve and maintain osseointegration.