

PROSTHODONTIC

Insights

A Digest of Recent Trends, Techniques and Clinical Concepts of Dental and Facial Esthetics



Thomas J. Balshi, DDS, FACP

Osseointegration for reconstruction of a hemimandibulectomy

Radical surgery was performed to remove the left side of the mandible without the benefit of biologic reconstruction. During the following 36 years the patient functioned with a hinged, removable partial denture anchored on the mandibular right side to her remaining natural dentition. She was referred for implant prosthodontic treatment when deterioration of the remaining natural dentition caused inability to function with the partial denture.

The only teeth remaining in the mandibular arch were numbers 24, 25 and 26. Numbers 25 and 26 were previously crowned and splinted to function as retainers for the removable partial denture (Figures 1a, b, & are 3). The patient func-

(Continued on Page 2.)

Biological requirements for material integration

O'Neal et al

A variety of synthetic devices have evolved that may be implanted and integrated within the masticatory apparatus for symmetry and function in the host. Implantation of synthetic devices have mandated an increased emphasis on understanding the tissue-material interactions so that implant success can be optimized. This article reviews the biological requirements for implant-tissue integration, with specific focus on the role of adhesion molecules and cytokines (growth factors).

Patient medical and dental history, including the quality of existing soft and hard tissues of the oral cavity, must be weighed prior to therapy. Complications that mimic the primary disease might predispose to failure of the implanted device. Patients with a significant history of periodontal disease warrant distinctive mechanical and antimicrobial considerations prior to the placement of dental implants. Early signs of failure, e.g. peri-implantitis or excessive functional stress, must be recognized in order to prevent implant loss.

A sign of a successful implant is the achievement of osseointegration between the device and surrounding tissue. Accomplishment of an optimal interface would reduce failures that are considered to be the result of or related to fracture or enhanced bone resorption and fibrous tissue formation.

Cytokines and cell adhesion molecules play a critical role in determining which cells will populate a given area and the ability of these cells to react with other cell types, with the extracellular matrix, and with the implantable materi-

als in the local environment. In addition, the local environment and the implant material can alter the responses of cells to local factors.

Cytokines are produced by a variety of cell types and have diverse bioactivities which include promotion and/or inhibition of cellular proliferation and differentiation, depending on the specific cell type. Cytokines may increase the rate of wound closure, increase the rate of proliferation of fibroblasts and epithelial cells at the site of healing, increase the rate of vascularization, and enhance the rate of collagen deposition.

Growth factors associated with bone have been evaluated for their potential use in the regeneration of bone tissue lost as a consequence of periodontal disease. While an attractive concept for improving implant sites, sufficient information is not yet available to support the value of such treatment. Nevertheless, the use of slow-release biodegradable polymer systems, which incorporate cytokines and/or other factors, may be advantageous for enhancing bone quality at implant sites.

Adhesion molecules associated with cytokines are reviewed, as are adhesion molecules that may be localized to an implant site. There is increasing evidence that such associations are important for signaling cells to synthesize or respond to these or other extracellular matrix molecules. Results suggest that specific proteins or synthetic molecules may prove beneficial for enhancing cell attachment and spreading of cells to artificial devices and thus may enhance the predictability

(Continued on Page 3.)

Osseointegration . . .

(Continued from Page 1.)

tioned predominately with the remaining natural dentition. The remaining portion of the right mandible was maintained in a slightly lingualized occlusion with the maxillary dentition.

The patient had refused biologic reconstruction with an iliac crest transplant due to apprehension. After being presented several treatment plans, the patient elected to proceed with a fixed prosthesis supported by six Branemark implants positioned to take advantage of the remaining mandibular bone, permitting a rigid, cantilevered extension to the left side, providing soft tissue support for the lips and cheek as well as occlusal function.

The remaining incisors, numbers 24, 25 and 26 were extracted, alveoplasty was used to level the crest of the remaining mandibular anterior ridge. Six Branemark implants were placed in the remaining mandible. An 18 x 3.75 mm. implant was placed in the mandible immediately anterior to the mental foramen. A 15 x 3.75 mm. implant was placed at a 45° angle to the crest of the ridge. With the exception of the 8.5 mm. implant in the area of tooth number 30 which received a standard 3 mm. abutment, all other implants received titanium EsthetiCone abutments.

At the time of Stage II surgery, a conversion prosthesis was constructed using the patient's interim removable complete denture. The conversion prosthesis had a 15 mm. cantilevered section in the region where the left side of the mandible had been removed. Two weeks following Stage II surgery, the patient returned for evaluation of the implant supported cast framework. The following week the permanent bone-anchored prosthesis was delivered (figure 4.)

Radiographic analysis showed excellent bone response to the Branemark titanium implants (Figure 5a, b). The cantilevered portion extending into the area of the missing left mandible provided excellent cheek and lip support as well as occlusal function.

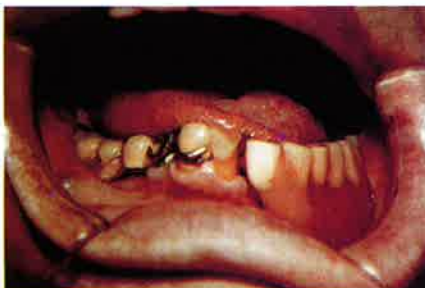

Figure 1a and 1b
Preoperative condition.

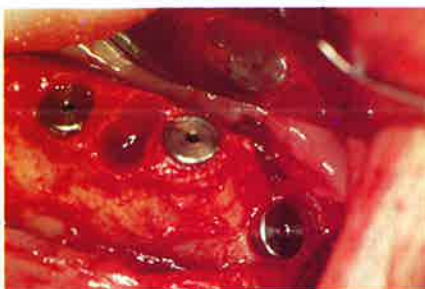
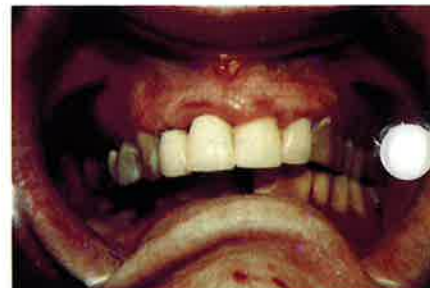
Figure 2a
Fixture placement at Stage I surgery. Note the last implant at a 45° angle to the crest of the ridge.

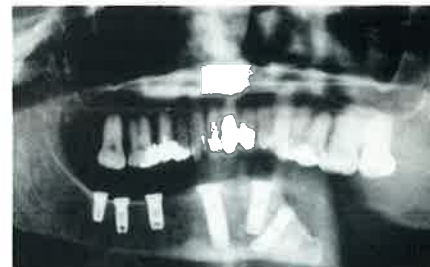


Figure 2b
Panradiograph following fixture installation.

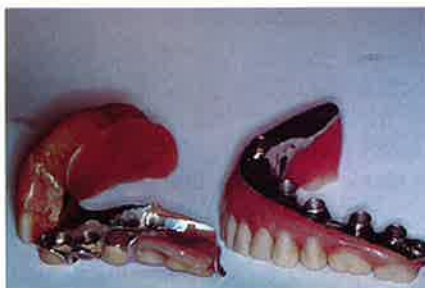

Figure 3
Previous hinged removable partial denture compared to the nonremovable tissue integrated prosthesis.

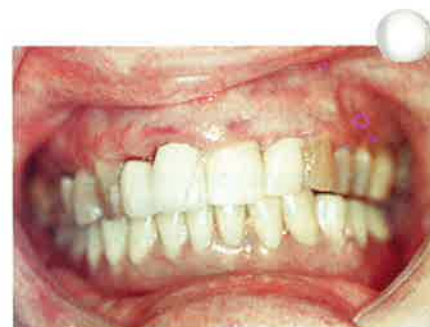

Figure 4
Tissue integrated prosthesis fastened to six osseointegrated Branemark implants.

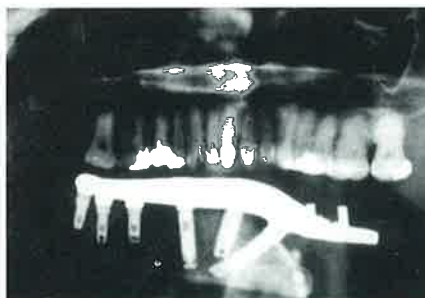
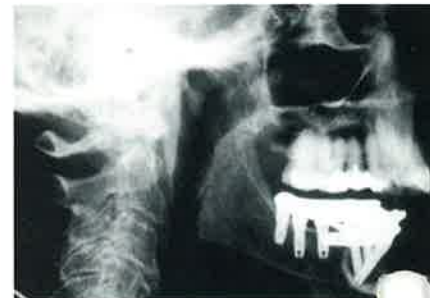

Figure 5a & 5b
Postoperative panradiograph with tissue integrated prosthesis fastened to the osseointegrated implants.



Biological requirements . . .

(Continued from Page 1.)

of implant tissue integration.

Regardless of the cause of implant failure, the end-result is the same. The clinical picture of peri-implantitis can include mucosal inflammation, increasing attachment loss, possible exposure of a portion of the implant to the oral environment, radiographic evidence of bone loss, and/or the potential loss of the implant over time.

Once an implant system with the prosthetic component is functional, and peri-implantitis occurs, two major problems make the likelihood of a new osseointegration unpredictable: 1) techniques for restoration of the implant surface in vivo have not been perfected; and 2) the techniques for restoration of new healing bone in close contact with the implant have not been refined.

Although conventional periodontal regeneration techniques such as grafts with demineralized cortical bone powder, demineralized freeze-dried bone and/or hydroxyapatite, are useful in the treatment of failing implants, minimum follow-up and no histology are available to support these methods for treatment of peri-implantitis. Guided tissue regeneration means of a polytetrafluoroethylene membrane has been used for several treatments, including ridge augmentation and subsequent placement of a new fixture, and treatment of peri-implantitis defects in an already osseointegrated fixture.

As the number of implants placed increases, the need for understanding of the failure modalities is becoming critical. Major research efforts should include the following:

1. Exploration of the predispositions to implant failure by identification of factors, both biological and mechanical, that promote the failure seen clinically.
2. Development of methods for early recognition of potential factors which contribute to implant failure.
3. Establishment of clinical procedures that would enhance the biocompatibility of host with implant materials before placement of the implants.
4. Once potential failure is recognized, development of predictable techniques for correction of the loss of osseointegration.

J of Oral Implantology Vol. XVIII/No. Three/1992

The wide fixture: a solution for special bone situations and a rescue for the compromised implant.

Part I

B. Langer et al

A common solution to immobilization problems is to redrill the site and place a longer fixture that will engage more compact bone apically. If all available bone height is utilized and the fixture is still mobile, a fixture of increased width may offer the only solution to achieving primary stability in a previously drilled site.

Using the same surface characteristics as the original Branemark fixture, a new self-tapping design was created in which wider threads were brought up to the marginal platform of the fixture. The fixture diameter was increased from 3.75 mm. to

The standard Branemark drilling components are used to prepare the site. A 4.3 mm. pilot drill, a 4.3 mm. twist drill, and tap were developed to enlarge the site for the new diameter fixture. All other components of the Branemark System are the same.

The indications for use of the 5.0 and 5.5 mm. diameter fixtures were: poor bone quality; inadequate bone height; immediate replacement of non-osseointegrated fixtures; and immediate replacement of fractured fixtures (Figures 1 and 2).

The 6 X 5.0 mm. fixture can be used with a greater degree of safety than longer standard fixtures in areas having acceptable bone width and density but inadequate bone height, especially in the posterior mandible. What is lost in height is partially compensated for by increasing the width and thus actually adding to the surface area of bone to titanium. In many cases, use of the wider fixture eliminates the need for sinus elevations or bone augmentation procedures and allows the patient to be treated routinely and in a more timely manner.

Replacement of a nonintegrated fixture at stage II or later by

immediately replacing the lost fixture with a wider fixture can circumvent the six months normally used for socket healing from fixture removal to fixture

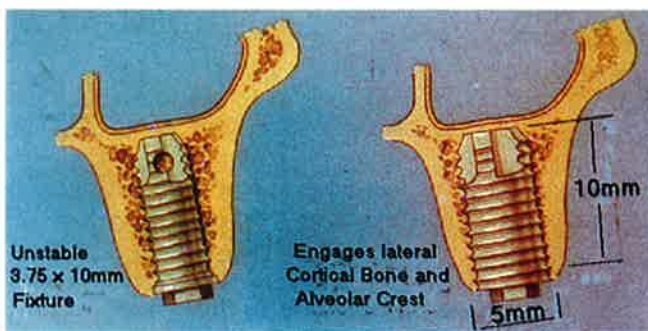


Figure 1

In poor bone quality, the 5.0 and the 5.5 mm. fixture engages lateral cortical bone and alveolar crest.

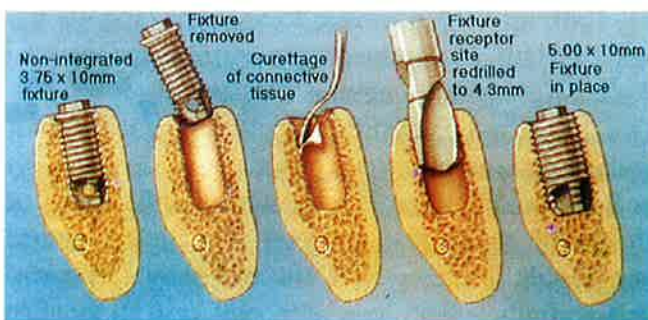


Figure 2

A: Standard fixture surrounded by weak bone. B: Removal of the loose fixture. C: A 4.3 mm. pilot drill used to widen the site. D: A 4.3 mm. twist drill. E: Wider 5.0 mm. fixture self-tapped into place.

5.0 mm. providing a dimensionally greater surface area. The wide fixtures were made in the lengths of 6, 8, 10, and 12 mm. A 5.5 mm. diameter fixture was also designed in the same lengths.

(Continued on Page 6.)

◆
**Educational Opportunities
Sponsored By The Institute
For Facial Esthetics-
Pennsylvania's First Official
Brånemark Training Center**

**Training Programs
For The Brånemark Method
Of Oseointegration**

October 7, 8, 9, 1994
3-Day Surgical Training
w/Hands-on Instruction

April 15-16, 1994
November 11-12, 1994
2-Day Prosthetic
Training w/Hands-on Instruction

*All courses are AGD accredited

For Information: Tel: 215-643-5881
Fax: 215-643-1149

Pressure Change on Bone Marrow Supporting Denture: Preliminary Observations

M. Ogiso, et al

Preliminary experiments on a root and abutment-separated two-piece apatite implant investigated the bone marrow pressure (BMP) inside the jawbone under the denture during biting. BMP was checked by inserting a catheter probe, attached to a blood pressure measuring apparatus, into the jawbone through a hole drilled in the first molar area of the buccal denture base plate. The BMP increased under the denture during bite enforcement. A lower rate of success was shown in implant cases when a provisional denture was used. These preliminary findings indicate the possible rise in BMP due to the use of the provisional denture, which may contribute to hindrance of normal bone healing around implants and result in implant failure.

*Journal of Long-Term Effects of
Medical Implants 3(3):251-260 '93*

Fractures of the Fixture Component of an Osseointegrated Implant

M.J. Morgan et al

Fixtures that had fractured in clinical use were gathered and examined using scanning electron microscopy (SEM) and the surface characteristics were noted. To confirm the type of fracture, new fixtures were fractured experimentally under overload and under fatigue conditions, and their surfaces were also examined with SEM showing fracture surfaces similar in appearance to the clinical specimens.

The clinical specimens were commercially pure (CP) titanium Branemark fixtures (Nobelpharma, AB, Gothenburg, Sweden), five coronal pieces and four apical pieces, from five patients. The fractures occurred after 1-5 years at a level corresponding to the end of the abutment screw. Four of the fixtures were the most mesially located implants in partial freestanding prostheses with distal cantilevers; two of these were in the posterior area of the mandible and two in the maxilla. The fifth specimen was the distal implant in a complete bone-anchored

mandibular prosthesis, in which the implants were nearly in a straight line because of limited bone volume resulting from alveolar ridge resorption.

Fixtures that had fractured in clinical use did so by fatigue, not overload. The high local stresses required for crack initiation are thought to be the result of three conditions:

1. Bone resorption from the coronal region of the fixture creating higher bending stresses.
2. Bending and axial stresses caused by biting and chewing are higher.
3. Cracks initiate and propagate under stress created by the sharp corner at the root of a thread.

Clinical and radiographic monitoring at regular intervals to confirm that the occlusion is well balanced and that loads are evenly distributed to the implants is critical in order to reduce the possibility of bone resorption.

*Int J Oral Maxillofac Implants 1993;
8:409-414*

Design and surface characteristics of 13 commercially available oral implant systems

A. Wennerberg, et al

The purpose of this study was to briefly describe the design and characterize, in qualitative as well as quantitative detail, the surface structure of 13 different commercially available oral implant systems. The implants (eight cylindrical and five screw-shaped) were divided into four groups with respect to their different surface materials: A) hydroxyapatite-coated; B) titanium plasma-sprayed; C) titanium alloy; and D) commercially pure titanium implants.

Differences in surface structure were obvious between the four groups. The HA-coated implants in Group A, consisting of six cylindrical systems, had the highest surface roughness. In Group B only 1 of the 13 implants had a titanium-plasma-sprayed surface. Three implants in Group C were manufactured of titanium alloy, two screw-shaped and one

cylinder. The three implants in Group D, all screw-shaped, were made of commercially pure titanium. As a group these were the smoothest implants in this study.

Relatively small differences that exist in surface roughness among implants in the commercially pure titanium group, such as the 3I standard screw and the Nobelpharma (the smoothest of the commercially pure titanium screws), could well result in differences in tissue responses. There is a great need for further studies in this area. To automatically regard different implant systems, obviously varying with respect to design and surface roughness, as capable of producing the same clinical results is without justification.

*Int J Oral Maxillofac Implants 1993;
8:622-633*

Risk factors associated with dental implants in healthy and medically compromised patients

R.A. Smith et al

At the National Institutes of Health Consensus Development Conference on Dental Implants a study was conducted to investigate the medical risks associated with dental implants. The study sample consisted of 104 patients who received a total of 313 Branemark dental implants (Nobelpharma AB, Gothenburg, Sweden). The mean age was 52.8 and 62.5% of the sample was female. Seventy-six percent of the sample reported having one or fewer medical problems. The mean number of implants placed was 3.0. Nineteen patients (18.3%) had implants placed in the maxilla, 80 patients (76.9%) had implants placed in the mandible, and 5 patients (4.8%) had implants placed in both the maxilla and mandible. There were 59 (18.8%) implants placed in the maxilla and 254 (81.2%) implants placed in the mandible. Ninety-nine of the 104 patients received an implant supported prosthesis that had been loaded up to 4 1/2 years.

Overall, 19 (5.8%) implants failed in 14 patients (13.5%). Nine implants failed in the maxilla (15.2%) and 9 implants failed in the mandible (3.5%).

The results showed that the number of medical problems were not statistically associated with surgical perioperative complications from implant surgery. Surgical risks in implant patients are defined as the probability of morbidity and mortality during the perioperative

(Continued on Page 6.)

PROSTHODONTIC Insights

is published by Prosthodontics Intermedica and distributed without charge to qualified individuals. Please request a subscription on your organization's letterhead.



Fixed, Removable, Maxillofacial
and Implant Prosthodontics

Prosthodontics Intermedica
467 Pennsylvania Avenue
Fort Washington, PA 19034 U.S.A.
Tel: 215-646-6334
Fax: 215-643-1149

Systemic Osteoporosis and Oral Bone Loss Evidence Shows Increased Risk Factors

M.K. Jeffcoat and C.H. Chestnut III

Older patients with osteoporosis are at increased risk for tooth loss. Generalized bone loss from systemic osteoporosis may render the jaws susceptible to accelerated alveolar bone resorption. Clinicians should also know prevention and treatment techniques for oral and systemic bone loss. Referral to an internist or gynecologist for diagnosis and treatment is recommended when systemic bone loss is suspected.

Osteoporosis is characterized by low bone mass and microarchitectural deterioration of the bone, which leads to increased bone fragility and risk of fracture. Data suggests that women lose more teeth than men, especially after menopause, putting them at risk for residual ridge resorption.

Age and estrogen deprivation appear to be major initiating factors in the onset of systemic osteoporosis. Some medications, especially long-term steroids, increase the risk of bone loss. Mechanical factors, such as the lack of exercise and disuse atrophy in the absence of teeth, also contribute to tooth loss.

Researchers observed a strong correlation between dental and total bone mass in females. Some reported that the height of the alveolar ridge in edentulous women correlated with total body calcium, which may indicate that women with severe post menopausal osteoporosis retain less bone following tooth loss. When skeletal bones lose mass, the mean bone density of the mandible also decreases.

Osteoporosis is caused by an uncoupling of the bone resorption/formation process, with an exaggeration of resorption, reduction in bone formation or a combination of both. In most post-menopausal osteoporosis, the problem is abnormal increase in resorption and not a decrease in bone formation. The net result is a reduction in bone mass and an increased risk of fracture. Parathyroid hormone and 1, 25-dihydroxyvitamin D, which are systemic stimulators of bone resorption, are important in controlling bone remodeling. Cytokines and pathologically high levels of prostaglandins have been associated with the local bone

loss of periodontitis.

Efforts to combat oral bone loss are directed at plaque control, preventing tooth loss and identifying patients at risk for bone loss. Oral implants offer promise for the regeneration of bone. Since oral and systemic bone loss appears to have common mechanisms at the cellular level, agents that slow osteoporotic bone loss, such as estrogen, could slow bone loss in the oral cavity. Blocking the cyclo-oxygenase pathway, thereby decreasing the production of prostaglandin E2, significantly inhibits alveolar bone loss in patients with adult and rapidly progressive periodontitis. Calcium supplementation is a mainstay of osteoporosis prevention and treatment as is good nutrition and regular exercise help prevent osteoporosis. New drug treatments are under evaluation, including bisphosphonates to inhibit osteoclasts and injections of calcitonin to reduce bone resorption. A recent study demonstrated that women receiving hormone replacement had a 30 percent reduction in the rate of fracture of the distal radius and that the protective effects increased progressively as the duration of therapy increased.

Measuring small changes in bone mass is difficult. Thirty percent to 50 percent of the bone mineral may be lost before conventional interpretive radiography can detect a change in oral bone mass. In dentistry, several methods have been developed to assess bone loss. The height of the alveolar crest on the tooth root may be estimated. Many techniques exist to measure bone loss along the tooth root, including computer-assisted methods. Digital-subtraction radiography more fully exploits the information in dental radiographs. Dual-energy X-ray absorptiometry or DXA can measure bone density at sites such as the hip, spine, and wrist. This technique allows more rapid scanning and improved resolution resulting in greater precision. DXA measurements at the time of menopause may accurately predict future fracture risk.

JADA, Vol. 124, November 1993 #49

Risk factors . . . (Continued from Page 5.)

period. They can be related to the patient's medical problems, the anesthesia, or the procedure, or they may be provider related.

The number of medical problems were not statistically associated with an increased risk of implant failure. Local factors (bone quality, bone quantity, bone trajectory, and surgical and prosthodontic techniques) are probably more significant indicators of outcome than associated medical conditions.

Sixty-five of 104 patients in this study were women, most in the postmenopausal age period. The patient's sex was not statistically associated with perioperative surgical complications or implant failure.

The number of implants placed was statistically associated with an increased risk of surgical complications and/or implant failure. Placing multiple implants requires more mucoperiosteal stripping, compromising blood supply, more operating time, and more contamination of the wound, all of which may contribute to the increased complication rate.

Patients taking insulin, oral hypoglycemic agents, or steroids are reasonably good candidates for implant placement. Additional studies are needed and are currently in progress.

The majority of implant placement procedures were performed under intravenous sedation (52%) or local anesthesia only (42%). Ninety-two (88%) of the abutment connection procedures were performed under local anesthesia alone. It does not appear that dental surgery patients have increased anesthetic related complications.

According to the consensus report implant surgery and the required anesthetic appear to be safe procedures even in the medically compromised patient.

*Int J Oral Maxillofac Implants 1992; 7:367-372
Printed with permission of Quintessence Publishing Co. Inc., Carol Stream IL*

The wide fixture: . . .
(Continued from Page 3.)

replacement. Because the removal of a nonintegrated fixture and its replacement are done simultaneously, tissue coverage is more difficult. The use of pedicle grafts advanced coronally and sutured with mattress ties has proved successful. Connective tissue grafts and membranes have been used in certain instances but are not always necessary.

A wider fixture can also be used to replace a fractured fixture. Immediate placement of the 5.0 mm. diameter fixture will engage the dense lateral walls of bone not damaged by the trephine drill used to remove the fractured fixture.

Retrieval of the separated fixture requires the placement of a long healing abutment into the remaining internal threads of the fixture, allowing the surgeon to elevate the fixture out of its submerged location without damaging the socket. The residual site is a receptive area for a new fixture since fixture fractures occur mostly in dense bone.

After three years the results of using the wider fixture have been extremely promising. No fixtures were lost prior to the uncovering procedure at stage II surgery and no fixtures were lost to infection. Results to date suggest that these new fixtures could be effective in clinical situations involving poor bone quality, inadequate bone height, and when nonintegrated implants or fractured implants are replaced immediately.

Int J Oral Maxillofac Implants 1993; 8:400-408

The association between the failure of dental implants and cigarette smoking

C. Bain and P. Moy

The influence of smoking on the failure rate of Branemark dental implants was evaluated over a period of six years. A total of 2,194 Branemark implants (Nobelpharma USA, Chicago) were placed in 540 patients. When patients were divided into smoking and nonsmoking groups, it was found that 390 implants (17.8%) had been placed in smokers and 1,804 implants (82.22%) in nonsmokers. Of the 390 implants placed in smokers, 44 were classified as failures (11.28%), while of the 1,804 implants placed in nonsmokers, only 86 implants failed (4.7%). Overall failure rates were highest in the posterior maxilla and lowest in the anterior mandible.

The findings in this study identify smoking as a major factor in implant failure. If one accepts that smoking has a detrimental effect on implant prognosis, the next logical question is how long the potential implant patient who smokes will have to abstain to have an equal prognosis with the nonsmoker. It seems likely that the longer time frame associated with osseous healing and the osseointegration process would require a longer period of abstinence. The authors suggest that the patient cease smoking at least one week prior to surgery and avoid tobacco for at least two months after implant placement.



Oral Hygiene Video For the Implant Patient

Educate your patients with a detailed film of home care techniques for implant patients.

Reinforce the hygiene instructions you have already shown your patients.

Optimize the time that your hygienist spends with home care instructions.

Legal documentation is verified by patient viewing homecare video.

1 Video \$ 35.00

5 Videos \$150.00

Return _____

Address _____

Please mail check and form to:
Institute for Facial Esthetics

467 Pennsylvania Avenue, Fort Washington, PA 19034
Tel: 215-643-5881 • Fax: 215-643-1149

Int J Oral Maxillofac Implants 1993; 8:609-615