

Advanced Periodontal Disease Eliminated With Osseointegrated Implant Prosthodontics



Thomas J. Balshi,
D.D.S., F.A.C.P.

The treatment of periodontal disease has made giant strides in the last half century. A better understanding of the etiology as well as improved surgical techniques have permitted patients with early to moderate periodontitis to retain their natural teeth for many years. However, in cases of advanced periodontal disease, especially in younger patients, traditional periodontal surgery and prosthodontic intervention may only provide interim stability. Diminished bone around a small quantity of remaining roots leads to insufficient functional support, permitting the continued periodontal deterioration to advance rapidly.

With the predictability of osseointegrated dental implants providing long term support over the last 30 years, treatment planning patients with advanced periodontal disease should take a different approach. To illustrate this concept, the following

patient report highlights the evaluation, treatment planning process, and therapeutic methodology. The goal in this instance was to provide the patient with a fixed prosthetic reconstruction concomitant with the elimination of the periodontal disease.

The patient is a white male (43) who was referred in 1993 with advanced periodontal disease, mobile teeth, and general oral debilitation (Fig 2). His medical history was non-contributing to his oral health. He had no allergies to medications, however, he did admit to smoking (one pack per week) and occasional social use of alcoholic beverages.

DENTAL HISTORY

His dental history was significant in that a maxillary porcelain fused to metal crown and bridge reconstruction was performed five years prior to the referral (Fig 3). The patient continued with routine dental treatment on a six month recall program. The mandibular anterior teeth, although mobile, were splinted with composite resin. A wire occlusal A-splint was used to stabilize the mandibular posterior dentition (Fig 4).

MAXILLARY ARCH

At the initial examination, the patient had several significant problems. The maxillary right posterior fixed bridge (# 2-6) was loose. It's removal in an alginate impression included removal of the posterior abutment tooth (#2) from the socket

(Fig 5a,b,c.). The remaining teeth had advanced mobility. Of the remaining anterior teeth, teeth #9 and 10 both had periapical lesions evident radiographically. On the maxillary left posterior, post and cores perforated laterally on teeth #12 and 13 (Fig 2). The left posterior splint with a molar cantilevered pontic (# 11-14) exhibited advanced buccal-lingual mobility.



Figure 1. The look of patient satisfaction!

MANDIBULAR ARCH

The right and left mandibular posterior dentition had 60-80% bone loss with a class III furcation noted on the molars. The mandibular anterior teeth had 70-100% bone loss (Fig 2).



THE PATIENT'S DESIRES

Although the patient realized the immanent loss of numerous teeth, he had an extreme desire to keep a fixed dentition and, if at all possible, avoid the use of a removable prosthesis. His stated goal was to ultimately have "permanent teeth".

TREATMENT PLAN

The treatment plan developed for this patient focused on the class III modification of the original Brånemark method which permits the patient to undergo an osseointegrated implant reconstruction while retaining periodontally hopeless teeth to support a

edentulous areas in the mandible. Implants placed into immediate extraction sites included wider diameter implants as noted on the panradiograph (Fig 7). Immediately following implant placement surgery the acrylic provisional restorations were cemented and the occlusion was refined.

Ten days after implant placement, the patient returned for suture removal and further refinement of the provisional restorations.

Following three months healing in the mandibular arch and five months in the maxilla, second stage implant surgery was performed and conversion prostheses were constructed by modifying the existing provisional restorations. Following connection of the provisionals to the osseointegrated implants, the remaining periodontally compromised abutment teeth were removed and the mucosa sutured to obtain primary closure.

The mandibular arch received a traditional Brånemark bone anchored bridge reconstruction while the maxillary arch was restored with a porcelain fused to high gold tissue integrated prosthesis (Fig 8,9).

RESULTS OF TREATMENT

The results of osseointegrated implant intervention for patients with advanced periodontal disease has several benefits. The positive psychologic management of the patient is significant. At no time during the course of treatment is the patient left without a fixed restoration. The patient's self esteem and confidence are maintained by avoiding a removable prosthesis.

The biologic benefits of osseointegration are also important. Early intervention and the removal of periodontally compromised teeth help maintain higher bone levels than those patients who lose their dentition and undergo

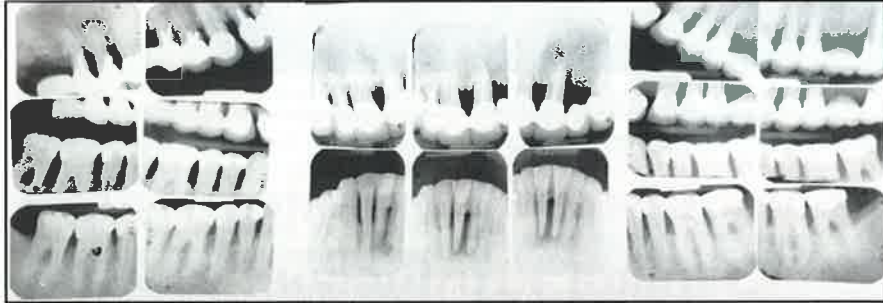

Figure 2. Panradiograph depicting preexisting condition.

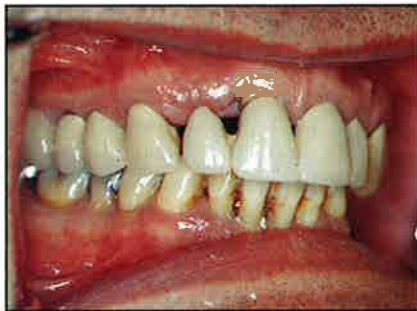

Figure 3. Previously existing maxillary porcelain fused to metal restoration.

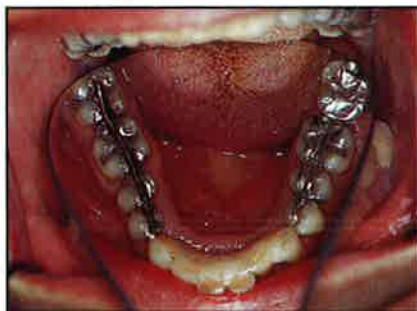

Figure 4. Wire splinting of the mandibular posterior dentition.

fixed provisional prosthesis. Strategic planning prescribed the retention of four teeth in the maxilla and four teeth in the mandible to function as abutments for provisional restorations while adjacent Brånemark implants were allowed to osseointegrate. The sequence of providing such treatment included the preparation of all eight abutment teeth prior to extraction of the adjacent periodontally hopeless teeth (Fig 6a, b). When the preparations were completed, the periodontally hopeless teeth were extracted. The extraction sites were thoroughly debrided of all granulation tissue. Temporary suture closure of the surgical sites was performed to facilitate the relin of the provisional fixed prostheses.

While laboratory technicians refined the heat processed high impact acrylic provisional restorations, Stage I implant surgery was performed for both the maxilla and mandible. The maxilla received 10 Brånemark implants and 8 were placed in the

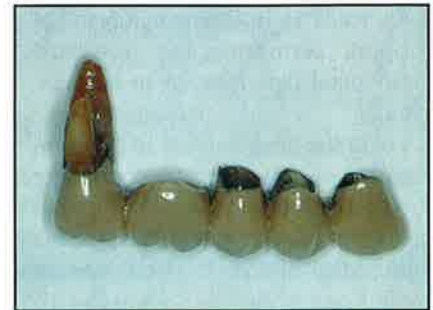
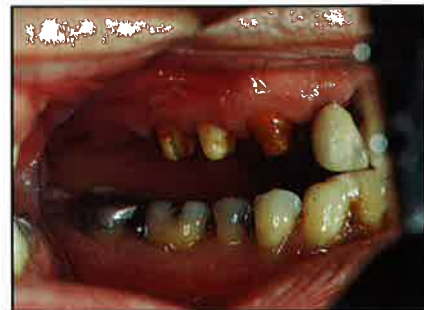
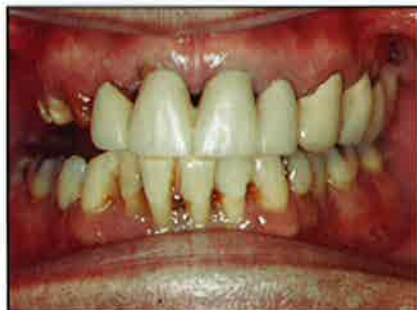Figure 5a, b, c. Maxillary right posterior fixed bridge, including the posterior abutment tooth, which came out in the alginate impression.

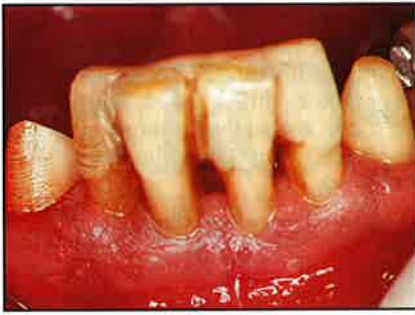

Figure 6a. Splinted periodontally hopeless teeth.

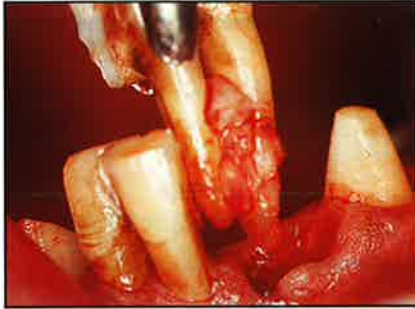

Figure 6b. Extraction of the periodontally hopeless teeth.

the physiologic process of bone resorption often associated with the use of removable prostheses.

It is also well known that osseointegrated Brånemark implants help main-

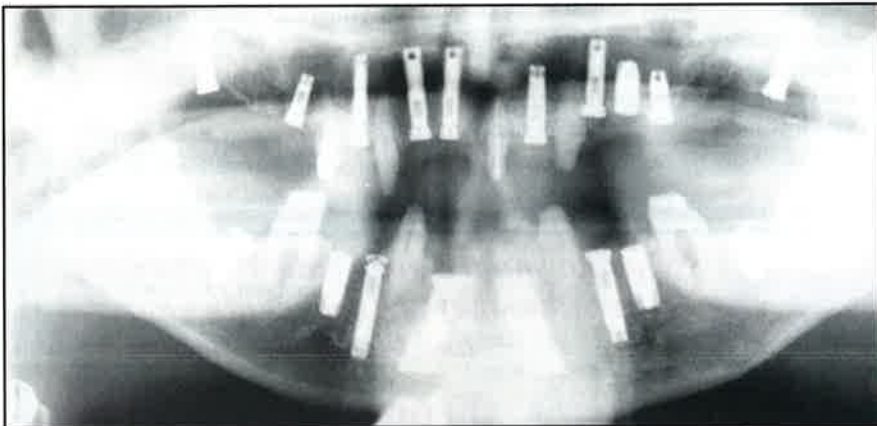


Figure 7. Panradiograph immediately following implant placement.

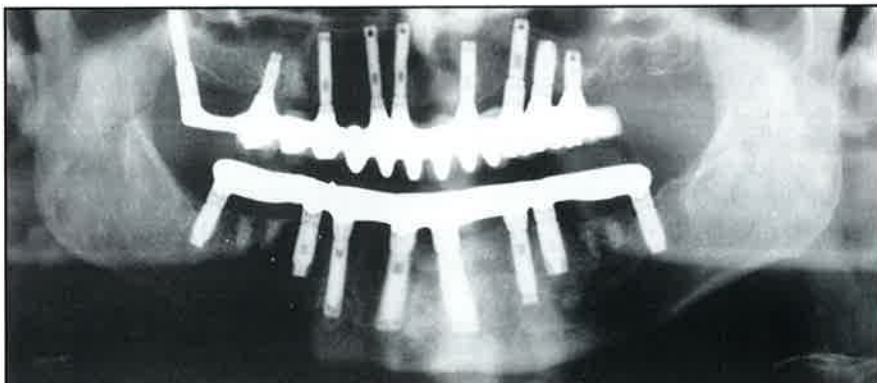


Figure 8. Final maxillary and mandibular implant supported bridge.

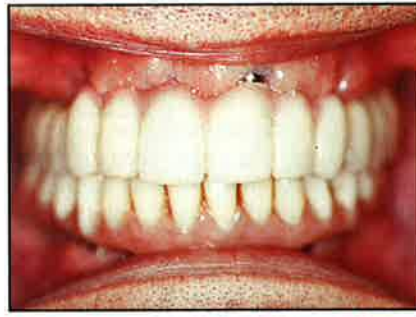

Figure 9. Facial view of final implant supported prosthesis.

tain bone levels through an internal bone remodeling stimulus. For young and middle aged individuals suffering from advanced periodontal disease, this factor addresses an important issue of long term bone maintenance. The removal of the natural dentition and subsequent elimination of the periodontal ligament in effect also eliminates all periodontal disease.

When considering this form of treatment, one should also note the technical complexity of providing extensive care. For busy patients, minimizing the number of treatment visits is an important issue. With proper technical support, tooth preparation, extraction of the hopeless teeth, fabri-

cation of the provisional restorations, stage I implant placement, and delivery of interim prosthetic restorations can be performed in one treatment session. The benefit of this form of patient management is extremely advantageous in reducing the number of visits required for total oral implant rehabilitation.

The greatest benefit of this treatment method is the tremendous psychologic advantage that is obvious with the final result. Patients who suffer from advanced periodontal disease are acutely aware of the mobility of their failing natural dentition. The stability of osseointegrated implant supported teeth is both uplifting and even invigorating as attested to by the proud, healthy and happy smiles (Fig 1).

References:

1. Balshi TJ, Wolfinger GJ. Conversion Prosthesis: A transitional Fixed Implant Supported Prosthesis For an Edentulous Arch. A Technical Note: *Int J Oral Maxillof Implants* 1996;11:92-97.

Health Media Watch

Medical costs related to cigarette smoking amounted to \$50 billion in 1993, according to a report in the *Journal of the American Medical Association*. The JAMA report is based on a data analysis conducted by the Centers for Disease Control and Prevention and the University of California. The findings in this report indicate that cigarette smoking accounts for a substantial and preventable portion of all medical-care costs in the United States.

The cost analysis does not include smoking-related medical expenditures for treating diseases caused by environmental exposure to cigarette smoke, time lost on the job, low infant birth weights linked to mothers who smoke and burn care for those injured in smoking-related fires. Factoring in these and other costs, CDS estimates that the total economic burden of cigarette smoking is more than twice as high as the direct medical costs described in its report.

JAMA 1994 272;6:428-9

Converting Patients with Periodontally Hopeless teeth to Osseointegration Prostheses

T.J. Balshi

The specialties of periodontics and prosthodontics have worked diligently to save dentitions suffering from advanced stages of periodontal disease. However, even when periodontal surgical therapy has been used to eliminate active acute and chronic disease processes, the mobility of the remaining dentition frequently requires prosthodontic splinting to create stability. In the past a prescription for conventional fixed prosthodontics was used for tooth replacement and to stabilize the mobile teeth. This report discusses and illustrates management of periodontally compromised dentitions using Brånemark implants to support a fixed prosthesis.

Three classifications of treatment for severely compromised periodontal dentitions are described. The class I method applies the traditional Brånemark protocol following the removal of all periodontally hopeless teeth; the class II modification of the Brånemark method splints periodontally mobile teeth to osseointegrated implants; and the class III modification converts the original removable denture into a transitional fixed implant prosthesis immediately following the placement of abutments at stage II surgery. The class III modification differs from the class II in that none of the natural abutment teeth remain as part of the final prosthesis. The patient never wears a removable prosthesis prior to delivery of the implant supported fixed prosthesis. The class III method maintains periodontally hopeless teeth to support a temporary nonremovable prosthesis which is suspended over the healing implant sites while the implants osseointegrate and the tissue heals. At stage II surgery the periodontally hopeless teeth are removed and the fixed prosthesis becomes totally implant supported.

Int J Periodontal & Rest Dent 1988; 2:9-33.

Tooth vs. Implant

S. Lewis

Attempts to save natural teeth have created numerous restorative, endodontic, and periodontal techniques. It has always been considered the treatment of choice to save teeth whenever possible. Often extreme efforts to save teeth would be considered because of the poor treatment alternatives for replacing them. In the past, dental implants such as blades or subperiosteals were considered a somewhat questionable approach to the replacement of missing teeth and were avoided by most practitioners. While procedures like hemisections and root amputations may have left teeth in somewhat guarded condition, they were still considered more predictable than most early implant techniques. Today, however, osseointegration provides a predictable means of replacing teeth, so that retaining questionable teeth may not be as necessary as in the past.

There are various situations where

the selective extraction of compromised natural teeth, or even healthy natural teeth, is considered because of the possibility of using alternative treatment options utilizing osseointegrated implants. While in some circumstances a tooth may be saved, in other clinical situations it might be more beneficial to extract a tooth in the exact same condition as the tooth saved in other situations. The extraction of a tooth, even a fairly healthy one, and the placement of an implant could lead to a more predictable, more definitive, and more cost effective solution for the patient. It should, therefore, be stated that the decision whether or not to save a tooth does not necessarily depend upon the health of the individual tooth, but rather on the overall rehabilitation being provided.

*Accepted for publication:
Int J Perio & Rest Dent, 1995*

Effect of Bruxism on Success Rate of Dental Implants

J. Yoon et al

The occlusal forces of bruxism damage teeth, periodontium and supporting bone. There is an additional problem when implants are present. With no ligamentous attachments between bone and implant, occlusal forces are transmitted directly to bone. The aim of this study was to determine whether dental implant and superstructure problems would be more frequent in bruxers than non-bruxers.

Forty-seven patients with implant prostheses were studied. Seventeen exhibited signs of bruxism, and 30 controls did not brux according to a bruxism questionnaire. The two groups were compared for pain, implant mobility, pocket depth, and problems with dental implants and prosthetic superstructures, such as implant abutment fracture, gold screw fracture and broken denture teeth.

Moderate to severe implant mobility was found in 18% of the bruxers but none in the implants of non-bruxers. A positive significant relationship was found between bruxism and problems with prosthetic superstructures. Seventy-six percent of the bruxism group versus 27% of the control group had superstructure problems. When pain, mobility, pocket depth and prosthetic problems were combined, 88% of the bruxers showed problems in the implant, interfacial tissue, and superstructures; while these problems occurred in only 27% of the controls.

Ten patients were selected at random from each group and fitted with occlusal mouthguards. The experimental subgroup showed significantly better results, including less tooth wear than the control group. The results indicate that bruxism reduces the success of implant therapy. Although it is not always possible to diagnose bruxism prior to treatment, providing occlusal mouthguards may improve success with bruxers.

J Dent Res 74 (IADR Abstracts) 1995



Maintenance procedures for the implant patient

Barbara J. Lord, RDH

The purpose of this article is to provide the dental staff, the hygienist and or the assistant with the basic understanding of the most current update on the comprehensive clinical examination, documentation and instrumentation of the dental implant and its components.

Although the primary issues in implant success are proper occlusal loading, prosthetic design and the distribution of the occlusal forces, one must also consider the importance of the maintenance of the implant soft and hard tissue environment.

Occlusal loading, or distribution of the biting forces, is essential and the primary concern in implant success. In order to maintain osseointegration the occlusal forces must be distributed equally so that one or more of the implants does not carry all of the occlusal load. The number

and location of implants has generally been predetermined for the edentulous mandible and maxillae. Further modifications of the basic design that take into account variations of quality and quantity of bone, the occlusal scheme, parafunctional habits, and various localized factors, have gradually developed with long-term clinical experience.

Understanding the implant environment and the rationale for impeccable bacterial control, along with the principles for assessing the prosthesis and surrounding tissue, may provide important information regarding the long term success of the implants.

The dental implant is surrounded by a soft tissue sulcus lined with crevicular epithelium and is attached by a hemidesomal arrangement. An underlying dense circular band of collagen fibers function as a biological seal or barrier to the external environment and oral microbiota. As described by Albrektsson and Zarb (1989), the junctional epithelium which provides a mucosal seal around an implant is not reflected by the physical strength of its attachment. The junctional epithelium ensures the continuity of the mucosal

epithelium and maintains the epithelial barrier. Peri-implant pathology which may lead to subsequent implant failure should be considered along with plaque and calculus indices.

The primary objective of the clinical maintenance visit is the removal of all hard and soft deposits with minimal or no alteration to the titanium abutment surface. A roughened abutment surface will encourage the formation of plaque and calculus. This is especially important in the subgingival area, where metallic contamination may be a factor after osseointegration has taken place (Newman and Fleming 1989). This is done with plastic scalers that come in a variety of shapes and designs.

There are numerous home care techniques available for the implant patient- from the basic toothbrush to the specifically designed implant floss.

The trained dental hygienist and or auxiliary can be instrumental in maximizing the compliance, motivation and education of the patient as it relates to maintenance of the dental implant.

Australian Prosthodontic Journal 1995;9 (Suppl)

The Successful Use of Osseointegrated Implants for the Treatment of the Recalcitrant Periodontal Patient

M. Nevins, B. Langer

The object of this retrospective and ongoing study was to measure the efficacy of using implants for the treatment of those patients where traditional periodontal treatment had been unsuccessful. In the past, these patients were not considered good candidates for endosseous implants because of their history of uncontrolled bone loss and the likelihood that such bone loss would continue. Because they have already invested time, finances, and emotion in efforts to unsuccessfully maintain their teeth, it is not unusual for them to resist the suggestion of implants.

The authors report the successful use of osseointegrated implants to replace teeth in patients whose periodontal disease had been categorized as recalcitrant. The study involved 59 partially or totally edentulous patients in which 309 implants were placed between 1985 and 1992. Of the 132 mandibular implants, 4 failed, for a success rate of 97%; and 3 of the 177 maxillary implants failed, for a success rate of 98%. The report included 42 mandibular and 50 maxillary prostheses, none of which failed. The results of this study compares favorably to the previous

accounts of osseointegrated implants placed in both edentulous and partially edentulous patients. Although it represents a small patient population, this study is a reflection of the small percentage of recalcitrant patients seen in a contemporary private periodontal practice and reasonably tests the hypothesis that implants will outperform problematic teeth in the recalcitrant patient population.

Because of their past history of traditional periodontal therapy, the majority of the patients in the study strictly complied with periodontal maintenance procedures after implant and prosthesis placement. These results indicate that individuals with a strong susceptibility to periodontal disease can be treated successfully with osseointegrated implants.

J Periodontol 1995;66:150-157

Treatment outcomes in implant therapy: The influence of surgical and prosthodontic experience

Preiskel H, Tsolka P

Operator's experience appears to be one important factor influencing the success of implant prosthodontics. The aspect of improved performance with experience was addressed in a recent international study, indicating better clinical results than those previously reported. This was attributed to the operator's improved efficiency and the opportunity to build on the long-term experience of the early studies, thereby avoiding certain causes of early failure.

This retrospective study reviews 30 months of treatment with 53 partially or completely edentulous patients provided with implant supported restorations. The restorative aspects of therapy were undertaken by experienced prosthodontists who had just begun implant rehabilitation techniques. Patients were treated in two centers, 21 in a major teaching institution (Group A) and 32 in a private practice (Group B). In Group A, the implants were placed by experienced surgeons who were just beginning involvement in implant techniques; while the patients in Group B had implants placed by surgeons having a minimum of 2 years implant experience. Implants were placed according to the Brånemark protocol.

The results indicated that the sur-

geon's level of experience had a major impact on the failure probability of unloaded implants. Loading conditions and the design of the prosthesis may be the decisive determinants for the probability of success with loaded implants. Prosthodontic protocol was similar to those normally used with the Brånemark System.

It might be tempting to suggest that the surgeon's experience would only apply to results before the loading of the implants. It is likely, however, that implant positioning, angulation, and

technique will affect the result for the entire life-span of the restoration. It is also acknowledged that increased experience might have caused the operator to adopt a more selective approach toward prosthodontic solutions.

The results of this study indicate that those entering the field of implant prosthodontics cannot expect their early work to match the success rates obtained from established centers.

Int J Prosthodont 1995;8:273-279

UNIQUE TRAINING OPPORTUNITIES

Group and individual observation courses and/or participation and hands-on programs in the Brånemark System are available at Prosthodontics Intermedica, sponsored by the Institute for Facial Esthetics and Nobelpharma USA Inc.

Call Liz Kirk for information & brochure:
Next course date:

(215) 643-5881
February 12-14, 1996.

WE'RE GETTING CONNECTED? ARE YOU? *Our Home Page is Coming Soon*


Prosthodontics Intermedica is in the process of creating a home page on the internet to provide dental professionals and the general public with information and news on state of the art implant dentistry. It will be best viewed within Netscape.

We Encourage Your Feedback! Use e-mail or fax to tell us about yourself:

- Do you have access to the internet?
- What service do you use? (i.e. - CompuServe, America Online, Prodigy, or a direct internet access provider)
- What is your e-mail address?
- Do you have a home page?
- What would you like to see on our home page?

E-mail: PITEAM@aol.com

Fax: (215) 643-1149



What do you tell your patients when they ask what they should eat after surgery and throughout treatment?

From Soup to Nuts

Originally conceived as a cookbook for dental patients embarking on implant reconstruction, FROM SOUP TO NUTS introduces gourmet anticipations for the most compromised eater, as well as a wide range of delicious novelties that eventually challenge the most securely implanted permanent teeth.

An ideal gift to help motivate a patient considering dental implants, for a patient recovering from a dental or surgical procedure, for a confirmed denture wearer, or for any person requiring a careful diet, FROM SOUP TO NUTS is the prescription for the flavors that accompany a bright healthy smile. It's just what the doctor ordered!

To order your cookbook: 215-643-5881 Cost: \$14.95
Doctors Cost: \$12.95

PROSTHODONTIC *Insights*

is published by Prosthodontics Intermedica and distributed without charge to qualified individuals. Please request a subscription on your organization's letterhead.



*Fixed, Removable, Maxillofacial
and Implant Prosthodontics*

Prosthodontics Intermedica
467 Pennsylvania Avenue, Suite 201
Fort Washington, PA 19034 U.S.A.
Tel: 215-646-6334
Fax: 215-643-1149