

Zygoma Fixtures Used To Correct Congenital Deformity: Treatment Of A 20 Year Old Male



Glenn J. Wolfinger, DMD, FACP Thomas J. Balshi, DDS, FACP

Congenital Anomalies are a broad category of health conditions that are present at birth and are a deviation from normal anatomic growth, development, or function. The congenital anomaly develops in utero or may have genetic origins.

Ectodermal Dysplasia is a congenital anomaly caused by a single abnormal gene or pair of abnormal genes. In congenital ectodermal dysplasia, teeth are absent at birth, reduced in number, or conical in appearance so that partial dentures are required from childhood. The birth prevalence of ectodermal dysplasia is approximately 1 in 100,000 and is known to be hereditary in nature.

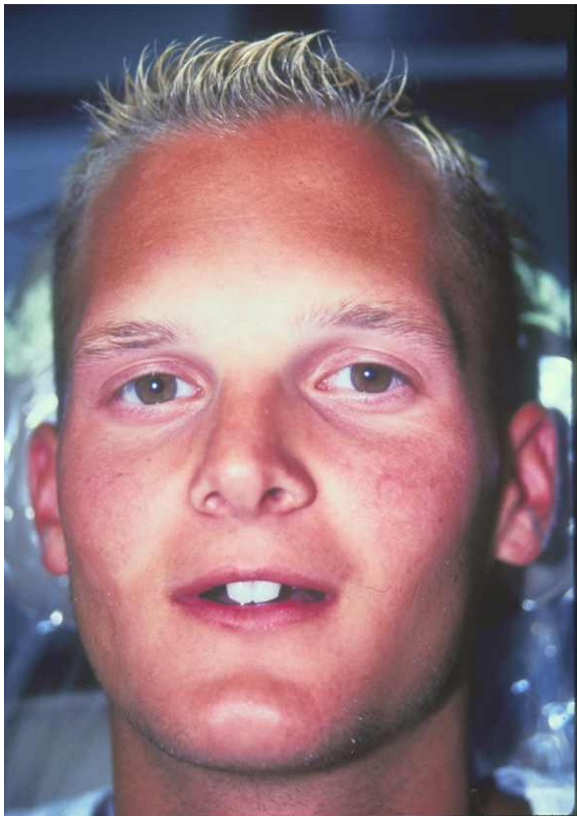

Figure 1: Full face frontal smiling (laughing) view illustrates a narrow lower third of the face.



Figure 1B: Post treatment full face smile with a fully functional and esthetic implant reconstruction. (Continued on page 2)

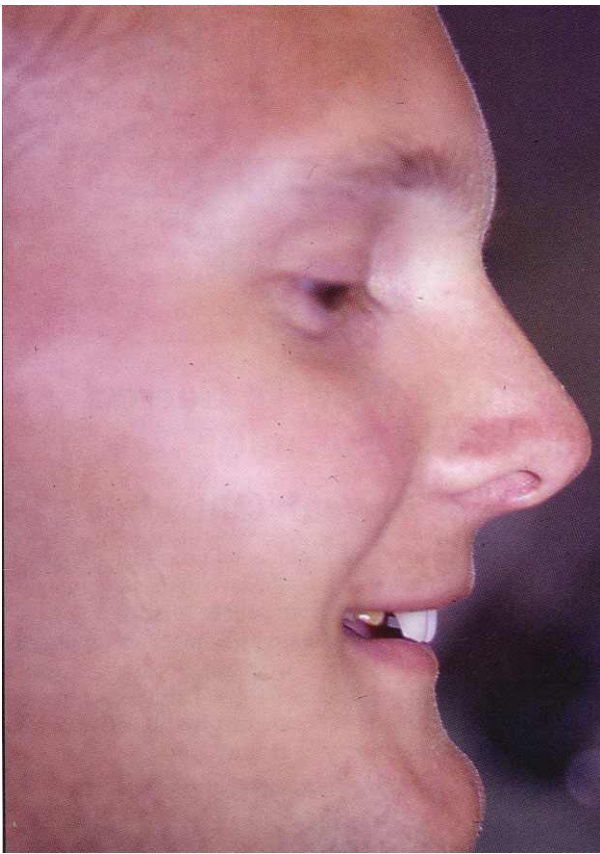

Figure 2: Preoperative profile demonstrates the bimaxillary hypoplasia and a retrognathic appearance.

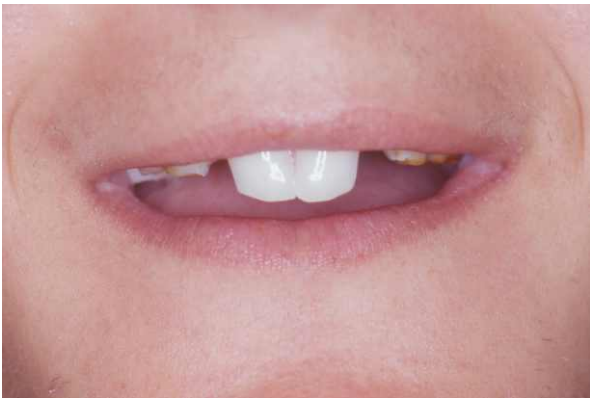

Figure 3A: Preoperative view showing poor esthetics.

Ectodermal dysplasia may present in various degrees of severity, ranging from a slight malformation of the coronal portion of a single tooth, to the more commonly recognized "congenitally missing lateral incisors", or the advanced presentation of the syndrome with multiple missing teeth, thinning or absence of facial hair, and reduction of sweat glands. Congenital deformities in the craniofacial region are physically and psychologically devastating and can handicap the individual in many ways. In young adults these anomalies can have a great impact on the psycho-social component of life.

Since ectodermal dysplasia is often accompanied by loss of adult teeth, it can also lead to underdevelopment of the jaws. A hypoplastic maxilla and mandible, having little if any dental support, produces bite collapse and narrowing of the alveolar ridges. This condition produces a diminished appearance of the lower third of the face. The reduction in size of the width of the jaws and supporting musculature is distractingly apparent in full face frontal view (Fig 1a). In profile, the underdeveloped jaws create a facial disharmony due to a retrognathic appearance (Fig 2).

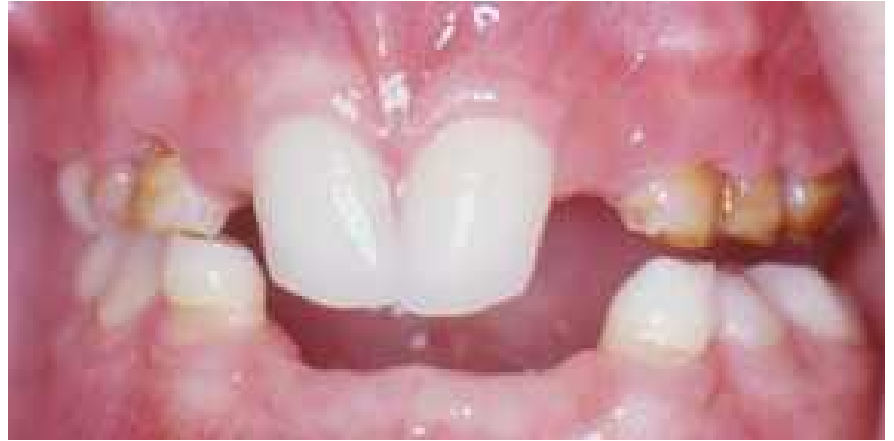

Figure 3B: Preoperative condition: adult malformed incisors and residual primary dentition.

In modern society, young adults, who have their entire business and social life ahead of them, are most likely to be affected by the psychological implications of esthetic deformities. The psycho-social peer pressure to have a beautiful or handsome appearance also weighs heavy in the academic environment. A distracting appearance due to congenital defects may inhibit normal social interactions and can subconsciously create a negative impact on academic performance.

Oral facial rehabilitation of young adults afflicted with severe Ectodermal Dysplasia can be successfully accomplished using modern treatment concepts. These concepts may include osseointegrated dental titanium implants to support non-removable teeth, bone grafting and tissue engineering, together with advanced esthetic prosthodontic artistry to create natural looking replacement teeth and an esthetically pleasing smile.

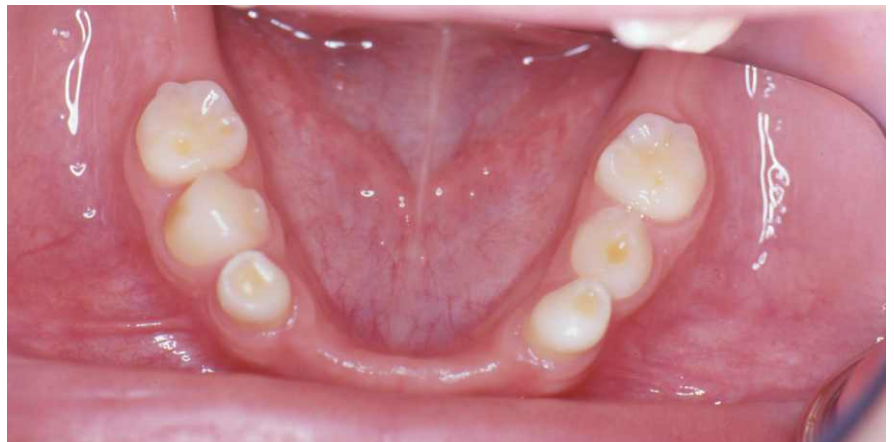

Figure 3C: Preoperative mandibular arch with six primary teeth.

The clinical treatment of a 20-year-old male is presented to illustrate the biomechanical and esthetic advantages of modern prosthodontic oral facial rehabilitation. It is of clinical interest, that the patient's 22 year old sister also suffered from Ectodermal Dysplasia. Her reconstructive treatment consisted of surgical intervention with an iliac crest bone transplant inlayed into the maxillary antrum. Subsequent degeneration of the graft required complex retreatment seven years later.

(Continued on page 3)

Treatment planning this young man's reconstruction illustrated a major change in prosthodontic philosophy and technology by being able to minimize the invasive nature of the reconstructive surgery. New and specially designed zygoma fixtures permitted a non-removable prosthodontic reconstruction by placing

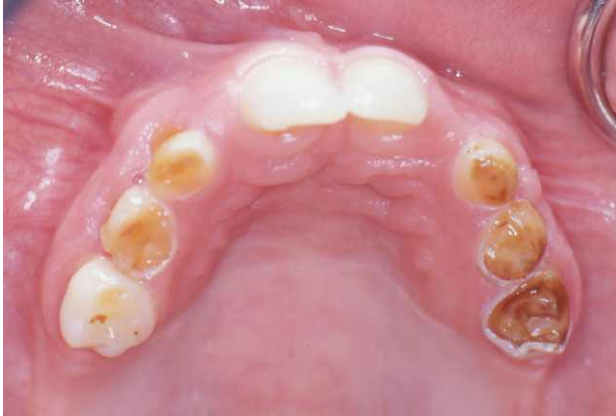

Figure 3D: Preoperative maxilla with severely carious posterior teeth serving as overdenture support.

implants into the zygoma bone to provide posterior support for a complete maxillary arch reconstruction. This treatment approach avoided the hospital visit generally required for an iliac crest transplant, it reduced the total amount of treatment time by eliminating the ten to twelve months usually required for bone grafts to mature before implants can be placed, and negated the necessity of additional healing time required for implants placed in grafted bone.

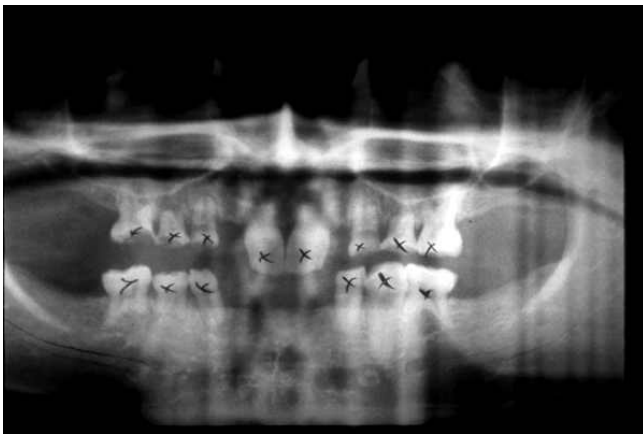


Figure 4A: Preoperative panoramic radiograph with deteriorating primary dentition and no subsequent adult dentition, except for the malformed maxillary centrals.

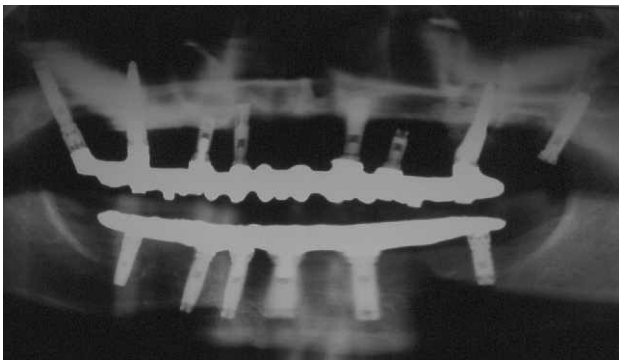


Figure 5A: Postoperative panoramic radiograph

As reported in the literature, implants placed in the maxilla in grafted bone may only be as high as 90% . Whereas, initial studies on zygoma fixtures conducted by Per Ingvar Branemark, et al, revealed a 96.8% clinical survival rate to date .

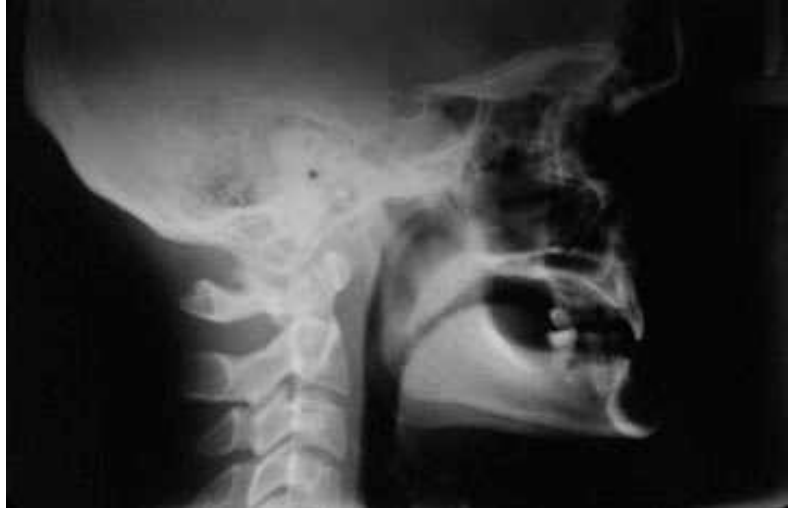

Figure 4B: Preoperative lateral cephalometric radiograph shows severe collapse of vertical dimension of occlusion.

This otherwise healthy ectodermal dysplasia patient initially presented with only two adult maxillary teeth, the central incisors (Fig 3a). Also present were six maxillary primary posterior teeth,

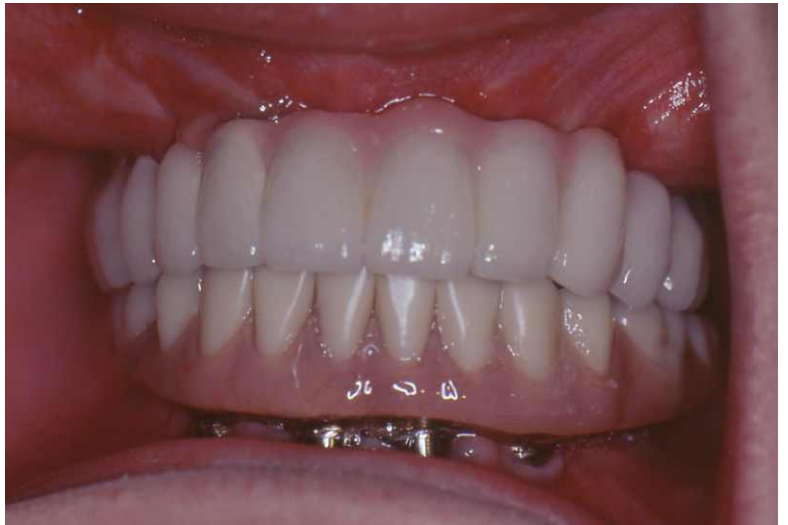

Figure 6: Postoperative intraoral frontal view.

six mandibular primary teeth, the canines, and both molars (fig 3b,c,d).

In order to appear in public the patient was using an all acrylic maxillary overdenture which overlaid his severely deteriorated posterior dentition, and an acrylic removable partial denture replacing the mandibular anterior teeth. Both of these "temporary" restorations were constructed at his existing decreased vertical dimension of occlusion.

After performing a comprehensive clinical and radiographic evaluation (Fig. 4a & b), a treatment plan was discussed with both the patient and his parents. This comprehensive plan recommended the removal of all the patient's remaining teeth, both adult and primary, and simultaneous surgical placement of Branemark titanium dental implants. The decision to proceed with treatment was made only after discussing and rejecting several

(Continued on page 4)

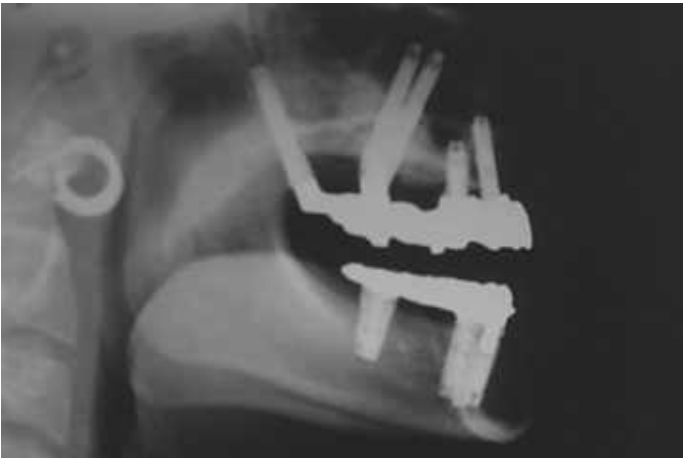

Figure 6: Postoperative lateral cephalometric view

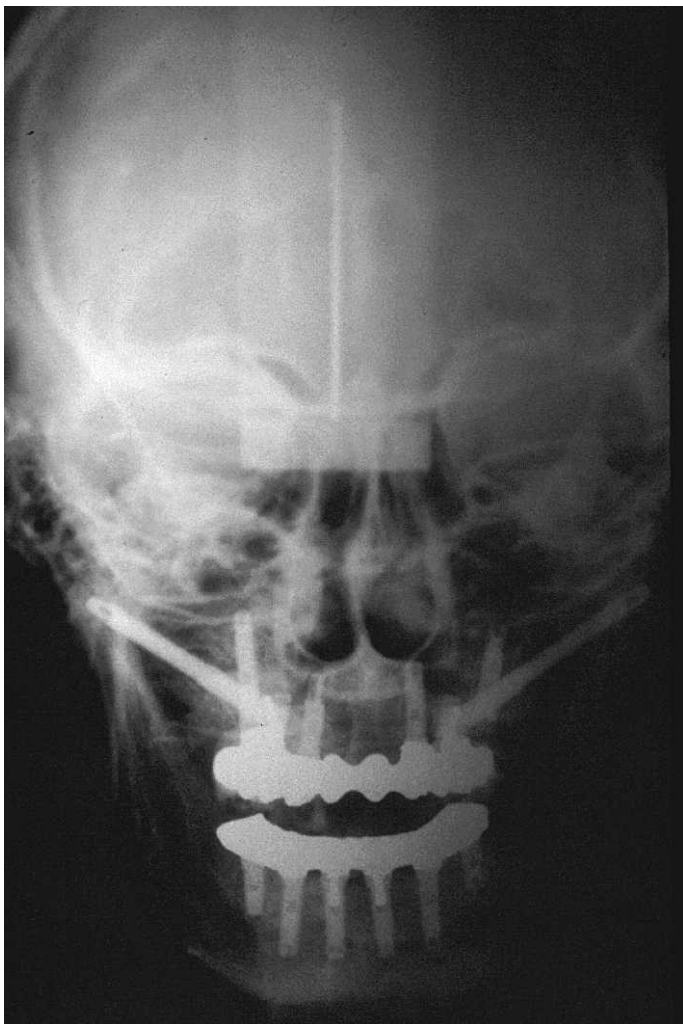


Figure 5B: Postoperative intraoral frontal radiograph

out patient setting, the remaining natural teeth were removed and six Branemark implants were placed in the mandible. All bone from the implant osteotomy sites was harvested for possible future use in the maxilla. Cover screws were placed over the implants and the site was thoroughly irrigated and sutured closed. The maxilla was operated with bilateral antral openings which created directional visibility for placement of the zygoma fixtures. Four additional implants were placed in the anterior maxilla and one in each pterygomaxillary area. Autogenous bone, harvested from the implant osteotomy sites, and a natural bovine derived bone substitute was combined with a platelet rich plasma gel treated to release growth factors. This graft material was placed in the antral floor of the maxilla and around the zygoma fixtures to increase the bone to implant surface area.

Post operatively the patient used a standard regime of medications and cold therapy for the first 48 hours to minimize swelling and post surgical discomfort. The sutures were removed ten days after the surgery and a soft lining was applied to the temporary removable complete dentures. Healing continued uneventfully for three months. The mandibular second stage surgery was completed in the normal fashion and a traditional implant supported fixed prosthesis was constructed with appropriate arch form and vertical dimension.

Second stage surgery was completed for the maxilla five months after the implants were placed. Angulated abutments were used with each zygoma fixture to angle the prosthetic retaining screw toward the occlusal table. One pterygomaxillary implant was not utilized to support the prosthetic reconstruction due to sensitivity, despite the fact that it was clinically immobile (Fig 5a,b,c). The final porcelain fused to gold fixed prosthesis was constructed to fill the labial and buccal spaces which had been void due to underdevelopment of the maxilla (Fig 6). A positive smile line complimented the patients lip line (Fig 1b).

The patient will continue treatment with oral hygiene visits scheduled every three months during the first year, every four months the second post operative year, and then every six months thereafter.

In summary, the treatment of a young man, born without many of his "permanent" adult teeth was successfully restored to complete function and esthetics using special zygoma fixtures. The esthetic beauty of this treatment is clinically enhanced by the brevity of the treatment process. Eliminating the need for extreme bone grafting substantially shortens the overall treatment experience and improves the predictability of success.

Authors note: For more information on sinus augmentation for implant reconstruction, refer to *Prosthodontic Insights*, February 1997, Vol. 10, No. 1.

Acknowledgments:

Robert Winkelman, CDT, MDT, Owner

Fort Washington Dental Lab, Inc.

Tel: 1-800-541-3490

215-628-4994

Email: fortwdental@aol.com

Web site: <http://ftwashingtondentallab.com>

References:

Jensen OT, Shulman LB, Block MS, Iacono VJ. Report of the Sinus Consensus Conference of 1996. *Int J Oral Maxillofac Implants* 1998;13(supplement)
Darle C. A New Procedure for Rehabilitating the Severely Resorbed Maxilla. *Talk of the Times*, 1999 Nobel Biocare SE

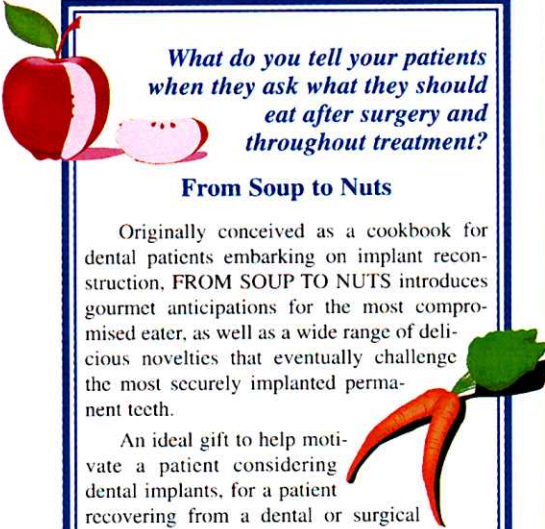
treatment alternatives which included iliac crest bone grafting and long term using a complete removable prosthesis. The patient had a strong desire to avoid the removable prostheses and wanted to be restored with fully functional dentition that was not removable. Under medically monitored general anesthesia, in an

(Continued on page 5)

Report of the Sinus Consensus Conference of 1996

Jensen, Shulman, Block and Iacono Retrospective data from the sinus floor augmentation bone grafts were collected from 38 surgeons for 1007 sinus grafts that involved the placement of 2997 implants over a 10-year period, with the majority of the implants followed for 3 years or more postrestoration. There were 229 implant failures reported. Various root-form implants and grafting modalities were used. A consensus conference was organized to evaluate the data and reach a consensus on optimal treatment protocols. The complete database demonstrated a 90.0% success rate for implants placed in sinus grafts with at least 3 years of function. Differences in grafting materials, implant surfaces, and timing protocols were statistically analyzed. However, the database was so multivariate and multifactorial that it was difficult to draw definitive conclusions; these must await controlled prospective studies.

Int J Oral Maxillofac Implants 1998;13(supplement)



What do you tell your patients when they ask what they should eat after surgery and throughout treatment?

From Soup to Nuts

Originally conceived as a cookbook for dental patients embarking on implant reconstruction, FROM SOUP TO NUTS introduces gourmet anticipations for the most compromised eater, as well as a wide range of delicious novelties that eventually challenge the most securely implanted permanent teeth.

An ideal gift to help motivate a patient considering dental implants, for a patient recovering from a dental or surgical procedure, for a confirmed denture wearer, or for any person requiring a careful diet, FROM SOUP TO NUTS is the prescription for the flavors that accompany a bright healthy smile. It's just what the doctor ordered!

To order your cookbook: 215-643-5118
Cost: \$14.95

PROSTHODONTIC — Insights —

A Regular Member of the American College of Prosthodontics

is published by Prosthodontics Intermedica and distributed without charge to qualified individuals. Please request a subscription on your organization's letterhead.



*Fixed, Removable, Maxillofacial
and Implant Prosthodontics*

Prosthodontics Intermedica
467 Pennsylvania Avenue, Suite 201
Fort Washington, PA 19034 U.S.A.
Tel: 215-646-6334
Fax: 215-643-1149

The Institute For Facial Esthetics presents

Surgical and Prosthetic Implant Training: A 3-Day Program

Featuring the Brånemark System

Course Dates:

October 16, 17, 18, 2000
January 8, 9, 10, 2001

Time: 8:00-6:00 PM

Tuition: \$1,800.00 General dentists &
Specialists (must provide copy of dental degree)

Location: Fort Washington, Pennsylvania

Presenters: Thomas J. Balshi, DDS, FACP, Board Certified Prosthodontist
Glenn J. Wolfinger, DMD, FACP, Board Certified Prosthodontist
Robert Winkelman, CDT, MDT, Master Dental Technician

Continuing Education: Twenty-four hours of Continuing Education will be provided. This course is sponsored by The Institute For Facial Esthetics.

For more information or to register: call 215-643-5881 or fax 215-643-1149. Course is limited to six participants.

Educational Objectives: To teach and demonstrate the effect of osseointegrated dental implants on facial esthetics and general patient well being; To provide clinical instruction and hands-on implant training; To provide clinical patient management before, during and after dental implant rehabilitation; to provide post-prosthesis maintenance via home and professional oral hygiene.

Course Content: This 3-day program includes fundamentals of implant surgery and prosthetics, as well as patient selection, treatment planning, general requirements, draping and anesthesia, evaluation of implant sites, bone preservation, site preparation, implant placement, surgical closure, abutment connection and loading of implants, patient instructions, oral hygiene, post-prosthesis maintenance. Special considerations include graft areas, anatomic defects, immediate extraction sites, delayed extraction sites. Complications will be presented as well as methods of preventing and solving problems.

Teaching Methods: Lectures, slides, video's, hands-on surgical & prosthetic training on models, observation of live surgeries and prosthetic procedures. All clinical treatment is performed by Drs. Balshi and Wolfinger, State licensed prosthodontists at Prosthodontics Intermedica.

Seminar includes: Certificate of attendance, course materials, lunch and refreshments.

The Institute For Facial Esthetics is an



The Institute For Facial Esthetics reserves the right to cancel the course at any time with no responsibility other than full refund of tuition paid. No refunds for cancellations made within 48 hours of the course.

(Continued on page 6)

Analysis of 356 Pterygomaxillary Implants in Edentulous Arches for Fixed Prosthesis Anchorage

TJ Balshi, GJ Wolfinger, SF Balshi II

One thousand eight hundred seventeen implants were placed in the completely edentulous maxillae of 189 patients (122 female; 67 male). The patients' mean age was 60 years (range 28 to 91 years). Three hundred fifty-six of the 1,817 implants were placed in the pterygomaxillary area and all patients were restored with complete arch fixed detachable prostheses. The mean number of implants per maxillary prosthesis was 9.0 (range 6 to 15). During stage II surgery and before loading, 41 pterygomaxillary implants (11.5%) were not osseointegrated and were removed. After a mean loading period of 4.68 years (range 0.06 to 9.2 years), 1 additional pterygomaxillary implant was lost. Altogether, 42 of 356 pterygomaxillary implants (11.8%) were removed. Survival rates according to implant size, bone quality, and tooth position were also

recorded. This study illustrates a cumulative survival rate of 88.2% after an average functional period of 4.68 years for pterygomaxillary site implant placement in edentulous maxillary arches.

The 88.2% cumulative survival rate of pterygomaxillary implants compares favorably with implants used in other areas of the maxilla, despite the compromised quality of bone and increased potential for force exerted on implants placed in the posterior maxilla. Implants placed in the pterygomaxillary region provide posterior bone support without sinus augmentation or supplemental grafting.

Pterygomaxillary implants are beneficial in restoring the entire maxillary arch with a prosthesis that is biomechanically stable and free of cantilevered pontics.

Int J Oral Maxillofacial Implants 1999;14:398-406

A New Procedure For Rehabilitating the Severely Resorbed Maxilla

by Christina Darle

Professor Brånemark and his team have developed a dental implant for placement in the Zygoma region. The first implant was placed in 1989 and since that time, 81 patients have been treated with a 96.8% success rate. The incidence of implant loss in the severely resorbed posterior maxilla is around 15% with the benefit of a sinus graft. Current treatment modalities aimed at reducing implant loss in these patients frequently involved different types of grafting procedures. These procedures vary extensively and involve everything from using allografts, alloplasts, and xenograft materials to harvest bone matrix from the patient's chin, hip, tibia or calvarium. Membranes are recommended by some, but not by others. Most studies involve limited patient material and applied procedures and used materials differ more than they correspond. There is a lack of consensus on all specifics relating to the procedure of grafting the severely resorbed posterior maxilla. The lack of consensus was recognized by the dental community in a Consensus conference on sinus grafts conducted in 1996. The fact that it took two years to finalize the results clarifies the difficulties described above. The main conclusion from the conference was that "The material was so multivariate and multifactorial that it was difficult to draw definite conclusions, these must await controlled perspective studies."

While alternate procedures were being explored, Professor Brånemark once more applied his lateral and uninhibited thinking in an attempt to answer the basic question "How can we, in a simpler, safer and higher predictable manner, restore function to those patients who have so severely resorbed jaws that standard implants are bound to provide unacceptable results?"

Extensive studies were done evaluating the craniofacial bone and its load bearing capacity. It was found that in close proximity to the defect area, the os zygoma consistently demonstrated dense bone quality and acceptable bone volume. This bone is similar to the dense type bone which we already know provides the most predictable anchorage in the mandible. Brånemark believed that this would be a significant improvement compared to conducting extensive grafting procedures.

Professor Brånemark's team then designed the zygoma fixture and the first patient was treated in 1989 at which time the clinical follow-up began. To date Professor Brånemark has treated 81 patients with fixtures in the zygoma region, including 24 maxillectomies, and 3 cleft defects. A total of 164 fixtures have been placed, of which 24 were (regular type fixtures) ranging in length from 13 - 30 mm, and 140 were specifically designed zygoma fixtures. Five of these were placed in four partially edentulous patients. The follow-up ranges from 0 - 10 years as follows: 10 years - 5 fixtures; 5 to 9 years - 54 fixtures; less than 5 years - 105 fixtures. No fixtures failed in the maxillectomy or cleft patients. After successfully treating maxillectomy and cleft patients, the procedure was developed also for non-defect sites pertaining to the severely resorbed posterior maxilla. To date, the overall success rate for this new fixtures is 96.8% and it has been estimated that the need for grafting is reduced by approximately 75% with this technique. A multicenter study was initiated in 1998 and 50 patients have been treated to date. The study will run for five years.

Talk of the Times, Nobel Biocare SE, 1999. Article #26577

References:

Brånemark PI, Svensen B, Van Steenberghe D. Ten year survival rates of fixed prosthesis on four of six implants ad modum Brånemark in full edentulism. *Clin Oral Implants Res* 1995;6:227-31

Jensen OT, Shulman, LB, Block MS, Iacono VJ. Report of the sinus consensus conference of 1996. *Int J Oral Maxillofac Implants* 1998;13 (supplement)