



Glenn J. Wolfinger,
DMD, FACP

Ultimate Smile Makeover TEETH IN A DAY™



Thomas J. Balshi,
DDS, FACP

Facial esthetics and self-esteem are important attributes in a society that puts a high value on appearance and poise. Successful communication at the family, community and business level requires face-to-face interaction. Key elements to this interaction are the mouth and the smile. Because a primary mode of this form of contact is speech, the mouth draws special attention during conversation.

A healthy, bright and attractive smile is a welcoming invitation to happy and stress free conversation. The opposite is true with oral debilitation. Decayed and missing teeth are visible deterrents when focusing on

important personal or business communication. Unattractive

odors that accompany poor oral health.



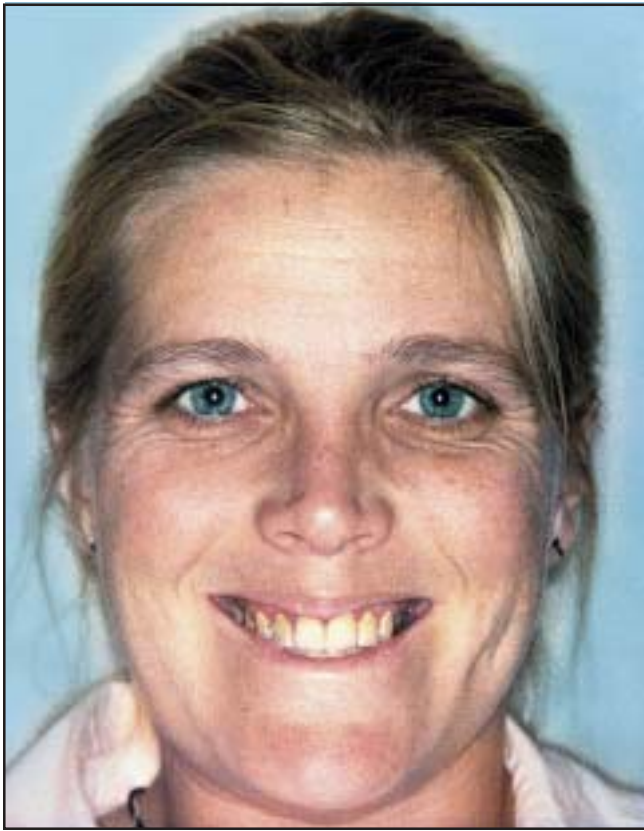TEETH IN A DAY™ for Megan is endorsed by a happy smile and positive self esteem.

teeth, typically those that are cracked, misshaped or dark with decay, exposing old black “fillings” may subconsciously lower the value of a particular interaction, and often create offensive mouth

The position of the teeth in the jaw plays a major role in the appearance of the smile. Narrow arches or missing molars can create black triangles between the corner of the lips when laughing or smiling. These dark corners serve as unattractive focal points.

When extensive debilitation is present, traditional dental restoration may be either ineffective for the long-term or very costly in time, finances and patient comfort. The time and cost alone for one arch of 14 teeth that requires endodontic therapy, post and core restoration,

A healthy, bright and attractive smile is a welcoming invitation to happy and stress free conversation.



Before treatment smile with unattractive black triangles at the corner of the mouth.



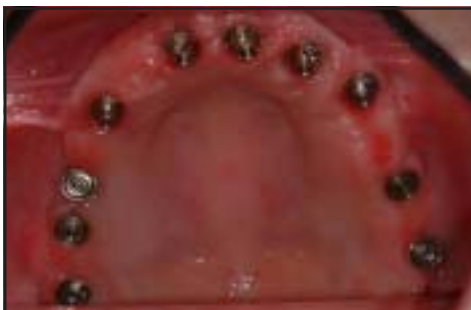After Teeth In A Day™ treatment patient exhibits a full smile filling the entire smile line.

ceramic or ceramometal crowns, possible periodontal surgery, and perhaps extensive orthodontic treatment is expensive, and the longevity of teeth weakened with root canals and posts is minimal. Periodontal response to extensive restorative treatment is also a consideration.

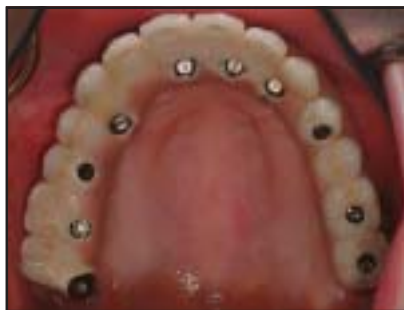The diagnosis of advanced oral debilitation with many of these conditions indicates that dental implant treatment is an ideal solution. The following is a clinical report of a 31 year-old mother who used the Internet to find solutions for her debilitated dental condition, which affected

her general health and self esteem. Megan presented with wide spread decay, severe bad breath, bleeding gums, and fractured and missing teeth. Her poor esthetics and bad breath led to psychological and emotional issues preventing her from effective social interaction and job security. Because of her

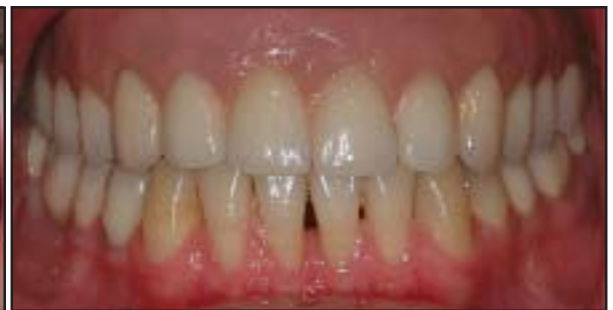The poor esthetics and bad breath led to psychological and emotional issues preventing her from effective social interaction and job security.



Healed maxilla with abutments positioned.

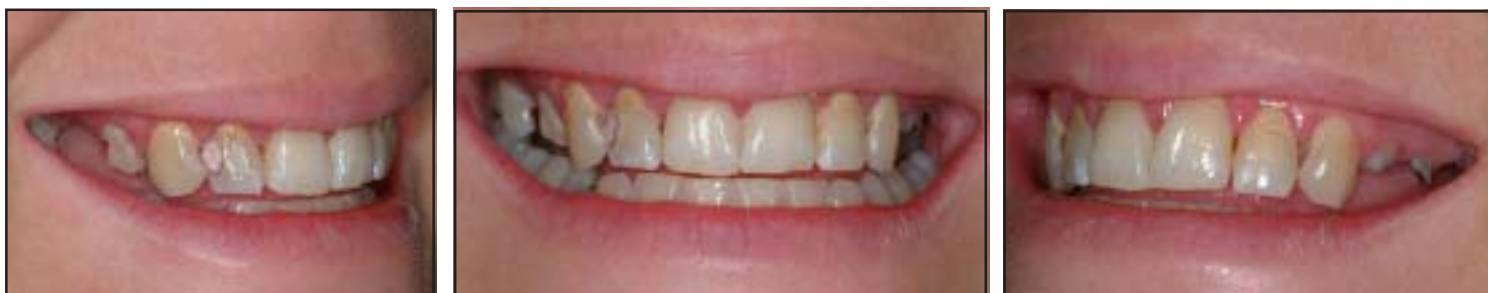

Final porcelain / gold upper teeth



Front view of upper Teeth In A Day™ fixed prosthesis

The maxillary arch was restored using the **TEETH IN A DAY™** protocol immediately following extraction of the severely decayed teeth.



Before treatment front views demonstrate severe decay and missing teeth.

extensive dental debilitation, the patient's Chicago area dentist suggested full mouth extractions and the construction of upper and lower dentures. Megan became even more emotionally distressed at the thought of wearing dentures for the rest of her life.

At Prosthodontics Intermedica in Fort Washington, a comprehensive evaluation of her medical and dental history was undertaken. Clinical and radiographic evaluation was performed and the treatment options for improving her smile and chewing ability were discussed. Megan was very excited about the prospects of having permanent teeth. The treatment plan recommended extraction of all of the maxillary teeth with the

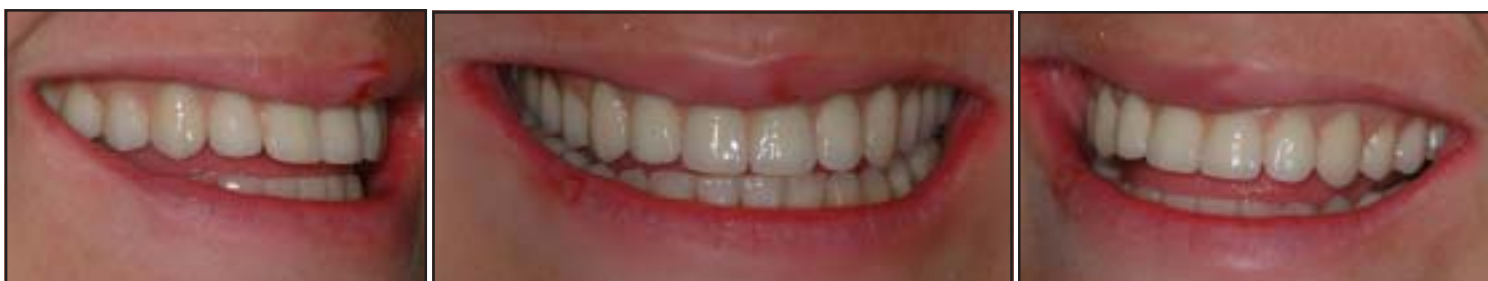placement of implants to immediately support a complete maxillary implant reconstruction.

The mandibular posterior teeth were in need of treatment as well. The lower right first molar needed to be extracted and that tooth was replaced with a traditional 3-unit fixed bridge. Four other mandibular posterior teeth were restored using conventional crown and bridge. Two molars needed endodontic therapy.

While Megan was asleep, the maxillary arch was restored using the TEETH IN A DAY™ protocol immediately following extraction of the severely decayed teeth. Ten implants were placed and a fixed interim acrylic prosthesis was

fabricated immediately following surgery. The patient functioned with this restoration for five months, until the final porcelain fused to gold reconstruction was fabricated and delivered.

To enhance the thrill of new teeth, Megan had two separate days of beauty treatment; one following the stage one surgery and one following delivery of the final prosthesis. The beauty treatment included a haircut, styling, makeup, a manicure and consultation designed to renew her appearance and self-esteem. The complete makeover is the wave of the future. The American Society for Aesthetic Plastic Surgery predicts that in 2004 most post-surgical patients will be referred for make-up, hairstyling, and cosmetic



After Teeth In A Day™ treatment, a healthy smile with bright teeth.



Megan enjoys the Phillies at Veteran's Stadium the day after Teeth In A Day™ surgery.

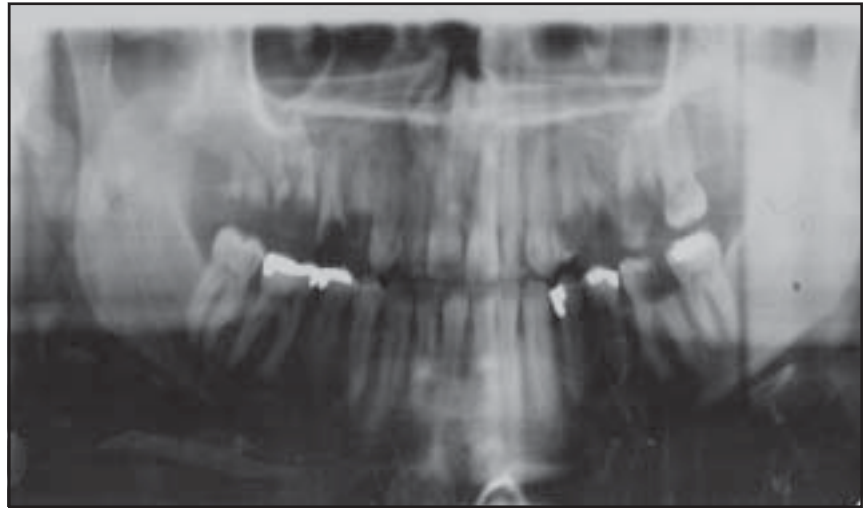dentistry.

The TEETH IN A DAY™ treatment cured Megan's bad breath, eliminated her pain, and replaced her unattractive teeth with a charming smile, completely infection free and totally functional. The enormous improvements in her chewing ability resulted in better nutrition and vastly improved her systemic health.

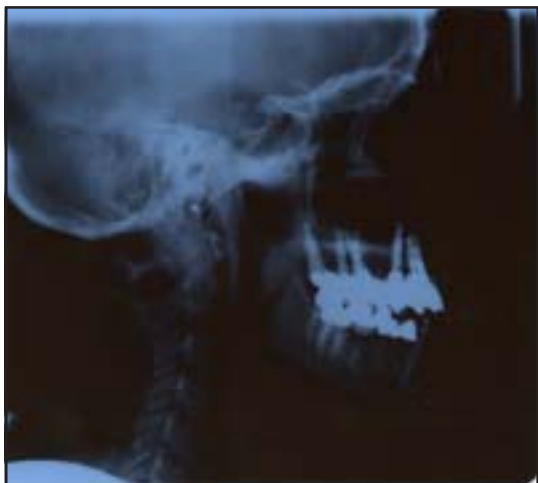
While the esthetic issues were the driving force for this patient, health and function were the prime objectives of the treatment presented. Megan's restored self esteem has enabled her to go for a job interview without having to be concerned about her appearance or offensive mouth odors.

Acknowledgments:

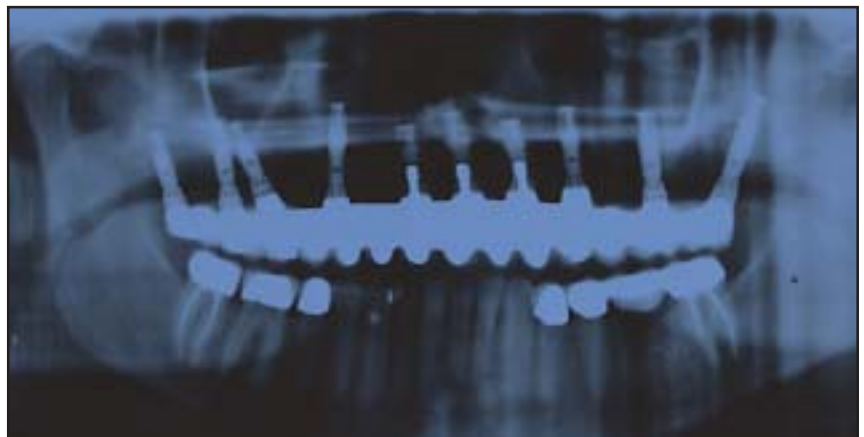
- Bob Winkelman, Fort Washington Dental Lab
- James Williams, CDT and Antoinette Washington, Dental Technicians at Prosthodontics Intermedica
- The clinical and administrative team at "PI"
- Joanne Balshi, Prosthodontics Intermedica Foundation
- Stephen F. Balshi, BBE - BioMedical Engineer and Prosthodontics Intermedica Research Team
- Support of Nobel Biocare, the Brånemark System and special thanks to President, Marty Dymek, Dr. Tom Reddy, Karen Fredericks, Ron Dove, Jane Trioani
- Susan Wolfinger for artistic contributions in hair style and make up
- Megan's sister, Amanda, who accompanied her and calmed her initial anxieties
- Anesticare Anesthesia Services, Inc. for their gentle and caring treatment.
- Chris Raines, website design / newsletter layout
- Liz Borgmann, newsletter editing



Pre-op panoramic radiograph shows rampant decay



Post-op Cephalometric radiograph



Post-op panoramic radiograph with implant supported prosthesis in place



Megan and her sister, Amanda, arrive at the Philadelphia International Airport.

Many people think of makeovers as being purely elective and driven only by vanity and esthetic issues. Reality suggests that the improvement of self esteem is what actually allows patients to enjoy life more fully. Completely restored, Megan is attending the university program of her dreams, exploring the Pacific seas. She has successfully renewed her relationship with an old friend and is on the threshold of a completely positive future.

Making a difference in Megan's life and following her smile through its achievements is the reward of a good dental "team." When the patient is not simply a chart, we effectively communicate both skill and energy. This is an important part of the treatment plan.



Mrs. Susan Wolfinger gives Megan a stylish new hair-do as part of her esthetic makeover.

The Institute For Facial Esthetics

Continuing Education

Traditional 2-Stage Implant Protocol and

1-Stage TEETH IN A DAY™

Featuring the Brånemark System®

Co-sponsored by Nobel Biocare USA, Inc.*

Course Dates:

September 20-21-22, 2004

May 3-4-5, 2004

January 17-18-19, 2005

Faculty:

Thomas J. Balshi, DDS, FACP
Glenn J. Wolfinger, DMD, FACP
Robert Winkelman, CDT, MDT

Time:

8:00 AM - 6:00 PM

Lunch 12:00 - 1:00 PM

Tuition:

\$ 1800

Credits:

Eligible for 24 hours of
continuing education credit

Location:

Institute for Facial Esthetics
467 Pennsylvania Avenue #201
Fort Washington, PA 19034

Educational Objectives: To teach and demonstrate the effect of osseointegrated dental implants on facial esthetics and general patient well-being; To provide clinical instruction and hands-on implant training; To provide clinical patient management before, during, and after dental implant rehabilitation; To provide post-prosthesis maintenance via home and professional oral hygiene.

Course Content: Includes the fundamentals of implant surgery and prosthetics, patient selection, treatment planning, drape and anesthesia, evaluation of implant sites, bone preservation, site preparation, implant placement, surgical closure, abutment connection, loading of implants, post-op instructions. Special considerations include graft areas, anatomic defects, immediate extractions sites, delayed extraction sites, complications, preventing and solving problems, and TEETH IN A DAY™ for the maxilla and mandible and the philosophy of extreme dental/facial makeovers.

Teaching Methods: Lectures, slides, videos, hands-on surgical and prosthetic procedures. Live surgery observed.

Seminar Includes: Certificate of attendance, course materials, lunch and refreshments.

**Nobel Biocare is an ADA CERP Recognized Provider. The formal continuing education programs of this sponsor are accepted by the AGD for Fellowship/ Mastership credit. Participants are eligible for 24 hours of continuing education credit. Continuing education credits issued for participation in this CE activity may not apply towards license renewal in all States.*

For more information or to register:
call 215-643-5881 or fax 215-643-1149

The Institute For Facial Esthetics Reserves the right to cancel the course at any time with no responsibility other than full refund of tuition paid. No refunds made within 48 hours of the course.

Extreme Dental/Facial Makeover



Manicured nails make Megan smile



Immediately after lightening haircolor



New smile, new hair style



Prosthodontic Insights is published by Prosthodontics Intermedica and distributed without charge to qualified individuals. Please request a subscription on your organization's letterhead.


Prosthodontics Intermedica
467 Pennsylvania Avenue, Suite 201,
Fort Washington, PA 19034 U.S.A.
Tel: 215-646-6334 Fax: 215-643-1149
Email: PITEAM@aol.com

A Whole New World in Just One Day

TEETH IN A DAY

Dr. Glenn Wolfinger and Dr. Thomas Balshi, Board Certified Prosthodontists present real life stories about actual patients experiencing Teeth In A Day™ Procedures step by step.

To Request a free Teeth In A Day™ Video Call Prosthodontics Intermedica at 215-646-6334 or email us at PITEAM@aol.com



A Patient's Guide to Dental Implants

\$14.95 plus shipping and handling

By Thomas Balshi, DDS, William Becker, DDS, Edmond Bedrossian, DDS, Peter Wohrle, DMD
Four dental implant specialists explain dental implant treatment step by step, in a first-of-its-kind book. Among the topics the authors cover: Who is a candidate for implants?, the advantages of implants, how implants are surgically placed, how to find a qualified dentist, and follow-up care. The book is loaded with before and after photos of patients.

This book can be ordered from Prosthodontics Intermedica, Fort Washington, PA.