
An Analysis and Management of Fractured Implants: A Clinical Report

Thomas J. Balshi, DDS*

An analysis of 4,045 implants placed in function during a 5-year period yielded eight fractured implants (0.2%). All fractures had associated marginal bone loss. The majority (six of eight) were supporting posterior prostheses. Parafunctional habits were diagnosed in all patients with fractured implants. Most patients presented with loosening or fracture of prosthetic gold screws or abutment screws prior to fracture. This study reports on the treatment of fractured implants accomplished by refacing the fractured titanium and adapting new abutments or replacing the entire implant with subsequent prosthesis refabrication.

(INT J ORAL MAXILLOFAC IMPLANTS 1996;11:660-666)

Key words: bone resorption, fractured implant, implant repair, implant replacement, occlusal load, osseointegrated implant, parafunctional forces

The incidence of fractured implants is small. However, when fractured implants do occur, they can cause difficult problems for patients and clinicians. Determining the etiology of fracture and treatment of it can be complex for the osseointegration team. The causes for implant fracture can be divided into three categories: (1) defects in implant design or material; (2) nonpassive fit of the prosthetic framework; and (3) physiologic or biomechanical overload.

Causes of Implant Fracture

Manufacturing-Induced Fractures. Defects in the manufacturer's design and production are the least likely reason for implant fracture. Eight 3.75-mm-diameter implants of 4,045 implants (Brånemark System, Nobel Biocare USA, Chicago, IL) placed in the author's center fractured during a 5-year period from 1989 to 1994. Microscopic analysis of the fractured components did not reveal porosities or other defects in titanium (Fig 1) and were not considered a fault of the manufacturing process.

Framework-Induced Fractures. The second category is the accuracy of fit of the prosthetic framework. Stress caused by screw joint connections to the implants from an ill-fitting prosthetic framework can result in constant shear load on the implant, predisposing it to fracture. Fracture could also result from bending, combined with axial tension or compression and torsion. Frequently, loosening of the screw(s) on the supraimplant component precedes implant fracture and may be a warning sign that the framework needs re-evaluation.

Overload-Induced Fractures. Biomechanical or physiologic overload appears to be the most common reason for implant fracture. Overload can emanate primarily from two areas, parafunctional habits and prosthesis design. Excessive occlusal force generated in either or both situations, particularly in lateral excursions of prostheses with posterior cantilevers, presents an opportunity for implant fracture through bending overload.

Parafunction has been identified as the major etiologic factor associated with implant fracture (Figs 2a to 2c). Analysis of the eight fractured implants identified in our patient population indicated that all five patients in the study demonstrated extreme bruxing and clenching habits and all admitted to having moderate to very high levels of stress in their daily routines. All were aware of the daily and nocturnal parafunctional habits.

*Private Practice, Fort Washington, Pennsylvania.

Reprint requests: Dr Thomas J. Balshi, Prosthodontics Intermedica, Institute for Facial Esthetics, 467 Pennsylvania Avenue, Fort Washington, Pennsylvania 19034.




Fig 1 Microscopic analysis of fractured implant demonstrates homogeneous density of titanium.

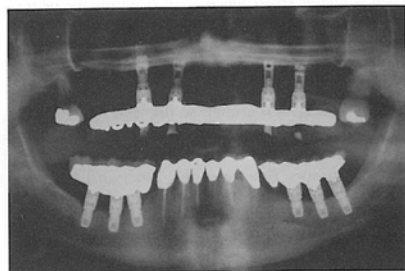


Fig 2a Panoramic radiograph shows bone levels at or near the first thread of Brånemark System implants 1 year following prosthesis placement.

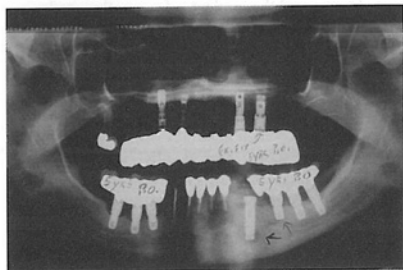


Fig 2b Five years following prosthesis placement, the patient reports screw loosening, significant occlusal wear resulting from parafunctional habits, and radiographic evidence of bone loss around the implants.




Fig 2c Seven years after prosthesis placement, the patient again presents with a loose prosthesis. Upon removal of the prosthesis, abutment cylinders are "flanged" because of excessive rotational wear. One abutment screw (center) had fractured, and one implant had also fractured.

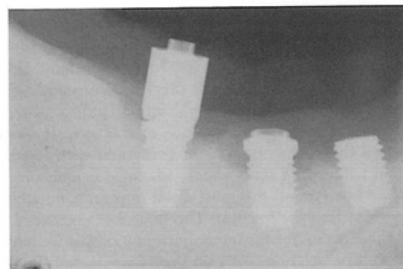


Fig 2d The two posterior abutments are loose, and the anterior implant has fractured.

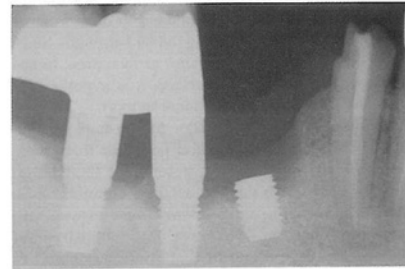


Fig 2e Immediate treatment requires replacement of the two flanged and distorted abutments with new abutments, and replacement of the original prosthesis, modified to remove the anterior component.

Implants are subjected to bending moments in the posterior quadrants, especially in patients with parafunctional habits. Theoretically, bending moments induce higher stress levels than compressive or tensile forces.¹ Morgan et al² analyzed fractured implants and concluded that commercially pure titanium implants failed as a result of bending fatigue.² Quirynen and coworkers³ noted that overload may also cause bone loss around an implant.

Implant fractures differ among individuals and groups. There is also a difference in fractures related to experience. For example, Zarb and Schmitt⁴ reported in 1990 on 274 implants placed with no implant fractures. In a retrospective study on fractured implants (39 patients), Rangert et al⁵ concluded that the majority of fractures occurred in posterior quadrants where prostheses were supported by one or two implants. The majority of patients had a combination of cantilevers and bruxism or heavy occlusal load, all leading to bending overload.⁵

In 1992, Tolman and Laney⁶ reported three implant fractures in a study of 1,778 implants placed (0.17%). Similarly, Gunne et al⁷ reported only three fractured implants in a study of 521 (0.57%) implants used to restore partially edentulous patients. In a study comparing single-molar replacements supported by one or two implants, Balshi et al⁸ reported no implants fractured.

It is essential that more implants be placed in patients exhibiting parafunctional habits to avoid implant fracture. Minimizing or eliminating cantilevers and occlusal contacts in lateral excursion reduces the potential for fracture.⁹ Posterior cantilevers, particularly in the maxilla, can be avoided by placing implants in the pterygomaxillary area,¹⁰ which significantly reduces the potential for implant fracture. Patients with parafunctional habits should also receive occlusal guard treatment to minimize any aberrant nocturnal forces. Recently,^{11,12} implants with larger diameters have been recommended to provide more metal bulk, thereby increasing implant strength. Since wider implants provide greater surface area, hence increased bone-implant interface, it is hypothesized that they could provide additional support.

Occlusal forces play a major role in implant fracture. In studies where natural posterior teeth were replaced with ceramometal restorations designed to function only with centric occlusal contacts while avoiding working or nonworking contacts, no implants fractured.⁸ However, one molar implant outside the time scope of that study was noted to have fractured 5 years after being placed in function. Included in the present analysis, this patient was diagnosed as having developed a pronounced bruxing and clenching habit.

Fracture Management

Despite the relatively low incidence of implant fracture, treatment is required when this complication occurs. Three methods of treatment are available:

1. Removal of the fractured implant, replacement of the implant, and refabrication of the prosthesis (Figs 3a to 3d)
2. Modification of the existing prosthesis leaving the fractured portion of the implant in place⁹ (see Fig 2e)
3. Modification of the fractured implant and refabrication of a portion of the prosthesis (Figs 4a to 4i).

Fracture Observations

Screw loosening is often observed before implant fracture. Either the gold screw, or in other cases, the abutment screw, can fracture if loose. In addition, angular bone loss around the implant is frequently noted.

When implant fracture occurs, the patient commonly presents with an inflammatory response in the mucosal tissue surrounding the fracture site. Bone loss is noted around all fractured implants studied. In some cases, bone loss is noted before implant fracture. Bone loss, which generally occurs rapidly to the level of the fracture and usually beyond, is often apparent radiographically (Fig 4a). Modification of the fractured implant requires surgical exposure of the remaining portion of the implant to provide access to the fractured surface (Fig 4c). Refacing, or smoothing the abutment-facing surface of the implant, should only be attempted if a sufficient number of internal threads remain for connection of a new transmucosal abutment.

Patient Treatment

In the illustrated example (Figs 4a to 4i), a three-unit implant-supported maxillary right posterior prosthesis was in function for 7 months (time from prosthesis placement until the fracture was diagnosed). The patient presented with a loose prosthesis and radiographic evidence of fracture. It was noted that the same patient presented with loose gold connecting screws and radiologic evidence of bone loss around the most distal implant 2 months prior to implant fracture. The bone loss continued, despite occlusal adjustment permitting contacts only in centric relation, with no buccal or lingual pressures in lateral excursions.

Treatment included removal of the fractured portion of the implant and refacing the remaining top portion with a special custommade rotary cutting

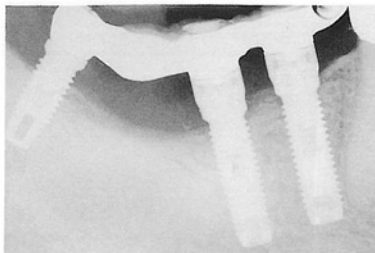


Fig 3a Placement of ceramometal fixed prosthesis (Feb 6, 1989).

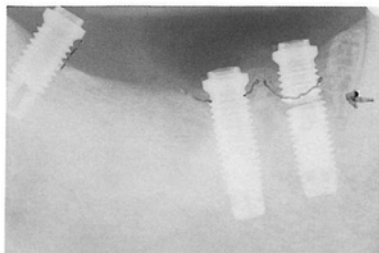


Fig 3b Thirty-one months later (Sept 17, 1991) bone loss accompanies fractured implant (arrow).

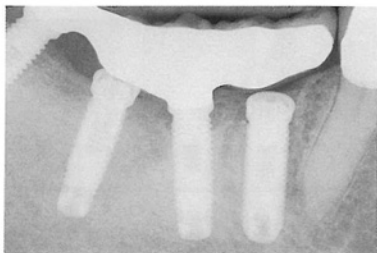

Fig 3c Fractured implant is removed and immediately replaced with larger-diameter implant (Sept 17, 1991). An additional implant is placed between the two remaining original implants.

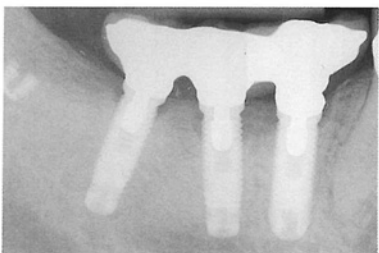


Fig 3d Nine months after placement of the prosthesis (Dec 10, 1992), bone levels remain constant. Note gold CeraOne abutment screws. The apical portion of the fractured most distal original implant is evident.

device (Fig 4b) consisting of heat-treated speed steel cutters and a noncutting hard-drawn stainless steel guide. Copious irrigation was used to reduce heat from friction during the refacing process. The refacing rotary instrument was designed with a noncutting guiding tip (Fig 4b), which can be inserted into the threaded portion of the implant in an attempt to keep the refacing cutter perpendicular to the long axis of the implant. After the implant was refaced (Fig 4c), a measurement was taken to determine the depth of the internal threads available for abutment connection. Standard abutment screws required shortening to accommodate the fewer number of internal threads (Figs 4d and 4e). Radiographic verification of the newly fitted abutment was obtained (Fig 4h). Once the abutment was placed, the screw was tightened to 20 Ncm of torque.

The new abutment replaced the previous abut-

ment and the fractured portion of the titanium implant. It was slightly shorter than the combined length of the previous abutment and the fractured piece of the implant, so that the original prosthetic gold casting, now sectioned, was not in hyperocclusion when placed on the new abutment. Following connection of all of the prosthetic framework components, a rigid soldering connection was made between the existing prosthetic section and the portion resected on the repaired implant (Fig 4h).

Refabrication or modification of the existing prosthesis included shortening, or elimination, of the cantilever, particularly because the refaced fractured implant was the terminal support for the prosthesis (Fig 4h). Continued observation of fractured implants in function has shown that modification of the implants permits continued use for the support of fixed prostheses for up to 6 years.

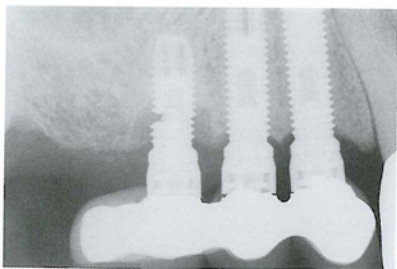


Fig 4a Distal implant fractured 7 months after placement of prosthesis. Gold screws had previously loosened and fractured. Note bone loss below the level of fracture.




Fig 4b Implant refacing tool (left) with noncutting guide tip. Smaller tip (right) modified to fit into the shallow abutment screw hole created by implant fracture.

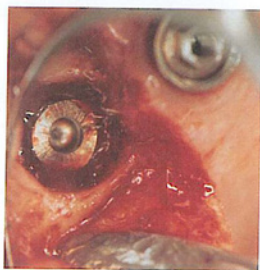

Fig 4c Implant refaced to a smooth perpendicular surface. Note cratered bone loss around the implant.




Fig 4d Standard abutment screw shortened by cutting it to the appropriate length with carborundum disc.




Fig 4e Modified abutment screw has only three threads remaining.

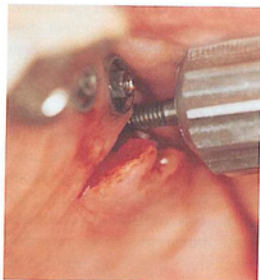


Fig 4f Retapping abutment screw threads in fractured implant accomplished by repeated forward and reverse rotation. The tap is frequently removed to clean the collector flutes.

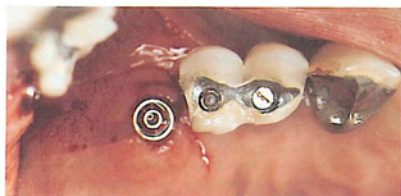


Fig 4g Standard abutment is fastened to the refaced fractured implant. Existing implant prosthesis is sectioned to accommodate change in abutment height.

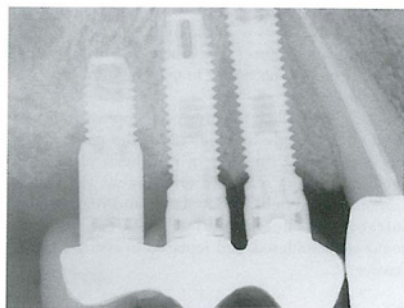


Fig 4h Radiograph of refaced fractured implant with refabricated ceramometal fixed prosthesis. Note the shortened cantilever.

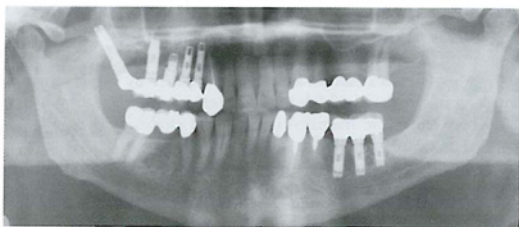


Fig 4i Two additional implants, one in the pterygomaxillary bone and one elevating the antral floor, are added to the three original implants to support fixed prosthesis with a reduced occlusal table.

Discussion

A retrospective analysis revealed eight fractured 3.75-mm-diameter implants of 4,045 (0.2%) in an implant population. All but two fractured implants were in the posterior quadrants, equally distributed between the maxilla and mandible. In the patient presented, the posterior cantilever was probably a major factor in the fracture of the implant (Figs 4a to 4i).

Except for one maxillary single-molar replacement, all other fractured implants were part of multiple-implant-supported fixed ceramometal prostheses in partially edentulous patients. Analysis of implant position disclosed that all had straight-line alignment, which leads to greater potential for creating bending moments on the implants.

Therefore, from the large body of data reported in the literature and the experiences in my center, it is recommended that careful control of occlusal forces be provided to eliminate all posterior contacts in

mandibular eccentric movements. Placement of implants should be staggered to avoid a straight-line configuration. The use of wider-diameter implants should also be considered when bone volume permits. It is suggested that posterior cantilevers or buccolingual offsets be avoided or minimized, especially in the partially edentulous patient. When patients exhibit chronic loosening of gold or abutment screws or experience fracture of components other than the implant, critical reassessment of the prosthesis is necessary. All abutments should be retightened, impression copings should be rigidly locked together avoiding material shrinkage, and an accurate impression and new master cast should be obtained. The prosthesis should be examined on the new cast, using the one gold screw test in which each screw is positioned at 10-Ncm torque, and the gold cylinder fit is checked under magnification. If even the slightest fit discrepancy can be detected, the casting should be cut, and the prosthesis should be reassembled. In

patients who have been identified as pronounced bruxers or clenchers and who have experienced multiple implant fractures, the placement of additional implants may be necessary to overcome the masticatory overload.

Lastly, even when the prosthesis appears to have a "perfect fit" on the master cast, if the patient feels any sensation at the time of prosthesis placement, such as a pulling sensation or tightness, the casting components should be sectioned and reassembled intraorally. The assembled units can then be removed, resoldered, and replaced to assure a totally passive fit.

Summary

The literature reviewing implant fractures currently indicates only a small incidence. The majority of fractures occur in the posterior quadrants and are associated with bending overload created by a combination of parafunctional forces, cantilevers, and possibly framework misfit. Straight-line implant placement contributes to the potential for higher bending moments.

Treating fractures can be accomplished either by replacing the implant and fabricating a new prosthesis or by refacing the fractured implant and modifying or refabricating the prosthesis. Additional time is needed to assess the results obtained from using these procedures. However, a passive framework fit and controlled occlusal forces are essential to success of the implant prosthesis and the avoidance of implant fracture.

Acknowledgments

The contributions of Bob Winkelman, CDT, MDT, of Fort Washington Dental Lab, and Liz Kirk, for her efforts in manuscript preparation, are herein acknowledged.

References

1. Rangert B, Sullivan R. Biomechanical principles preventing prosthetic overload induced by bending. *Nobelpharma News* 1993;7(3):4-5.
2. Morgan MJ, James DF, Pilliar RM. Fractures of the fixture component of an osseointegrated implant. *Int J Oral Maxillofac Implants* 1993;8:409-414.
3. Quirynen M, Naert I, van Steenberghe D. Fixture design and overload influence marginal bone loss and fixture success in the Brånemark System. *Clin Oral Implants Res* 1992;3:104-111.
4. Zarb G, Schmitt A. The longitudinal clinical effectiveness of osseointegrated dental implants. Part III: Problems and complications encountered. *J Prosthet Dent* 1990;64:185-194.
5. Rangert B, Krogh PHJ, Langer B, Van Roekel N. Bending overload and implant fracture: A retrospective clinical analysis. *Int J Oral Maxillofac Implants* 1995;10:326-334.
6. Tolman DE, Laney WR. Tissue-integrated prosthesis complications. *Int J Oral Maxillofac Implants* 1992;7:477-484.
7. Gunne J, Jemt T, Lindén B. Implant treatment in partially edentulous patients: A report on prostheses after 3 years. *Int J Prosthodont* 1994;7:143-148.
8. Balshi TJ, Hernandez RE, Pryszyk MC, Rangert B. A comparative study of one implant versus two replacing a single molar. *Int J Oral Maxillofac Implants* 1996;11:372-378.
9. Balshi TJ. Preventing and resolving complications with osseointegrated implants. *Dent Clin North Am* 1989;33:821-868.
10. Balshi TJ, Lee HY, Hernandez RE. The use of pterygomaxillary implants in the partially edentulous patient: A preliminary report. *Int J Oral Maxillofac Implants* 1995;10:89-98.
11. Sullivan DY. Wide implants for wide teeth. *Dent Econ* 1994 Mar;84(3):82-84.
12. Langer B, Langer L, Herrmann I, Jorneus L. The wide fixture: A solution for special bone situations and a rescue for the compromised implant. Part I. *Int J Oral Maxillofac Implants* 1993;8:400-408.