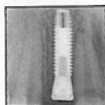

Candidates and Requirements for Single Tooth Implant Prostheses



Thomas J. Balshi, DDS, FACP*

Successful prosthodontic treatment begins with an accurate diagnosis and thorough and comprehensive treatment planning. Osseointegration is an integral part of prosthodontic treatment planning. When use of the single tooth implant is anticipated, there are several procedure objectives that should be considered: elimination of pathosis; attainment of ideal fixture alignment and stability; protection of the adjacent teeth; preservation or augmentation of the alveolar ridge; attainment of primary closure; and avoidance of mucosal pressure. Esthetic and biologic complications are discussed. (Int J Periodont Rest Dent 1994;14:317-331.)

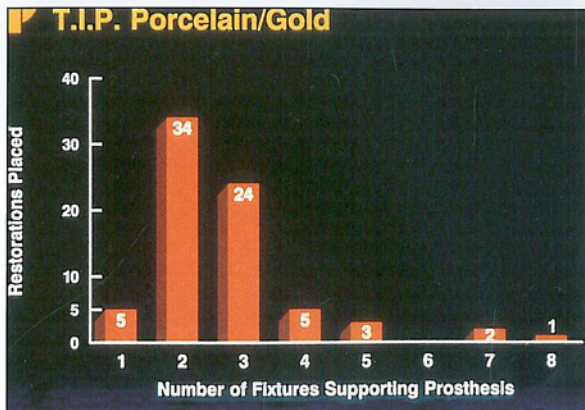
The single tooth implant prosthesis may be one of the most challenging prosthetic restorations. Treatment planning concepts, clinical requirements, and applications must be discussed when candidates and requirements for the single tooth implant prosthesis are considered.

The replacement of a single tooth using an osseointegrated implant stems from an evolution in concepts, technology, and clinical application following years of basic research and fundamental studies. The methods of osseointegration developed by Bråne-mark et al¹ are well documented, including first-stage surgery followed by unloaded healing for either 3 to 4 months in the mandible or 5 to 6 months in the maxilla.

Over a decade ago, Adell et al² described the successful use of multiple osseointegrated fixtures supporting fixed partial prostheses in both the maxillary and mandibular arches. These

*Institute for Facial Esthetics, 467 Pennsylvania Avenue, Fort Washington, PA 19034.

Fig 1 The distribution of fixtures to support prostheses shows the most common partially edentulous restorations are supported by two fixtures followed by three fixture-supported prostheses.



results were confirmed by numerous centers worldwide. The use of osseointegrated implants became a highly accepted method of restoration for the fully edentulous patient.

Extrapolation from the original clinical methodology soon led to the successful treatment of partially edentulous patients. In 1989, Jemt et al³ reported high success rates with 876 consecutively placed implants in partially edentulous patients. At the same time, Balshi⁴ reported the results of a 4-year study of partially edentulous patients using osseointegrated

implants. The results of this study indicated a 99.5% success rate for individual fixtures placed in the maxilla and a 98% success rate for those placed in the mandible. Of the 214 fixtures placed in 60 partially edentulous patients, the most common type of restoration used was the two fixture-supported prosthesis, followed by the prosthesis supported by three fixtures (Fig 1). This study also included the analysis of five single tooth replacements with one complication related to a single premolar implant prosthesis.

Single tooth implants

Clinical success in treating both fully and partially edentulous patients with osseointegrated implants ad modern Brånemark led to their use for the replacement of single missing teeth. The original hardware design had mechanical complications that required an antirotational component to prevent the prosthetic restoration from rotating on the abutment cylinder or on the fixture itself. This clinical application began in the 1980s and was introduced to the literature by Jemt in 1986.⁵ The new compo-

nents were designed to maintain titanium contact with the mucosal tissue via a nonrotating abutment designed to support the veneer material with an esthetic subgingival margin.

Lekholm and Jemt⁶ described the initial concept of single tooth treatment for patients who needed prosthetic replacement predominately to improve esthetics where a space or diastema existed, or to replace a missing tooth where the adjacent teeth were intact. Two forms of antirotational mechanisms were designed. Both provide nonrotating stability of the final restoration and permit the component to be securely fastened to the implant while maintaining a counterrotational antitorque force to minimize injury to the fresh osseointegrated interface at the initial delivery of the abutment.

In a multicenter study, Jemt et al⁷ reported on 107 osseointegrated Brånemark fixtures placed in 92 patients for single

tooth replacement. Only three implants were lost after the first year of function. Most of the remaining restorations were esthetically successful using modified components. The gingival condition was healthy around the single crowns and its appearance was similar to that around the permanent teeth.

The problem most frequently experienced during the first year was related to loose abutment screws; 26% of 107 implants inserted required retightening of the retaining screws during the observation period. However, the occurrence of loosened screws was less frequent as the study progressed. It is the author's opinion that the autoburnishing of the titanium interfaces at the screw joint connections resulting from the micromovements created during function, or the interproximal contact pressures with orthodontic autoequilibration and the adjacent dentition led to the screw loosening.

Prosthetic rationale

Prosthetic maintenance of permanently cemented fixed prostheses has always been problematic. These restorations often required destruction and subsequent refabrication of the prosthesis itself to preserve the underlying abutment teeth.

From a prosthetic standpoint, an easily retrievable single tooth implant is desirable. With osseointegrated implants and a retrievable prosthesis, repair of a fractured veneer can easily be accomplished. Modification of the crown at any time, or its replacement after years of function because of color change in the adjacent, natural teeth, are distinct advantages. Additionally, with the screw-retained single tooth prosthesis, the potential for cement dissolution is avoided.

Among the advantages of the single tooth osseointegrated implant replacement over traditional fixed prosthodontics are its highly predictable prognosis and longevity.¹⁰ The prognosis of osseointegration is dependent on two major factors: the surgical aspect of fixture placement with meticulous hard and soft tissue manipulation^{1,11,12} and meticulous prosthodontic treatment.

With the knowledge that the potential for osseointegration of a well-placed fixture is excellent, one should consider the procedure objectives, possible complications, and the clinical condition of potential candidates for this form of restorative treatment.

Treatment planning and procedure objectives

The success of quality prosthodontic treatment always begins with an accurate diagnosis and comprehensive treatment planning.¹³ For the single tooth implant prosthesis, osseointegration is an integral part of prosthodontic treatment planning. There are several procedure objectives that should be considered: the elimination of pathosis, the attainment of ideal fixture alignment and stability, the protection of the adjacent teeth, the preservation or augmentation of the alveolar ridge, the attainment of primary closure of the mucosal tissue immediately following root extraction and fixture placement, and the avoidance of pressure on the mucosa created by a temporary prosthesis.

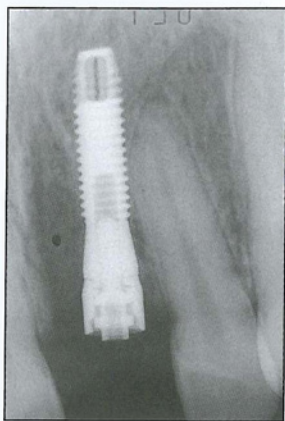


Fig 2 Radiograph 5 months after fixture placement in an immediate extraction site, reveals the osseointegrated conical-necked Brånemark implant.

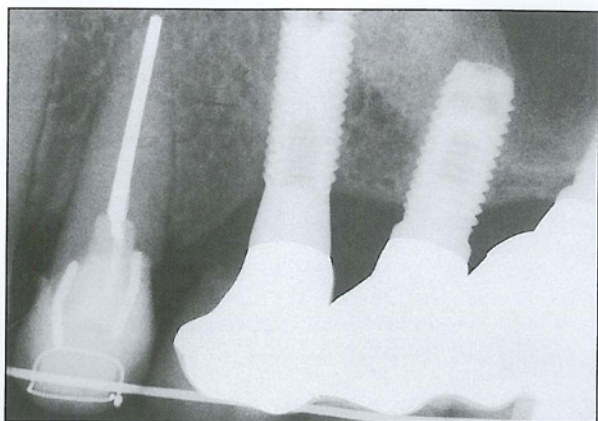


Fig 3 Three-year postoperative radiograph shows bone loss stabilized at the first threads on the conical implant, similar to the stabilized bone position of the adjacent standard fixture.

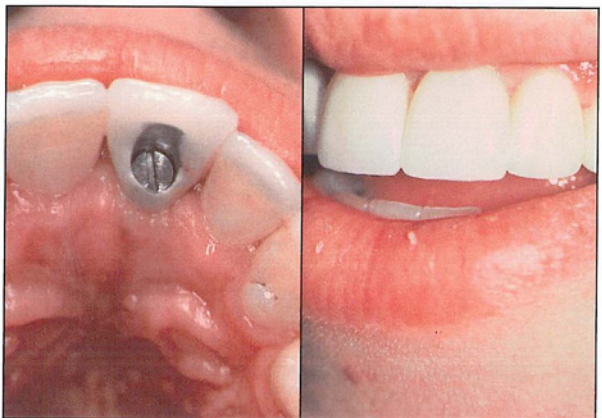


Fig 4 Retaining screw access is on the gingulum area of anterior teeth when fixtures are ideally placed.

The conical neck implant

Standard Brånemark fixtures were used in most of the reported studies. However, in 1988 a modified surgical and prosthodontic approach for single tooth rehabilitation using osseointegration was described by Öhrnell et al.⁸ This method prescribed the use of a special conical implant adapted for single tooth replacement immediately following tooth extraction (Fig 2). The alveolar socket was carefully cleansed of any granulation or fibrous tissue prior to insertion of the implant.

Use of this implant diminished after continued observation of bone loss around the conical portion of the implant. It has been observed that bone loss around the fixtures usually stops at the beginning of the threads, similar to that with the standard Brånemark implant.⁹ Figure 3 shows the receded but stabilized bone level around the conical fixture 3 years after prosthesis delivery.¹⁰

With the option of the single tooth implant prosthesis, alternative prosthetic replacement possibilities should be considered. In addition to the traditional fixed prosthesis and the resin-bonded pontic there are numerous removable prosthetic appliances available for tooth replacement. However, biologic as well as sociologic conditions indicate that, in almost all circumstances, the fixed prosthesis is the treatment of choice (Fig 4).

With the advancement of osseointegration, a new era of prosthetic tooth replacement has begun. The rationale for an easily retrievable single tooth prosthesis is quite apparent.

Biologic rationale

The biologic rationale for using an osseointegrated implant rather than a traditional fixed prosthesis includes:

1. Preservation of the enamel and dentin of adjacent teeth. Tooth preparation for an esthetically acceptable and functionally durable fixed prosthesis requires the removal of at least 1.5 mm or more of enamel to provide sufficient space for a physiologically contoured esthetic prosthesis.

2. Avoidance of pulpal insult. With every tooth preparation, there is always the risk of pulpal insult, ranging from acute pulpitis to pulpal necrosis requiring endodontic treatment.

3. Minimization of periodontal problems. The placement of subgingival margins affects the natural condition of the sulcus and may lead to increased insult of the periodontal tissues.

4. Maintenance of normal periodontal ligament function. By requiring a natural abutment tooth to take on the added responsibility of pontic support, normal periodontal ligament functions are increased, and in cases of previous diminished periodontal support, may be injurious.

5. Avoidance of added potential for marginal deterioration. The traditionally fixed prosthesis, no matter how fine its marginal integrity, always has a potential for marginal deterioration as a result of carious lesions, cement leakage, or a periodontal insult leading to gingival recession.

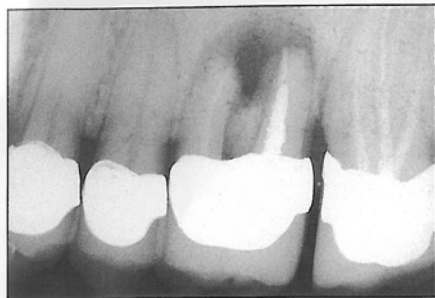

Fig 5 Following extraction of the first molar, long-standing apical pathosis will require long-term healing.

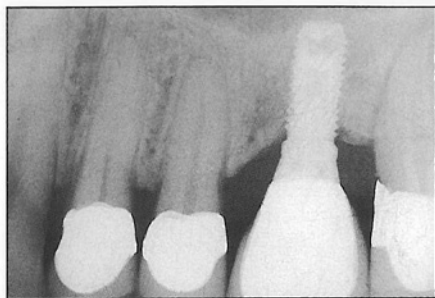


Fig 6 The fixture engaged the cortical plate at the sinus floor. Six months later, the fixture was uncovered and a molar crown was fabricated using the titanium single tooth abutment system.

Elimination of pathosis.

One of the most important procedure objectives is the elimination of pathosis. Large, chronic periapical abscess conditions require thorough debridement following molar extraction (Fig 5). The alveolar ridge may require osseous healing prior to implant placement. After 1 year of healing, a fixture is placed that engages the cortical plate of the sinus floor, or at least contacts that area for better fixture stability. Six months postinstallation, the fixture is uncovered and the first molar replacement is fabricated (Fig 6).

Ideal alignment. In the determination of ideal implant placement, the long axis angulation should permit the retaining screw to emerge in the area of the cingulum of anterior teeth (see Fig 4). This can be easily accomplished using surgical guidepins or guide-stents.¹⁴ Although guidestints are helpful, the adjacent teeth can function as an excellent guide for fixture angulation and position.

Protection of adjacent teeth. Optimal fixture placement should always account for the root position of adjacent teeth. At least 1.5 mm of

bone should be maintained between the fixture threads and the periodontal ligament of the adjacent teeth. An intercoronal distance of 8 mm is ideal. Where minimal intercoronal space exists, surgical preparation may require long, shanked burs. When insufficient space exists, orthodontics should be considered.

Preserving or augmenting the ridge

Labial plate resorption. Anterior tooth loss frequently leads to resorption of the labial plate of bone. This factor must always be considered with single tooth replacement. The fixture should be placed palatally to account for labial bone loss when surgical augmentation is not considered. Crown construction for this clinical condition will require an anteriorly cantilevered cervical extension of the prosthesis (Fig 7a); optimal esthetics can be obtained using this prosthetic technique (Fig 7b).

Immediate extraction sites. Following fixture placement in immediate extraction sites, primary closure of the area is an objective that can be accomplished by obtaining larger flap release and pulling the mucosal tissues over the site. This flap usually extends one tooth beyond the fixture site on each side.

Avoidance of mucosal pressure. Many patients who undergo single tooth replacement expect immediate esthetic temporization. To avoid mucosal pressure, use of soft tissue liners under removable appliances is mandatory (Figs 8a and 8b). Other forms of provisionalization, such as pontics bonded with resin to the adjacent dentition or denture teeth fastened to an orthodontic arch wire, are also effective.

Anatomic and prosthodontic factors are combined when the treatment plan calls for the use of a single tooth implant replacement. Basic anatomic factors to be considered with prosthodontic rehabilitation include quality and quantity of bone, anticipated function, and esthetics. Adequate bone quantity and quality are essential for initial implant stability and subsequent load-carrying capability. Treatment planning should also include anticipated function because there is an important relationship between bone quality and quantity and the anatomic location and anticipated function of the replacement tooth.

Single tooth function

Anticipated function for single tooth replacement can be divided into four general categories: incisor or canine guidance in the anterior and premolar or molar function in the posterior. Weber et al¹⁵ stated that stress loading of the implant begins with fixation of the suprastructure or the connection of the prosthetic restoration. This applies to the single tooth implant replacement as well as multifixture-supported prostheses.

Anterior guidance. Rangert¹⁶ states that the screw joint that attaches the prosthetic gold cylinder and the transmucosal abutment to the implant fixture constitutes a flexible system. This may in some way partially mimic the action of the periodontal ligament. For this reason, anterior guidance on the implant prosthesis that is in harmony with the adjacent natural teeth can be accomplished.

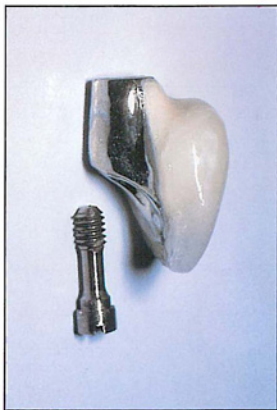

Fig 7a Cervical labial extension is required when implants are placed palatally.

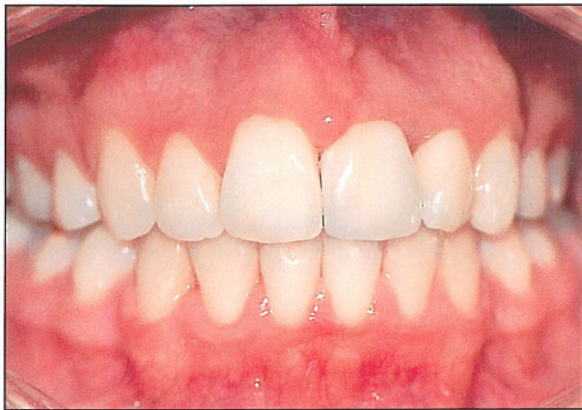

Fig 7b Optimal esthetics can be obtained using the single tooth replacement technique.

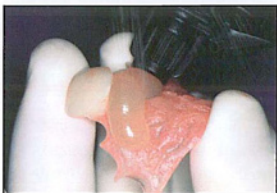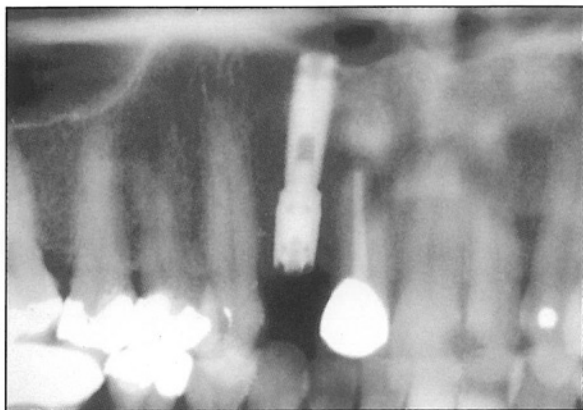


Fig 8a A light-cured, soft relining material should be used after the hard acrylic has been relieved over the fixture site.

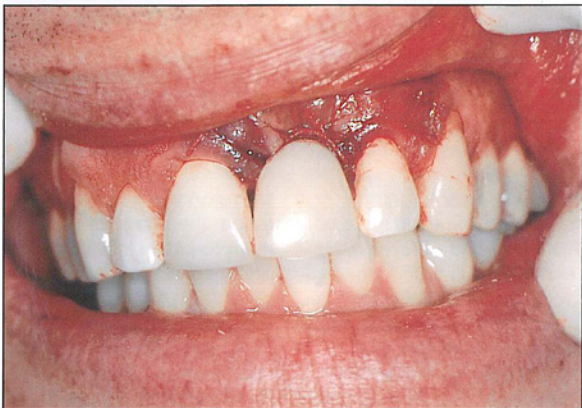

Fig 8b Following pressure-free confirmation of the soft material to the residual ridge, light activation stabilizes the material. Excess material can be trimmed to provide the maximum esthetics immediately following surgical fixture placement.

Fig 9 Five-month post-fixture placement radiograph shows the maxillary anterior implant engaging the cortical plate at the floor of the nose for additional stability.



Incisal guidance is an essential element of the anterior single tooth implant reconstruction. Thus, a fixture with maximum length, engaging an apical cortical plate, should be used (Fig 9).

In a clinical example, a single fixture replaces the patient's right lateral incisor. On the opposite side, a single fixture also replaces both the lateral incisor and the canine (Figs 10a to 10c). In both instances, incisal and canine guidance are developed as part of the restorative treatment plan and function of the final prosthesis. This patient continues to function successfully, with no biologic or mechanical change observed over the 4.5-year follow-up period.

Premolar function. In the premolar region, canine function in mastication should always be anticipated in addition to possible assistance with guidance in lateral excursions (Figs 11a and 11b). Group function, including canine and premolar guidance, is frequently a part of the older patient's long-standing occlusal adaptation. The premolar replacement functions in mastication and occlusal guidance and provides excellent posterior esthetics (Fig 11c).

Molar function. Molar replacement with a single implant can be accomplished provided the quantity and quality of bone permit stable osseointegration (Fig 12). A single fixture, 13 mm or longer,

placed in type I or II bone is more likely to maintain osseointegration under molar loading conditions than prostheses supported by shorter implants or those placed in more spongy bone.

Single short fixtures placed in either the maxillary or mandibular posterior may be incapable of withstanding heavy masticatory function and high occlusal loading. Therefore, it is preferable that two fixtures be placed whenever possible for single molar replacement.¹⁷

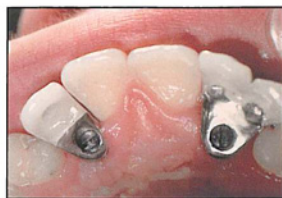

Fig 10a Implants support right lateral incisor and left lateral incisor and canine. Both provide incisal and canine guidance in excursive function.

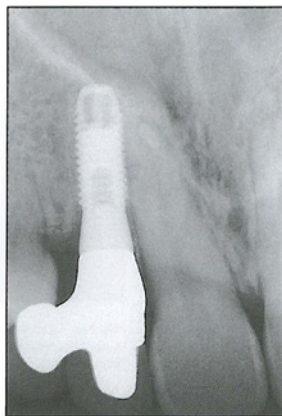


Fig 10b Periapical radiograph shows the porcelain-fused-to-gold final prosthesis replacing the lateral incisor and canine. Fixtures have been functioning for 4.5 years.

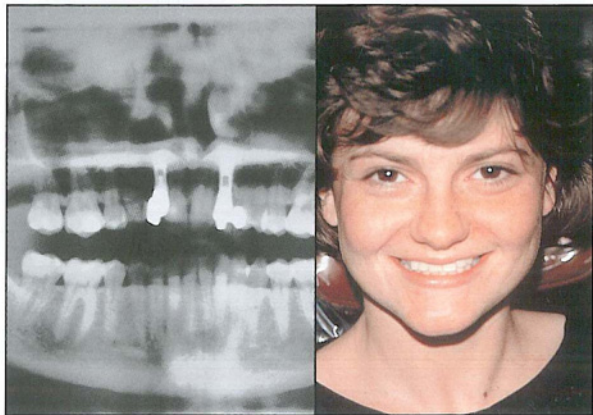


Fig 10c Posttreatment panoramic radiograph and clinical smiling view illustrate the biomechanical and cosmetic results achieved with osseointegrated replacements for congenitally missing teeth.

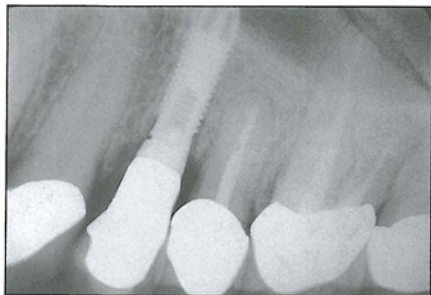


Fig 11a Six months after fixture placement, a periapical radiograph illustrates first premolar replacement using an osseointegrated implant to support a porcelain-fused-to-gold crown.

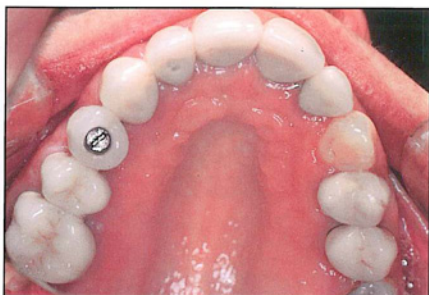


Fig 11b Occlusal view of the screw-retained porcelain-fused-to-gold crown with access for placement and removal through the occlusal surface.

Fig 11c The implant-supported premolar crown provides excellent function and mastication, occlusal guidance, and posterior esthetics.

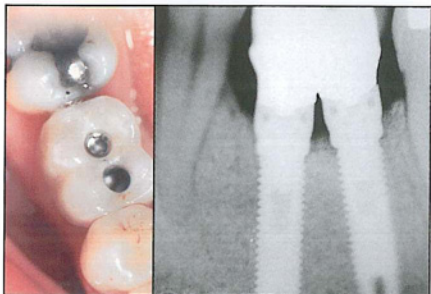
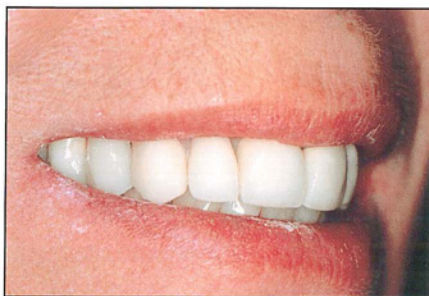

Fig 12 Four months following fixture placement, a single molar replacement is supported by two osseointegrated implants in the mandibular arch replacing the mesial and distal roots.

Esthetics

In addition to achieving all the biomechanical objectives required for functional stability, the single tooth implant prosthesis must also provide an esthetic replacement. A prosthesis that will be easily retrievable in the future will permit appropriate adjustments in color and surface texture as the adjacent natural teeth change. Teenagers with congenitally missing teeth are ideal candidates for this treatment process. Precise orthodontic treatment is generally a prerequisite (Figs 13a to 13h).

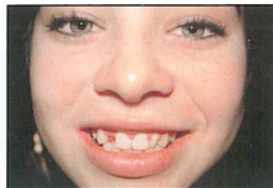

Fig 13a Facial smiling view of congenital partial anodontia of the maxillary right lateral incisor.

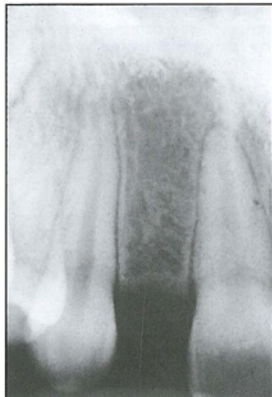


Fig 13b Periapical radiograph shows ideal root positioning following orthodontic treatment.

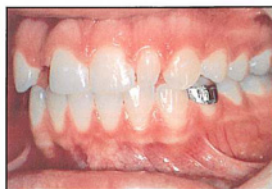

Fig 13c Left facial clinical view shows the congenitally deformed (peg-shaped) maxillary left lateral incisor.

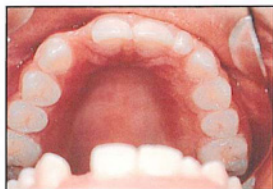


Fig 13d Palatal view illustrates the correct spacing created by proper orthodontics both for implant placement in the edentulous area and restorative treatment of the peg-shaped lateral incisor.

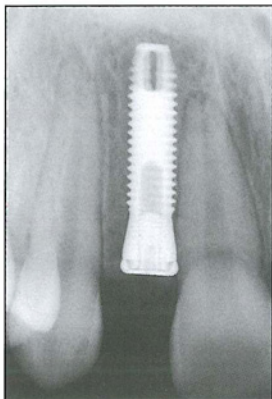


Fig 13e A conical-neck Brånemark fixture is placed between the central incisor and canine roots.

Fig 13f Fixture is placed palatally to accommodate both the labial undercut and underdeveloped alveolar ridge.

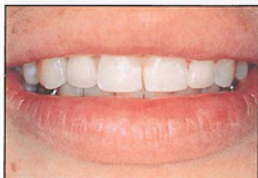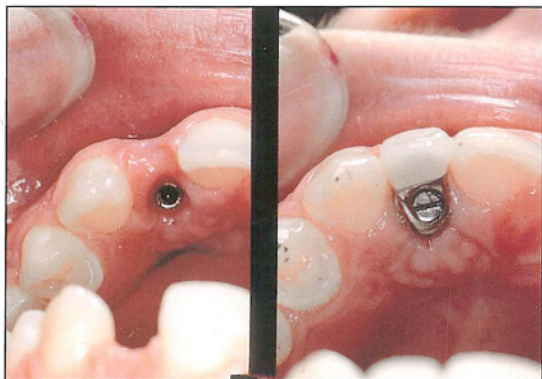


Fig 13g Smiling view of implant replacement for the maxillary right lateral incisor and porcelain laminate veneer restoring the congenitally deformed left lateral incisor.



Fig 13h Facial smiling view of restoration.

Summary

The use of osseointegrated implants has evolved clinically from the success established with the restoration of fully and partially edentulous patients ad modern Brånemark to the single implant-supported prosthesis. This concept of treatment has many biologic advantages over traditional prosthodontic methods, including preservation of the natural dentition and the supporting periodontium. Additional prosthodontic advantages such as repair or replacement for changing esthetic requirements are easily accomplished with screw-retained crowns.

Treatment planning for single tooth implant prosthesis requires an understanding of osseointegration relative to bone quality and quantity, the anatomic position within the dental arch, the anticipated function, and the potential for optimal esthetic results. The greater the dense bone contact area with the implant surface is, the stronger the functional capacity of the replacement tooth will be.

In areas where anatomic restrictions mandate shorter implant length, other methods of improving or increasing the dense bone contact surface area should be considered. Molar replacement frequently occurs in areas of inferior bone quality and quantity. Molars

are also subjected to the greatest functional loading. For these reasons, multiple fixtures should be used whenever possible for single molar replacement.

References

- Brånemark P-I, Zarb GA, Albrektsson T. Tissue-integrated prostheses: Osseointegration in Clinical Dentistry. Chicago: Quintessence, 1985.
- Adell R, Lekholm U, Rockler B, Brånemark P-I. A 15-year study of osseointegrated implants in the treatment of the edentulous jaw. *Int J Oral Surg* 1981;10:387-416.
- Jemt T, Lekholm U, Adell R. Osseointegrated implants in the treatment of partially edentulous patients. A preliminary study of 876 consecutively installed fixtures. *Int J Oral Maxillofac Implants* 1989;4:211-217.
- Balshi T. Use of porcelain in partial edentulism. Presented at the 4th Annual Meeting of the Academy of Osseointegration, Dallas, 3-4 March, 1989.
- Jemt T. Modified single and short span restorations supported by osseointegration fixtures in the partially edentulous jaw. *J Prosthet Dent* 1986;55:243-247.
- Lekholm U, Jemt T. Principles for single tooth replacement. In: Albrektsson T, Zarb GA (eds). The Brånemark Osseointegrated Implant. Quintessence, 1989:117-126.
- Jemt T, Laney W, Harris D, Henry P, Krogh P, Polizzi G, et al. Osseointegrated implants for single tooth replacement: A 1-year report from a multicenter prospective study. *Int J Oral Maxillofac Implants* 1991;6:29-36.
- Ohrnell L-O, Hirsh J, Ericsson I, Brånemark P-I. Single tooth rehabilitation using osseointegration: A modified surgical and prosthetic approach. *Quintessence Int* 1988;19:871-876.
- Balshi TJ. Preventing and resolving complications with osseointegrated implants. *Dent Clin North Am* 1989;33(4):821-868.
- Jemt T, Lekholm U, Grondahl K. A 3-year follow-up study of early single implant restorations ad modum Brånemark. *Int J Periodont Rest Dent* 1990;5:341-349.
- Beumer J, Lewis S. The Brånemark Implant System. St. Louis: Ishiyaku EuroAmerica 1989:222-229.
- Sherwood R, Sullivan D. Concepts and techniques of single tooth implant restorations. *Esthet Dent Update* 1991;2(2):17.
- Balshi T. Sequential treatment planning. *Gen Dent* 1987;March/April: 113-117.
- Balshi T, Garver D. Surgical guide stints for placement of implants. *J Oral Maxillofac Surg* 1987;45:463-465.
- Weber H, Benzing U. Biomechanical aspects of implant-supported prostheses for edentulous jaws. In: Laney WR, Tolman DE (eds). *Tissue Integration in Oral, Orthopedic and Maxillofacial Reconstruction*. Chicago: Quintessence, 1992: 149.
- Rangert B. Forces and moments on Brånemark implants. *Int J Oral Maxillofac Implants* 1989;4:241-247.
- Balshi T. First molar replacement with an osseointegrated implant. *Quintessence Int* 1990;21:61-65.

