

Facial and Oral Reconstruction Following Trauma and Failed Chin Implant: A Case Report

Thomas J. Balshi, DDS,* Glenn J. Wolfinger, DMD,† Maria Claudia Pryszyk, DMD,‡ and Stephen F. Balshi, MBE§

The effectiveness of the Brånemark method of osseointegration for restoration of the completely edentulous patient is well documented.¹⁻⁴ Restoration of the partially edentulous patient using osseointegration is also shown in the literature.^{5,6} In patients with extreme bone loss, or in cases in which accidental trauma had been applied to bone, it is common to facilitate bone regrowth with the use of any number of types of bone grafts.⁷ Grafts using cancellous and cortical freeze-dried bone in the jaw have been documented and have been successful.⁸ Bone grafts used in conjunction with implant reconstruction⁹⁻¹¹ have provided a stable and viable approach to the treatment of osseous defects in the edentulous jaw. This article reports a successful case in which the use of bone grafting, placement of a titanium mesh bone crib,¹² and osseointegration of dental implants restored a patient back to a normal healthy dentition.

CLINICAL REPORT

Patient Background

A 55-year-old white woman in good general health was referred for treatment following traumatic injuries sustained in an automobile accident. Twenty-five years previously, the pa-

Functional and esthetic reconstruction of a patient with microgenia who sustained traumatic injury was successfully accomplished using Brånemark System osseointegrated implants (Nobel Biocare USA, Inc., Yorba Linda, CA) to support a permanent dental prosthesis following mechanical and biologic reconstruction of the anterior mandible and chin. A 25-year-old glycine chin implant previously used for facial esthetic enhancement had eroded the anterior cortical plate and migrated through the medullary bone, compressing the periosteum into the apex of the anterior tooth roots. Further destruction of the lingual cortex

with risk of fracture was imminent. After removal of the chin implant, a cancellous bone graft was held in place with a titanium mesh frame. The prosthetic rehabilitation consisted of two phases of mandibular implant placement followed by the construction of a porcelain-fused-to-gold implant-supported fixed prosthesis, restoring the occlusal vertical dimension as well as appropriate lip support. Restoration of function was superior to the pretreatment condition. (Implant Dent 2005;14:221-226)

Key Words: osseointegration, dental implants, bone graft, titanium mesh bone crib, glycine chin implant

tient had been diagnosed with microgenia and had undergone facial aesthetic surgical treatment involving placement of a hard glycine chin implant. Extraoral examination revealed slight ecchymosis in the anterior mandible with swelling and tenderness upon palpation. Intraorally, the traumatic impact had fractured the complete removable denture used to restore the edentulous maxilla. The mandibular arch was partially edentulous in the posterior, where it had been restored with a removable partial denture. Although emergency splinting had been performed immediately following the accident in an attempt to stabilize the avulsed and partially avulsed teeth, the mandibular prosthesis was no longer functional as a result of the changed alignment of the mobile teeth.

Examination with lateral cephalometric, panoramic, and intraoral peri-

apical radiographs revealed dentition that had been traumatized from the left mandibular first premolar to the right mandibular canine (Fig. 1). Widened periodontal ligaments and horizontal bone loss were consistent with the recent history and clinical findings. Furthermore, a radiolucent area approximately 50-mm wide and 20-mm high was noted apical to the roots of the remaining teeth. The lateral cephalometric film also showed an invasive resorptive process through the anterior cortical plate and underlying medullary bone in the symphysis as a result of the hard silicon chin implant being pressed by the perioral muscles into the bone. A computerized axial tomography of the mandible revealed the precise position of the hard glycine implant and the degree of erosive destruction present (Fig. 2).

*Prosthodontist, Private Practice, Prosthodontics Intermedica, Ft. Washington, PA; Director, Institute for Facial Esthetics, Fort Washington, PA.

†Prosthodontist, Private Practice, Prosthodontics Intermedica, Ft. Washington, PA; Staff Prosthodontist, Department of Veterans Affairs Medical Center, Philadelphia, PA.

‡Private practice, Melbourne, FLA; Consultant to the Institute for Facial Esthetics, Ft. Washington PA.

§Biomedical Engineer and Research Director, Prosthodontics Intermedica, Ft. Washington, PA.

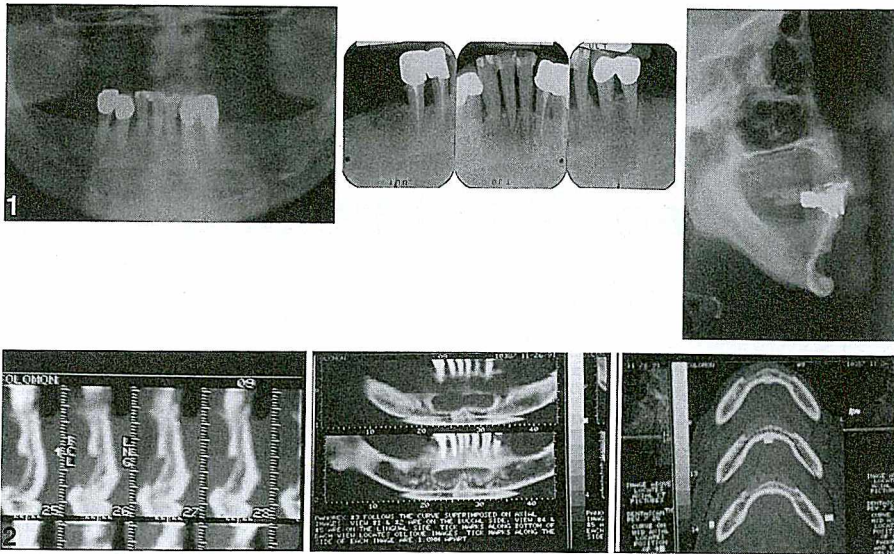


Fig. 1. Preoperative radiographs showing periodontal breakdown of lower anterior teeth and defect of labial cortical plate of anterior mandible created by chin implant.

Fig. 2. Computerized tomography of mandible showing destruction of labial cortical plate of mandible caused by chin implant.

Facial esthetic analysis confirmed microgenia and the need for facial rehabilitation.

MULTIDISCIPLINARY TREATMENT PLAN AND PROCEEDINGS

A team consisting of a board-certified plastic surgeon, a board-certified prosthodontist, and auxiliary personnel planned a two-phase treatment process to address the traumatic insult to the chin implant and rehabilitate the injured dentition using a nonremovable implant-supported prosthesis. The alternative to this process would have been the use of a complete removable denture or an implant-retained overdenture. However, a fixed prosthesis allowed for achievement of the most stable and functional prosthetic result.

Phase 1 addressed stabilization of the occlusal scheme and restoration of the lost occlusal vertical dimension. In the mandible, the hopeless teeth were removed, with the exception of the left first premolar and right canine. These teeth were used to support a provisional fixed partial denture. At the same time, 6 titanium dental implants (Brånemark System; Nobel Biocare USA, Inc., Yorba Linda, CA) were placed, 3 in each of the mandibular posterior edentulous areas and allowed to heal for 3 months (Fig. 3).

Surgical intervention in the anterior mandible then occurred. With the patient under general anesthesia, an extraoral incision was made below the chin in the crease line. The platysma muscle was sharply dissected off the mandible, and the periosteum was incised and elevated. The dissection elevated old scar tissue and revealed a fibrous encapsulation around the glycine implant. The chin implant was sectioned and removed, exposing an erosive fenestration of the lingual cortical plate in the area of the midline. The intact posterior wall of this osseous defect was roughened to increase vascularity for the bone graft.

The plastic surgeon shaped and contoured a titanium mesh bone crib to replicate the patient's previous chin contours. The upper edge of this bone crib was fastened to the labial cortex of the mandible using 0.5×6 mm and 0.5×5 mm microscrews (Howmedica; Stryker Howmedica Osteonics, Allendale, NJ) into previously drilled screw holes. A mixture of cancellous and cortical freeze-dried bone (Bio-Oss; Osteohealth, Shirley, NY) was packed into the defect and against the mesh tray. The mesh was then compressed against the mandible, and the inferior border of the tray was fastened with additional microscrews. The edge of the mesh was finally contoured with a scissor-like cutting in-

strument, similar to a bolt cutter, which produces no measurable heat from friction, and beveled to avoid any deformity created by the juncture of the mesh and the bone (Fig. 4). The wound was irrigated with saline, and a layered closure was accomplished with Vicryl 5-0 (Ethicon; Johnson & Johnson, Somerville NJ) and nylon 5-0 sutures (Ethicon; Johnson & Johnson). Foam tape and a circumferential head dressing (Caromed Int.; Byron Medical, Tucson, AZ) were applied after placement of plastic adhesive strips. The patient healed uneventfully, with complete recovery of muscle and sensory function.

Five months after the chin reconstruction, the patient returned for second-stage implant surgery. Local anesthesia was administered, and the 6 posterior Brånemark System implants were uncovered. All were determined to be osseointegrated. A conversion prosthesis^{13,14} was constructed using the existing anterior provisional restoration to maintain tooth position and occlusal vertical dimension. The acrylic crowns of the presurgical provisional restoration were filled to create pontics, and the natural teeth were extracted.

The labial mucosa was then dissected, revealing the titanium mesh tray. The superior microscrews were removed, and osteotomy sites into the grafted bone indicated firm osseous-like tissue. Six additional titanium dental implants (Brånemark System; Nobel Biocare USA, Inc.) were surgically placed according to the standard implant placement protocol into and through the area of the bone graft (Fig. 5). The standard 3-month healing time was extended by 3 months to permit further bone remodeling in the grafted region. The patient was evaluated at 1, 3, 5, and 6-month healing intervals.

Phase 2 began 6 months after placement of the anterior implants. The conversion prosthesis was disconnected from the 6 posterior implants. Using local anesthesia, second-stage surgery was completed for the 6 osseointegrated anterior implants. Appropriate abutments (Brånemark System; Nobel Biocare USA, Inc.) were placed, and the conversion prosthesis was modified to incorporate support

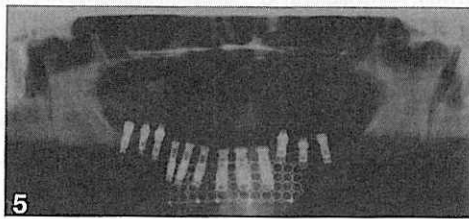
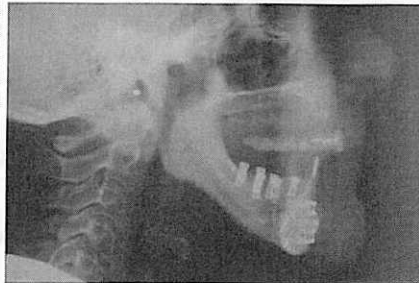
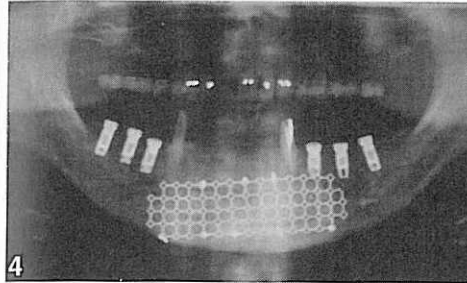
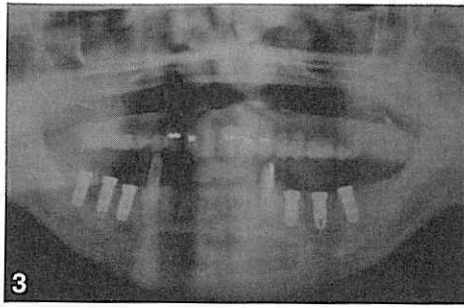


Fig. 3. Panoramic radiograph after placement of 6 implants in mandibular posterior region, extraction of 5 lower anterior teeth, and preparation of 2 teeth for wire-reinforced fixed provisional bridge.

Fig. 4. Lateral cephalometric and panoramic radiographs after removal of chin implant, bone grafting, and use of titanium mesh plate.

Fig. 5. Panoramic radiograph after placement of 6 implants into grafted bone in anterior mandible.

from the newly uncovered implants. Closure of the anterior mini-flaps was completed with Vicryl sutures (Ethicon; Johnson & Johnson).

A final impression was used to produce the master cast. The conversion prosthesis was fastened to the master cast to permit accurate articulation, preserving the precise occlusal vertical dimension and tooth position with which the patient had been functioning for the previous 10 months. One month later, the final porcelain fused-to-gold mandibular prosthesis was inserted in 1 piece and connected to the 12 osseointegrated Brånemark System implants (Fig. 6). At all follow-up visits, the prosthesis was stable. Radiographic examination confirmed that both the Brånemark System implants and the titanium mesh were firmly anchored in the bone more than 12 years after initiation of treatment (Fig. 7).

DISCUSSION

The need for closely coordinated, multidisciplinary treatment is a prerequisite for successful rehabilitation of patients with traumatic injury to the mandible. This treatment can often be extended as a result of complicating factors, such as previously placed implants requiring removal. When bone grafts are required, extended healing time may be necessary. For the treatment described here, the anterior mandibular implants were placed 5 months after the chin graft, when the site had not yet completely remodeled. However, the apex of those implants engaged original host mandible, as did the coronal portion of the implant. An additional 6-month healing period permitted further remodeling of the grafted area around the implants. Had autogenous bone been used, the bone remodeling likely would have occurred more rapidly. However, cre-

ation of a second surgical site brings with it potential risks and morbidity. In light of the bicortical stabilization of the anterior implants with a freeze-dried bone graft in the middle of the mandible, there was little biologic rationale for using autogenous bone. Furthermore, clinical and radiographic follow-up indicated that there was continued bone maintenance around the implants in the grafted area.

In a normal mandibular reconstruction, the use of 12 mandibular implants is not justified. However, this patient, who had a multiphase protocol, needed the use of all 12 mandibular implants. The placement of the first 6 implants in the posterior region resulted in a large anterior cantilever with the conversion prosthesis. After the chin implant and bone grafting sites healed, 6 anterior implants were placed to ensure that osseointegration occurred because of the unpredictability of the grafted anterior region of the mandible.

Another consideration was the interim use of the conversion prosthesis supported by the posterior implants. This treatment method permitted complete unloaded healing to occur around the anterior implants. It also provided an extended interval in which the anterior tooth position and occlusal vertical dimension could be evaluated. The details of the occlusal scheme were refined in the conversion prosthesis and then replicated in the final prosthesis. There is generally some concern about loading shorter posterior implants with an anterior cantilevered pontic section. However, radiographic analysis of the 6 posterior implants showed very limited marginal bone loss around these implants, comparable to what would have been expected in the anterior area. Long-term radiographic analysis will be required to monitor marginal bone levels for the initial 6 implants loaded 3 months after placement. Analysis will also be necessary to determine any changes in the bone levels, or density, in the anterior.

CONCLUSION

Facial and oral rehabilitation proved successful for an individual who had traumatic injury resulting in tooth loss and damage to a hard glycine chin implant. Brånemark System

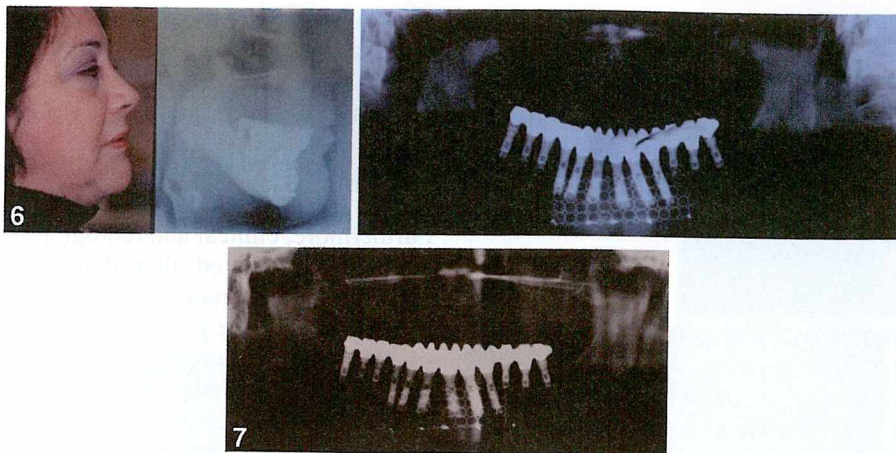


Fig. 6. Lateral facial view, and lateral cephalometric and panoramic radiographs following completion of mandibular implant reconstruction.

Fig. 7. Panoramic radiograph more than 12 years following initiation of treatment.

endosseous implants were used to accomplish this, along with reconstruction of the anterior mandible with a freeze-dried bone graft and titanium mesh bone crib. Stabilization of the bone crib with microscrews allowed the bone graft to heal without outward pressure. The titanium mesh also provided rigid support for the facial muscles and maintained an aesthetic profile.

Brånemark System implants placed first in the posterior edentulous area served as rigid anchors for a conversion prosthesis with anterior cantilevered pontics. The use of this prosthesis provided the opportunity to evaluate the occlusal vertical dimension as well as the aesthetics of the tooth positioning. Use of the conversion prosthesis also allowed additional implants to become osseointegrated in an environment free from any occlusal or functional pressure, either directly or through the mucosa. The overall success of this treatment program resulted from a closely coordinated, interdisciplinary treatment plan based on sound principles of bone morphology, physiology, and metabolism.

Disclosure

Dr. Balshi has a financial interest in Nobel Biocare USA, Inc., through

lecturing (honorarium), whose product, Brånemark System implants, is mentioned in this article. The other authors have no financial interest in any of the companies or products mentioned.

REFERENCES

1. Brånemark P-I, Hansson BO, Adell R, et al. Experience from a 10-year period: A description of a new procedure for rehabilitation of the edentulous patient and a clinical report of 235 jaws in 211 consecutive cases treated during 1965–1975 with installation of 1618 titanium fixtures supporting permanently bone anchored bridges. In: *Osseointegrated Implants in the Treatment of the Edentulous Jaw*. Stockholm, Sweden: Almqvist & Wiksell; 1977:39-94.
2. Adell R, Lekholm U, Rockler B, et al. A 15-year study of osseointegrated implants in the treatment of the edentulous jaw. *Int J Oral Surg*. 1981;10:387-416.
3. Brånemark P-I, Zarb GA. Tissue-integrated prostheses. In: Brånemark P-I, Zarb GA, Albrektsson T, eds. *Osseointegration in Clinical Dentistry*. Chicago, IL: Quintessence; 1985:211-232.
4. Balshi TJ. Converting patients with periodontally hopeless teeth to osseointegration prostheses. *Int J Periodontics Restorative Dent*. 1988;8:9-33.
5. Ericsson I, Lekholm U, Brånemark P-I, et al. A clinical evaluation of fixed-bridge restoration supported by the combination of teeth and osseointegrated titanium implants. *J Clin Periodontol*. 1986;13:307-312.
6. Sullivan DY. Prosthetic considerations for the utilization of osseointegrated fixtures in the partially edentulous arch. *Int J Oral Maxillofac Implants*. 1986;1:39-45.
7. Stevenson S. Enhancement of fracture healing with autogenous and allogeneic bone grafts. *Clin Orthop Relat Res*. 1998;355s:S239-S246.
8. Kline SN, Rimer SR. Reconstruction of osseous defects with freeze-dried allogeneic and autogenous bone. Clinical and histologic assessment. *Am J Surg*. 1983;146:471-473.
9. Lytle JL. Freeze-dried demineralized bone in dental implant reconstruction. *J Calif Dent Assoc*. 1994;22:47-51.
10. Piattelli A, Scarano A, Piattelli M. Microscopic and histochemical evaluation of demineralized freeze-dried bone allograft in association with implant placement: A case report. *Int J Periodontics Restorative Dent*. 1998;18:355-361.
11. Keller EE, Tolman D, Eckert S. Endosseous implant and autogenous bone graft reconstruction of mandibular discontinuity: A 12-year longitudinal study of 31 patients. *Int J Oral Maxillofac Implants*. 1998;13:767-780.
12. Giordano A, Brady D, Foster C, et al. Particulate cancellous marrow crib graft reconstruction of mandibular defects. *Laryngoscope*. 1980;90:2027-2036.
13. Balshi TJ. The Biotes conversion prosthesis: A provisional fixed prosthesis supported by osseointegrated titanium fixtures for restoration of the edentulous jaw. *Quintessence Int*. 1985;16:667-677.
14. Balshi TJ, Wolfinger GJ. Conversion prosthesis: A transitional fixed implant-supported prosthesis for an edentulous arch—A technical note. *Int J Oral Maxillofac Implants*. 1996;11:106-111.

Reprint requests and correspondence to:
 Stephen Balshi, MBE
 Suite 201
 467 Pennsylvania Avenue
 Ft. Washington, PA 19034
 Phone: 215-646-6334
 Fax: 215-643-1139
 E-mail: balshi2@aol.com



AUTOR(EN): Thomas J. Balshi, DDS*, Glenn J. Wolfinger, DMD**, Maria Claudia Pryszyk, DMD***, Stephen F. Balshi, MBE****. *Zahnprothetiker, privat praktizierender Arzt, Prosthodontics Intermedica, Ft. Washington, PA; Leiter, Institut für Gesichtsästhetische Behandlungen, Fort Washington, PA. **Zahnprothetiker, privat praktizierender Arzt, Prosthodontics Intermedica, Ft. Washington, PA; Zahnprothetischer Mitarbeiter, Abteilung für Veteranmedizinische Fragen im medizinischen Zentrum, Philadelphia, PA. ***Privat praktizierender Arzt, Melbourn, Fla, Berater des Instituts für Gesichtsästhetische Behandlungen, Ft. Washington, PA. ****Biomedizinischer Ingenieur und Forschungsleiter, Prosthodontics Intermedica, Ft. Washington, PA. Schriftverkehr: Stephen Balshi, BBE, 467 Pennsylvania Avenue, Suite 201, Ft. Washington, PA 19034. Telefon: 215-646-6334, Fax: 215-643-1139. eMail: balshi2@aol.com

AUTOR(ES): Thomas J. Balshi, DDS,* Glenn J. Wolfinger, DMD ** Maria Claudia Pryszyk, DMD,*** Stephen F. Balshi, MBE****. *Prostodontista, Práctica Privada, Prosthodontics Intermedica, Ft. Washington, PA; Director, Instituto de Estética Facial, Fort Washington, PA. **Prostodontista, Práctica Privada, Prosthodontics Intermedica, Ft. Washington, PA; Prostodontista, Centro Médico del Departamento de Asuntos de Veteranos, Filadelfia, PA. ***Práctica Privada, Melbourn, FL; Consultor del Instituto de Estética Facial, Ft. Washington, PA. ****Ingeniero Biomédico y Director de Investigación, Prosthodontics Intermedica, Ft. Washington, PA. Correspondencia a: Stephen Balshi, BBE, 467 Pennsylvania Avenue, Suite 201, Ft. Washington, PA 19034. 4 Teléfono: 215-4 646-4 6334, Fax: 215-4 643-4 1139. Correo electrónico: balshi2@aol.com

Gesichts- und Kieferwiederherstellung nach Trauma und fehlgeschlagener Kinnimplantationsbehandlung: eine Fallstudie

ZUSAMMENFASSUNG: Die funktionale wie ästhetische Rekonstruktion eines Patienten mit Mikrogenie nach traumatischer Verletzung wurde erfolgreich durch Anwendung von Knochengewebsintegrierenden Bränemark Implantaten zur Unterstützung einer dauerhaften Zahnprothetik herbeigeführt, nachdem vorab der vordere Unterkiefer sowie das Kinn mittels mechanischer wie auch biologischer Rekonstruktion aufgebaut wurden. Ein 25 Jahre altes Glycin-Kinn-Implantat, wie früher zur ästhetischen Gesichtswiederherstellung eingesetzt, hatte die Kortikalplatte im vorderen Kieferbereich unterhöhlt sowie das medulläre Knochengewebe durchwandert und dadurch die Knochenhaut in die Spitze der vorderen Zahnwurzeln gedrückt. Es drohte die weitere Zerstörung der Zungenseitigen Rinde verbunden mit einem Frakturrisiko. Nach Entfernung des Kinnimplantats wurde ein Transplantat der Substantia spongiosa mittels Titanmaschenrahmen an Ort und Stelle gehalten. Die prothetische Wiederherstellung erfolgte in zwei Behandlungsabschnitten zur Implantierung im Unterkieferbereich, gefolgt von dem Aufbau einer Porzellan-Gold-verschmolzenen Implantatgestützten festen Prothese, wodurch die vertikalen Okklusalausmaße und die entsprechende Lippenstütze wiederhergestellt werden konnten. Die funktionale Wiederherstellung wies gegenüber dem Ursprungszustand vor Behandlungsbeginn bessere Ergebnisse auf.

SCHLÜSSELWÖRTER: Knochengewebsintegration, Zahnimplantate, Knochengewebsstransplantat, Titanmaschenknochenverankerung, Glycin-Kinn-Implantat

Reconstrucción oral y facial luego del trauma y implante fallado del mentón: Informe de un caso

ABSTRACTO: La reconstrucción funcional y estética y de un paciente con microgenia que sufrió una lesión traumática se logró exitosamente usando implantes Bränemark oseointegrados para soportar una prótesis dental permanente luego de la reconstrucción mecánica y biológica de la mandíbula anterior y el mentón. Un implante de glicina del mentón de 25 años de edad usado previamente para mejorar la estética facial había erosionado la placa cortical anterior y migrado a través del hueso medular, apretando el periosteo en la punta de las raíces de los dientes anteriores. Una destrucción adicional de la corteza lingual con el riesgo de fractura era inminente. Después de la remoción del implante del mentón, un injerto de hueso canceloso se mantuvo en su lugar con un armazón de malla de titanio. La rehabilitación protésica consistió en dos fases de la colocación del implante mandibular seguido por la construcción de una prótesis fija apoyada con implantes de porcelana fundida en oro, restaurando la dimensión oclusal vertical así como el apoyo apropiado para el labio. La restauración de la función fue superior a la condición previa al tratamiento.

PALABRAS CLAVES: oseointegración, implantes dentales, injerto de hueso, cuna de hueso con malla de titanio, implante de glicina de mentón