



A Retrospective Analysis of 800 Brånemark System Implants Following the All-on-Four™ Protocol

Thomas J. Balshi, DDS, PhD, FACP,¹ Glenn J. Wolfinger, DMD, FACP,² Robert W. Slauch, BS,^{3,4} & Stephen F. Balshi, MBE⁵

¹Founder and Prosthodontist, PI Dental Center at the Institute for Facial Esthetics, Fort Washington, PA

²Prosthodontist, PI Dental Center at the Institute for Facial Esthetics, Fort Washington, PA

³Research Associate, PI Dental Center at the Institute for Facial Esthetics, Fort Washington, PA

⁴Dental Student, University of Maryland, Baltimore College of Dental Surgery, Baltimore, MD

⁵Director of Research, PI Dental Center at the Institute for Facial Esthetics; President, CM Prosthetics, Inc., Fort Washington, PA

The article is associated with the American College of Prosthodontists' journal-based continuing education program. It is accompanied by an online continuing education activity worth 1 credit. Please visit www.wileyhealthlearning.com/jopr to complete the activity and earn credit.

Keywords

Dental implant; tilted implant; osseointegration; maxilla; mandible; immediate loading.

Correspondence

Stephen Balshi, PI Dental Center at the Institute for Facial Esthetics, 467 Pennsylvania Ave., Ste. 201, Fort Washington, PA 19034. E-mail: balshi2@aol.com

The authors deny any conflicts of interest.

Accepted April 27, 2013

doi: 10.1111/jopr.12089

Abstract

Purpose: The purpose of this study was to retrospectively evaluate implant survival rates in patients treated with the All-on-Four™ protocol according to edentulous jaws, gender, and implant orientation (tilted vs. axial).

Materials and Methods: All Brånemark System implants placed in patients following the All-on-Four™ protocol in a single private practice were separated into multiple classifications (maxilla vs. mandible; male vs. female; tilted vs. axial) by retrospective patient chart review. Inclusion criteria consisted of any Brånemark System implant placed with the All-on-Four™ protocol from the clinical inception (May 2005) until December 2011. Life tables were constructed to determine cumulative implant survival rates (CSR). The arches, genders, and implant orientations were statistically compared with ANOVA.

Results: One hundred fifty-two patients, comprising 200 arches (800 implants) from May 2005 until December 2011, were included in the study. Overall implant CSR was 97.3% (778 of 800). Two hundred eighty-nine of 300 maxillary implants and 489 of 500 mandibular implants survived, for CSRs of 96.3% and 97.8%, respectively. In male patients, 251 of 256 implants (98.1%) remain in function while 527 of 544 implants (96.9%) in female patients survived. Regarding implant orientation, 389 of 400 tilted implants and 389 of 400 axial implants osseointegrated, for identical CSRs of 97.3%. All comparisons were found to be statistically insignificant. The prosthesis survival rate was 99.0%.

Conclusions: The results from this study suggest that edentulous jaws, gender, and implant orientation are not significant parameters when formulating an All-on-Four™ treatment plan. The high CSRs for each variable analyzed demonstrate the All-on-Four™ treatment as a viable alternative to more extensive protocols for rehabilitating the edentulous maxilla or mandible.

Immediate loading of all-acrylic, implant-supported prostheses for maxillary and mandibular arches has been shown to provide numerous clinical advantages to patients and dentists.¹⁻⁶ Patients are able to receive fixed, full-arch restorations the same day as implant placement, providing esthetics, comfort, and limited function during the 3- to 6-month healing phase, all while achieving high implant survival rates.

Traditional treatment plans typically called for a large number of implants placed in fairly vertical positions throughout the entire arch.⁷ However, the posterior maxilla and mandible may have several limitations associated with this approach. In the

mandible, the inferior alveolar nerve and associated structures may provide minimal bone for implant anchorage or prevent the placement of implants distal to the mental foramina altogether. In the maxilla, it is not uncommon to see resorption in the posterior regions or enlargement of the sinuses.⁸

In the event that posterior implants could not be placed and to compensate for these biologic limitations, a lengthy cantilever distal to the terminal implant was typically needed to provide patients with adequate posterior dentitions; however, extensive posterior cantilevers are biomechanically unfavorable due to increased occlusal forces.⁹⁻¹¹ Alternative methods for

the maxilla, such as sinus augmentations¹² or pterygomaxillary implants^{13,14} have been used to establish adequate stability for posterior implants and decreased cantilevers. Sinus lifts often prolong treatment time in order for graft maturation to occur.

The introduction of tilted implants^{8,15} has provided a significant alternative for restoration of maxillary and mandibular posterior segments without bone grafting. According to Krekmanov *et al*,⁸ posterior tilting of distal implants will reduce cantilever lengths, broaden the prosthetic base, and improve implant-to-bone surface areas because longer implants can be used. In their study, tilted implants increased prosthesis length by an average of 6.6 mm in the mandible and 9.3 mm in the maxilla.⁸ This resulted in better biomechanics.

The All-on-FourTM concept uses the simplicity of posterior tilted implants to create a full-arch restoration that can be less clinically invasive for patients. The concept was initially proposed in a 2003 study¹⁶ as a treatment plan for mandibles, since immediate function had become widely accepted in that region. The design consisted of a fixed prosthesis supported by four endosseous implants: two axial implants in the anterior segment and one distal implant on each posterior segment tilted posteriorly. All implant apices are to engage cortical bone anterior to the mental foramina. The increased anterior/posterior spread¹¹ from the tilted implants generally provides first molar occlusion for patients with short cantilevered segments.

Edentulous maxillary jaws were initially thought to provide a significant challenge to the protocol, as maxillary bone is known to have decreased bone density, especially relative to mandibular bone.¹⁶ However, Maló *et al*¹⁷ demonstrated in 2005 that maxillary All-on-FourTM rehabilitations had a cumulative survival rate (CSR) of 97.6%, approximately 1% higher than their 2003 study in the mandible (96.7% CSR).¹⁶ More recent studies^{18,19} have further reinforced the viability of the All-on-FourTM protocol as a treatment alternative for both dental arches.

The purpose of this study was to retrospectively determine if there was a significant difference in implant survival rates relative to edentulous jaws, patient gender, and implant orientation following the All-on-Four protocol in a single private practice. Implant failures based on bone quality²⁰ and smoking habits were also measured. The null hypothesis for this study was there would be no significant differences relative to implant CSRs (outcome variable) in edentulous jaws, gender, and implant orientation.

Materials and methods

A retrospective chart review was performed for all patients who received Brånemark System implants (NobelBiocare, Yorba Linda, CA) following the All-on-FourTM protocol in a single private practice (PI Dental Center, Fort Washington, PA). Data compilation was performed using an implant tracking database system (Implant Tracker; Hartford, CT). As this research involved the study of existing records, and the records were made anonymous to the investigators, IRB approval was not sought. Inclusion criteria consisted of any implant placed in the practice in an All-on-FourTM treatment from May 2005 (the clinical inception of All-on-FourTM) until December 2011. On the day of surgery, implants were placed and immediately loaded with all-acrylic resin, screw-retained interim prostheses (Teeth in

Table 1 Master life table of implants

Period	# of implants	# of failures	Survival rate (%)	Cumulative survival rate (%)
0 to 3 months	800	12	98.5	98.5
3 to 6 months	776	4	99.6	98.0
6 to 9 months	737	1	99.9	97.9
9 to 12 months	660	5	99.3	97.3
1 year	588	0	100.0	97.3
2 years	375	0	100.0	97.3
3 years	168	0	100.0	97.3
4 years	93	0	100.0	97.3
5+ years	40	0	100.0	97.3

a Day®). Approximately 3 months postsurgery, patients presented for definitive impressions, enabling the construction of highly accurate master casts used for the fabrication of the definitive prostheses. The definitive prostheses were delivered 4 to 8 weeks later.

Regarding failed implants, replacement implants were excluded from the study. A surviving (or osseointegrated) implant was defined as an implant that remained in function and had no clinical mobility or adverse symptoms at the time of definitive impressions. In contrast, an implant failure was defined as an implant that did not achieve osseointegration, as demonstrated by patients reporting pain or discomfort or by clinical mobility determined by the clinician. This resulted in eventual removal of the failed implant from the patient.

All implants were classified into three groups: maxillary vs. mandibular; male vs. female patients; and tilted (posterior) vs. axial (anterior). Separation into each group was conducted by reviewing postoperation radiographs and clinical notes. Life tables were constructed to determine the CSRs. MANOVA was performed in Microsoft Excel (Microsoft Inc., Redmond, WA) to compare the significance in the CSRs between the edentulous jaws, gender, and implant orientation groupings.

The number of failures based on implant type, bone quality, and smoking habits were also calculated. Bone quality was determined subjectively by the prosthodontist placing the implants, based on resistance to drilling and clinical experience. Bone quality was quantified by types 1 to 4 according to the Lekholm and Zarb²⁰ criteria. Smoking habits were recorded from the initial patient work-up.

Results

One hundred fifty-two patients with 200 dental arches (800 implants) were included in this study. Of the Brånemark System implants placed following the All-on-FourTM protocol during the study period, 778 of the 800 implants successfully osseointegrated, resulting in a CSR of 97.3% (Table 1). Relative to edentulous jaw locations, 289 of the 300 (96.3%) maxillary implants placed remained in function (Table 2); mandibular implants had a survival rate of 97.8% (489 of 500, Table 3). Regarding gender, male patients had 251 of the 256 (98.1%) implants successfully osseointegrate (Table 4), and female patients had 527 of the 544 implants integrate (96.9%, Table 5). In the implant orientation groups, the tilted and axial implants had equal sample sizes (n = 400); CSRs both equaled 97.3%

Table 2 Life table for implants in the maxillary arch

Period	# of implants	# of failures	Survival rate (%)	Cumulative survival rate (%)
0 to 3 months	300	6	98.0	98.0
3 to 6 months	290	1	99.7	97.7
6 to 9 months	281	1	99.6	97.3
9 to 12 months	248	3	98.9	96.3
1 year	222	0	100.0	96.3
2 years	130	0	100.0	96.3
3 years	39	0	100.0	96.3
4 years	19	0	100.0	96.3
5+ years	8	0	100.0	96.3

Table 3 Life table for implants in the mandibular arch

Period	# of implants	# of failures	Survival rate (%)	Cumulative survival rate (%)
0 to 3 months	500	6	98.8	98.8
3 to 6 months	486	3	99.4	98.2
6 to 9 months	456	0	100.0	98.2
9 to 12 months	412	2	99.5	97.8
1 year	366	0	100.0	97.8
2 years	245	0	100.0	97.8
3 years	129	0	100.0	97.8
4 years	74	0	100.0	97.8
5+ years	32	0	100.0	97.8

Table 4 Life table for implants in male patients

Period	# of implants	# of failures	Survival rate (%)	Cumulative survival rate (%)
0 to 3 months	256	3	98.8	98.8
3 to 6 months	241	2	99.2	98.1
6 to 9 months	223	0	100.0	98.1
9 to 12 months	203	0	100.0	98.1
1 year	178	0	100.0	98.1
2 years	100	0	100.0	98.1
3 years	40	0	100.0	98.1
4 years	16	0	100.0	98.1
5+ years	8	0	100.0	98.1

Table 5 Life table for implants in female patients

Period	# of implants	# of failures	Survival rate (%)	Cumulative survival rate (%)
0 to 3 months	544	9	98.3	98.3
3 to 6 months	535	2	99.6	98.0
6 to 9 months	514	1	99.8	97.8
9 to 12 months	457	5	99.0	96.9
1 year	410	0	100.0	96.9
2 years	275	0	100.0	96.9
3 years	128	0	100.0	96.9
4 years	77	0	100.0	96.9
5+ years	32	0	100.0	96.9

Table 6 Life table for tilted implants

Period	# of implants	# of failures	Survival rate (%)	Cumulative survival rate (%)
0 to 3 months	400	6	98.5	98.5
3 to 6 months	388	3	99.2	97.8
6 to 9 months	368	1	99.7	97.5
9 to 12 months	329	1	99.7	97.3
1 year	294	0	100.0	97.3
2 years	188	0	100.0	97.3
3 years	85	0	100.0	97.3
4 years	47	0	100.0	97.3
5+ years	20	0	100.0	97.3

Table 7 Life table for axial implants

Period	# of implants	# of failures	Survival rate (%)	Cumulative survival rate (%)
0 to 3 months	400	6	98.5	98.5
3 to 6 months	388	1	99.7	98.3
6 to 9 months	369	0	100.0	98.3
9 to 12 months	331	4	98.9	97.3
1 year	294	0	100.0	97.3
2 years	187	0	100.0	97.3
3 years	83	0	100.0	97.3
4 years	46	0	100.0	97.3
5+ years	20	0	100.0	97.3

Table 8 Number of failures based on implant dimension

Implant dimension	Number of failures	Failure rate for specific implant dimension (%)
Mk III 3.75 × 13 mm	2	6.3
Mk III 3.75 × 15 mm	1	1.6
Mk III 4.0 × 13 mm	1	4.5
Mk III 4.0 × 15 mm	3	23.7
Mk IV 4.0 × 10 mm	2	2.8
Mk IV 4.0 × 13 mm	2	2.0
Mk IV 4.0 × 15 mm	6	1.6
Mk IV 4.0 × 18 mm	5	3.2

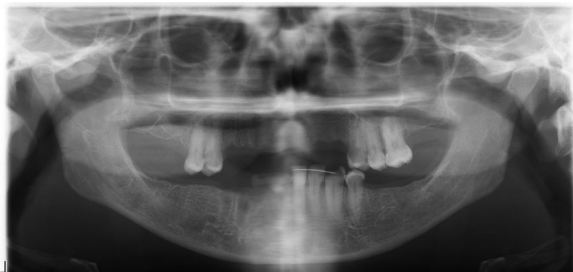
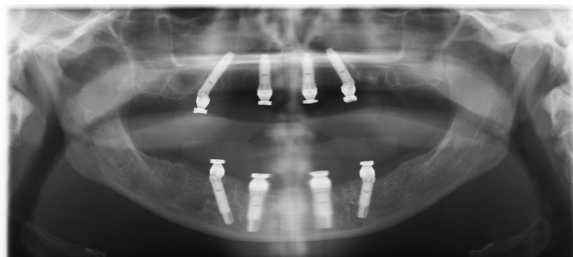
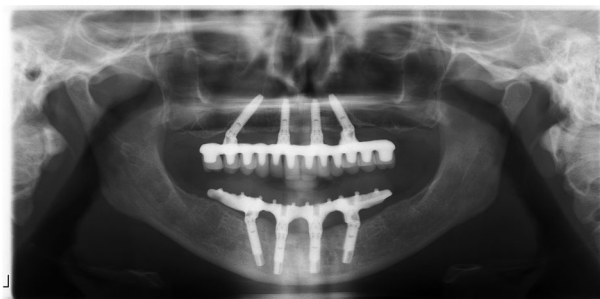Table 9 Number of failures based on bone quality

Bone quality	Number of implants in bone type	Number of failures	Failure percentage (%)
Type 1	25	1	4.0
Type 2	239	10	4.1
Type 3	479	11	2.3
Type 4	57	0	0.0

(Tables 6, 7). The Mark III 4.0 × 15 mm implant had the highest failure rate (23.7%) of all specific implants used in the study (Table 8). Type 2 bone had the highest failure rate (4.1%) of all bone qualities (Table 9). Relative to smoking, eight implants failed in two patients who were documented as smokers (Table 10). The prosthesis survival rate was 99.0%. The CSR comparisons between dental arch, gender, and implant

Table 10 Number of failures based on smoking status

Smoking status	Number of implants	Number of failures	Failure percentage (%)
Nonsmoker	668	14	2.1
Smoker	132	8	6.1

**Figure 1** Preoperative panoramic radiograph of the patient elected for maxillary and mandibular All-on-Four™ implant rehabilitation.**Figure 2** Postoperative panoramic radiograph following All-on-Four™ implant rehabilitation in the maxilla and mandible. The implants were immediately loaded with all-acrylic resin interim prostheses.**Figure 3** Panoramic radiograph following delivery of definitive prostheses for the maxilla and mandible. The maxillary CM Prosthesis consists of a milled titanium framework with individual lithium disilicate crowns. The mandibular prosthesis is a milled titanium framework veneered with acrylic resin and denture teeth.

orientation were found to be statistically insignificant (MANOVA; $p > 0.05$). Examples of preoperation and post-operation radiographs are depicted in Figures 1 and 2. Figure 3 illustrates a radiograph following delivery of the definitive prostheses in the same patient.

Discussion

Immediate occlusal loading of edentulous jaws following the All-on-Four™ protocol has been demonstrated to provide patients with functional and esthetic screw-retained interim prostheses the same day of surgery.⁵ Alternative protocols such as sinus augmentations are available to patients and may obtain the same definite treatment outcomes as the All-on-Four™ treatment protocols; however, these protocols require longer healing periods, and it may not be possible to employ an immediate loading protocol. The use of tilted implant placement protocols has allowed dental practitioners to use the All-on-Four™ concept, which provides a viable alternative to restore dentitions in edentulous maxillae and mandibles. Due to the increased frequency of this protocol, as reported in multiple publications,^{16-19,26} it is important to determine if specific variables such as dental arch, gender, or implant orientation produce any significant differences in the success of the procedure.

Regarding dental arches reconstructed with this specific protocol, this study found that the mandible produced a CSR 1.5% higher than (Table 3), but not statistically different relative to the maxilla (Table 2). The authors of this report suggest if cortical bone is present, implants may osseointegrate despite the arch rehabilitated. With gender, similar CSRs were obtained in male patients (98.1%) and female patients (96.9%); these results were also statistically insignificant.

Tilted and axial implants had identical CSRs (Tables 6, 7). In a 2000 study,⁸ axial implants had a lower CSR in the maxilla (90.2%) than tilted implants did (95.7%); however, the implants were not immediately loaded. The authors of this article mentioned that the increased contact between cortical bone and tilted implants may be the reason for the percentage difference. The same reason could account for the high CSR reported in the current study.

In a 2011 report by Butura *et al*,¹⁸ tilted implants had a CSR of 99.8% and axial implants a CSR of 99.5% in the mandible. A study by Graves *et al*¹⁹ in 2011 reported a CSR of 97.5% in the maxilla. In both studies, the surgical procedures for implant placement were similar, and all implants were immediately loaded with fixed all-acrylic resin screw-retained prostheses. The higher CSRs shown from these 2011 reports^{18,19} and this current study, when compared to the original research conducted on tilted implants,⁸ could be due to inception of the TiUnite^{21,22} surface implant. Other possible explanations for the higher CSRs are related to immediate loading protocols and biomechanics: the splinting effect and cross-arch stabilization. The authors of the current study believe it is imperative that all implants be splinted together in the immediate loading protocol to distribute the forces throughout the entire arch. Cross-arch stabilization of immediately loaded implants limits micromotion to the individual implants. With optimal load distribution through splinting, single implants avoid overload that can lead to micromotion and prevent osseointegration. Relative to edentulous jaws, gender, and implant orientation results, it is suggested there are no biological or mechanical disadvantages regarding these variables when formulating an All-on-Four™ treatment plan when the aforementioned splinting condition exists.

At 3 months postsurgery, patients were scheduled for definitive impressions to enable fabrication of the definitive prostheses. Delivery of the definitive prosthesis typically occurred 1 to 2 months later (4 to 5 months postoperative). In this study, five implants (in two patients) failed in the 9- to 12-month timeframe after the definitive prostheses were already delivered; however, in both cases, all-acrylic resin definitive prostheses were used. The all-acrylic resin prosthesis was a cost-effective alternative to a metal framework for a definitive prosthesis as demonstrated by Malo *et al.*²⁶ Thus, a simple manipulation was achieved by removing the old abutment cylinders corresponding to the failed implant sites and adding additional acrylic resin to reposition the new implant orientations on the original prostheses. If this occurred with the definitive prosthesis containing a metal framework, the framework must be stripped, sectioned, and repositioned. The prosthesis survival rate for this study was 99.0%. Only two patients required a reversion back to a removable denture, due to all four implants failing to maintain osseointegration. In one of these, the patient (female, 41 years) presented herself with a periodontally compromised maxillary dentition. An All-on-FourTM fixed immediate prosthesis was the treatment plan presented and accepted by the patient to restore the maxillary dentition. Type 3 bone²⁰ was observed at the time of implant placement. Ten months after surgery, none of the four implants maintained osseointegration, suggesting there may be a systemic issue in the bone remodeling process. It was at this time that clinical mobility was noted for all implants. The patient was a heavy smoker and refused to quit, and continued to display poor oral hygiene, which may also have been possible mechanisms of implant failure.

In the other specific case, the patient (female, 45 years) presented with a chief complaint of a loose mandibular denture. The patient displayed unusual jaw and muscular movements that were considered a maladaptive response to the loose mandibular denture. After the implants were placed and the mandibular prosthesis was secured, the unusual jaw and muscular movements continued. The extreme occlusal and lateral forces caused micromotion to the immediately loaded prosthesis and prohibited osseointegration from occurring, leading to fibrous encapsulation. The patient was referred to a neurologist for evaluation and was later diagnosed with oromandibular dystonia. The patient never returned for replacement of the lost implants and prosthesis.

When implants fail in the All-on-FourTM protocol, tilted (posterior) implants are often more difficult to replace than axial (anterior) implants. For example, a mandibular receptor site more distal to the original site is likely to be anatomically challenging due to the location of the mental foramina; a receptor site more mesial will decrease the anterior/posterior spread. An implant site buccal or lingual to the original site may be acceptable if there is sufficient alveolar ridge width for implant placement. In the maxilla, similar challenges exist for the tilted (posterior) implants relative to the anterior wall of the maxillary sinus. In both dental arches, axial implants placed in the anterior segments have more freedom for clinicians to move the new implant sites mesial or distal when compared to previous sites.

Prior research^{9,23-25} has shown protocols that use pterygomaxillary implants or a large number of implants have success

rates well into the 90% range; however, factors such as the amount of occlusal surface areas differ when comparing the All-on-FourTM concept to previous concepts. Due to their ability to provide posterior maxillary support, pterygomaxillary implants typically provide patients with second molar occlusion with no distal cantilevers being needed. The All-on-FourTM method typically provides first molar occlusion, often with the use of a distal cantilever.

The high overall CSR for the All-on-FourTM concept (97.3%, Table 1) in this study demonstrates similar success rates when compared with these alternative protocols. The data in this study suggest that the All-on-FourTM protocol as described is a treatment plan that produces similar, if not higher, success rates and allows clinicians to achieve the satisfactory immediate functional and esthetic outcomes. There are also great advantages afforded to patients in terms of postoperative comfort and decrease in overall treatment time.

Conclusion

The All-on-FourTM concept provides a predictable method to restore edentulous jaws. The high implant survival rates relative to edentulous jaws, patient gender, and implant orientation when following the All-on-FourTM protocol suggests that the procedure is a viable alternative to restore dentitions for edentulous patients.

Acknowledgment

The authors would like to thank Chris Raines for her assistance in data collection using Implant Tracker; the staff of the PI Dental Center for their kind and gentle treatment of the patients; and Dr. Brian Wilson and Mr. Dan Delaney for their support in the administration of general anesthetics, when needed.

References

1. Zarb GA, Zarb FL, Schmitt A: Osseointegrated implants for partially edentulous patients. *Dent Clin North Am* 1987;31:457-472
2. Balshi TJ, Wolfinger GJ: Immediate loading of Brånemark implants in edentulous mandibles. A preliminary report. *Implant Dent* 1997;6:83-88
3. Schnitman PA, Wöhrle PS, Rubenstein JE, et al: Ten-year results for Brånemark implants immediately loaded with fixed prostheses at implant placement. *Int J Oral Maxillofac Implants* 1997;2:495-503
4. Tarnow D, Entiaz S. Class I: Immediate loading of threaded implants at stage I surgery in edentulous arches: ten consecutive case reports with 1-5 year data. *Int J Oral Maxillofac Implants* 1997;12:319-324
5. Balshi TJ, Wolfinger GJ: Teeth in a day. *Implant Dent* 2001;10:231-233
6. Randow K, Ericsson I, Nilner K, et al: Immediate functional loading of Brånemark dental implants: an 18-month clinical follow-up study. *Clin Oral Impl Res* 1999;110:8-15
7. Block MS, Winder JS: Method for insuring parallelism of implants placed simultaneously with maxillary sinus bone grafts. *J Oral Maxillofac Surg* 1991;49:435-437
8. Krekmanov L, Kahn M, Rangert B, et al: Tilting of posterior mandibular and maxillary implants for improved prosthesis support. *Int J Oral Maxillofac Implants* 2000;15:405-414

9. Bahat O: Brånemark system implants in the posterior maxilla: clinical study of 660 implants followed for 5 to 12 years. *Int J Oral and Maxillofac Implants* 2000;15:646-653
10. Rangert B, Jemt T, Jörnérus I: Forces and moments on Brånemark implants. *Int J Oral Maxillofac Implants* 1989;4:241-247
11. English C: Biomechanical concerns with fixed partial dentures involving implants. *Implant Dent* 1993;2:221-242
12. Balshi TJ: Preventing and resolving complications with osseointegrated implants. *Dent Clinics North Am* 1989;33:821-868
13. Tulasne JF: Osseointegrated fixtures in the pterygoid region. In Worthington P, Brånemark PI (eds): *Advanced Osseointegration Surgery, Applications in the Maxillofacial Region*. Chicago, Quintessence, 1992, pp. 182-188
14. Graves SL: The pterygoid plate implant. A solution for restoring the poster maxilla. *Int J Periodont Rest Dent* 1994;14:512-523
15. Aparicio C, Arevalo X, Ouzzani W, et al: A retrospective clinical and radiographic evaluation of tilted implants used in the treatment of the severely resorbed maxilla. *Appl Osseo Res* 2000;3:17-21
16. Maló P, Rangert B, Nobre M: "All-on-4" immediate-function concept with Brånemark system implants for completely edentulous mandibles: a retrospective clinical study. *Clin Implant Dent Relat Res* 2003;5 Suppl 1:2-9
17. Maló P, Rangert B, Nobre M: "All-on-4" immediate-function concept of Branemark system implants for completely edentulous maxilla: a 1-year retrospective clinical study. *Clin Implant Dent Relat Res* 2005;7 Suppl 1:S88-S94
18. Butura C, Galindo D, Jensen O: Mandibular all-on-four therapy using angled implant: a three year clinical study of 857 implants in 219 jaws. *Oral Maxillofac Surg Clin North Am* 2011;23:289-300
19. Graves S, Mahler BA, Javid D, et al: Maxillary all-on-four therapy using angled implants: a 16 month clinical study of 1110 implants in 276 jaws. *Dent Clin North Am* 2011;55:779-794
20. Lekholm U, Zarb G: Patient selection and preparation. In Brånemark P-I, Zarb G, Albrektsson T (eds): *Tissue-Integrated Prostheses: Osseointegration in Clinical Density*. Chicago, Quintessence, 1985, pp. 199-220
21. Bahat O: Technique for placement of oxidized titanium Implants in compromised maxillary bone: prospective study of 290 implants in 126 consecutive patients followed for a minimum of 3 years after loading. *Int J Oral Maxillofac Implants* 2009;24:325-334
22. Balshi SF, Wolfinger GJ, Balshi TJ: Analysis of 164 titanium oxide-surface implants in completely edentulous arches for fixed prosthesis anchorage using the pterygomaxillary region. *Int J Oral Maxillofac Implants* 2005;20:946-952
23. Kinsel RP, Liss M: Retrospective analysis of 56 edentulous dental arches restored with 344 single-stage implants using an immediate loading fixed provisional protocol: statistical predictors of implant failure. *Int J Oral Maxillofac Implants* 2007;22:823-830
24. Degidi M, Piattelli A: A 7-year follow-up of 93 immediately loaded titanium dental implants. *J Oral Implantol* 2005;1:25-31
25. Balshi TJ, Wolfinger GJ, Balshi SF: Analysis of 356 pterygomaxillary implants in edentulous arches for fixed prosthesis anchorage. *Int J Oral Maxillofac Implants* 1999;14:398-406
26. Malo P, de Araujo Nobre M, Lopes A, et al: "All-on-4" immediate-function concept for completely edentulous maxillae: a clinical report on the medium (3 years) and long-term (5 years) outcomes. *Clin Implant Dent Relat Res* 2012; 14 Suppl 1:e139-e150