

## Single, Tuberosity-Osseointegrated Implant Support for a Tissue-Integrated Prosthesis



Thomas J. Balshi, DDS\*

### Abstract

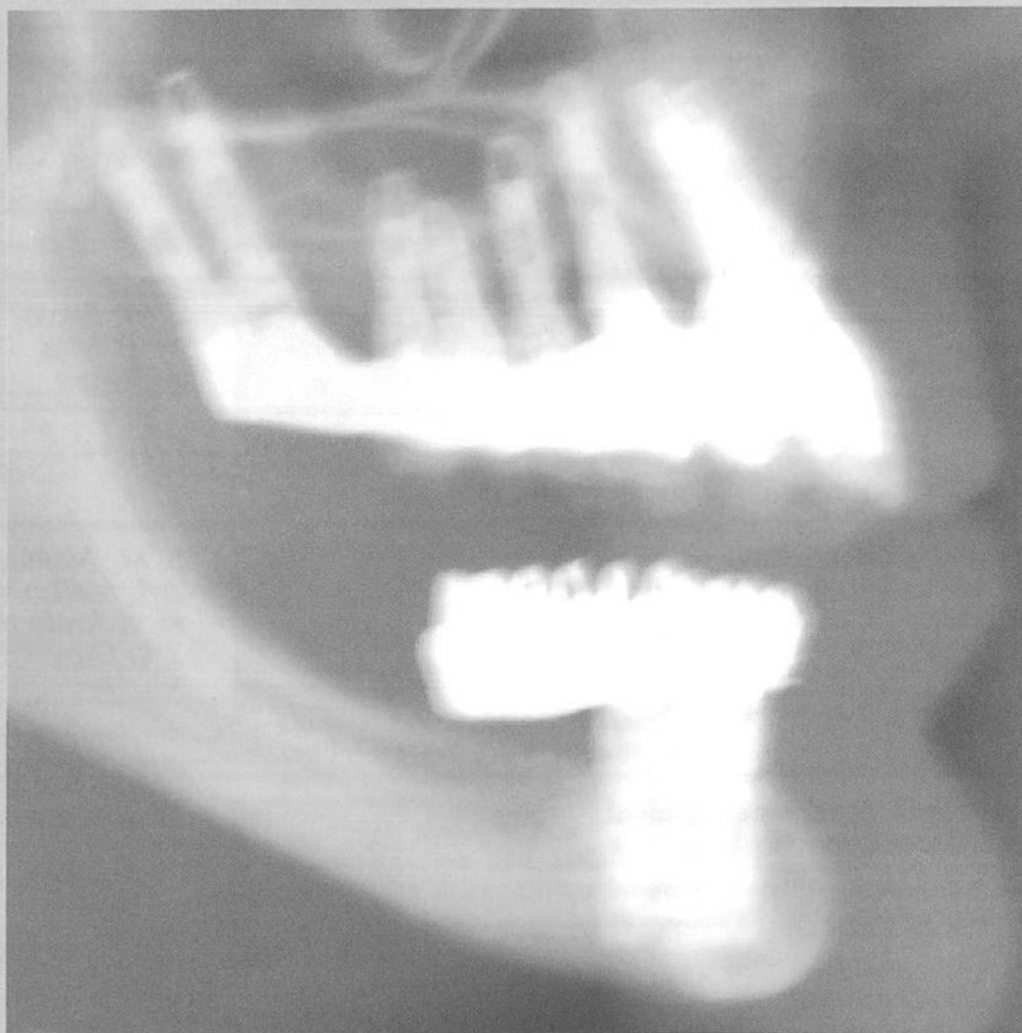
*Fixed prosthodontic rehabilitation can be accomplished in partially edentulous patients whose maxillary antrum prohibits successful placement of multiple fixtures. A single posterior fixture is placed in the tuberosity region to support a tissue-integrated prosthesis directly connected to a periodontally sound anterior abutment tooth. The treatment planning considerations and surgical aspects are described, and a case report is used to illustrate the technique. (Int J Periodont Rest Dent 1992; 12:345-357.)*

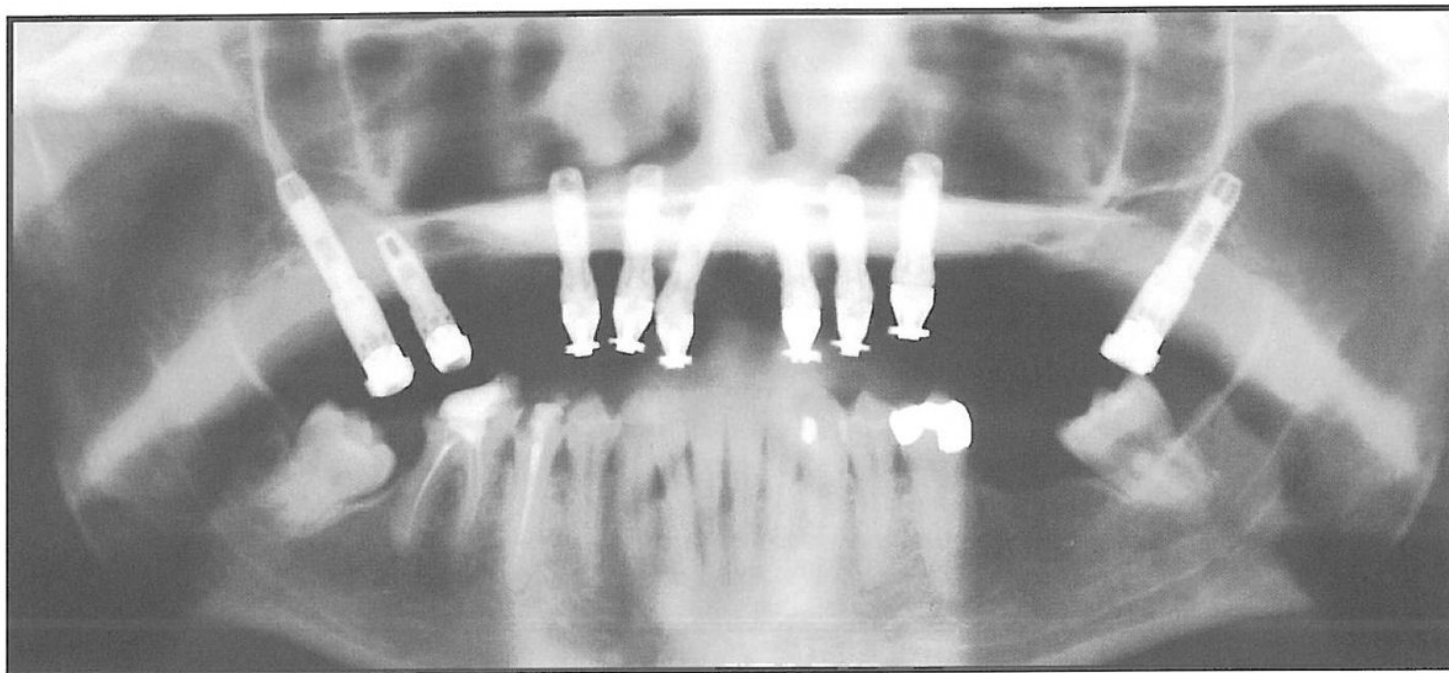
The routine use of commercially pure titanium screw fixtures as osseointegrated implant abutment support for fixed prosthodontic restorations requires careful presurgical planning and special postinstallation prosthetic management. Initially, Brånemark did not advocate the routine use of titanium fixtures in the posterior maxilla (personal communication, June 1986). However, ongoing clinical trials, conducted over a 36-month period and including more than 30 patients with tuberosity fixture installation, indicate that the tuberosity or pterygomaxillary area may be a suitable receptor site for titanium fixtures to osseointegrate. In another clinical analysis, more than 200 pterygomaxillary fixtures were successfully placed and currently support fixed prostheses.<sup>1</sup>

The ability to use available tuberosity bone for fixture installation provides posterior abutment support for a fixed prosthesis in areas frequently compromised by enlarged maxillary antrums and an inadequate quantity of alveolar bone. Successful use of osseointegrated fixtures in this manner can preclude the necessity for sinus elevation procedures and bone grafting when a fixed tissue-integrated prosthesis is prescribed. Tuberosity fixtures have provided successful abutment support for a variety of tissue-integrated prosthesis forms, including:

1. Multifixture complete-arch fixed prostheses (Figs 1 and 2)
2. Complete removable overdentures with fixed retention bars (Fig 3)
3. Multiple fixture-supported restorations independent of the natural dentition (Fig 4)
4. Terminal abutments for partial fixed prostheses connected to the natural dentition, as primarily described in this paper

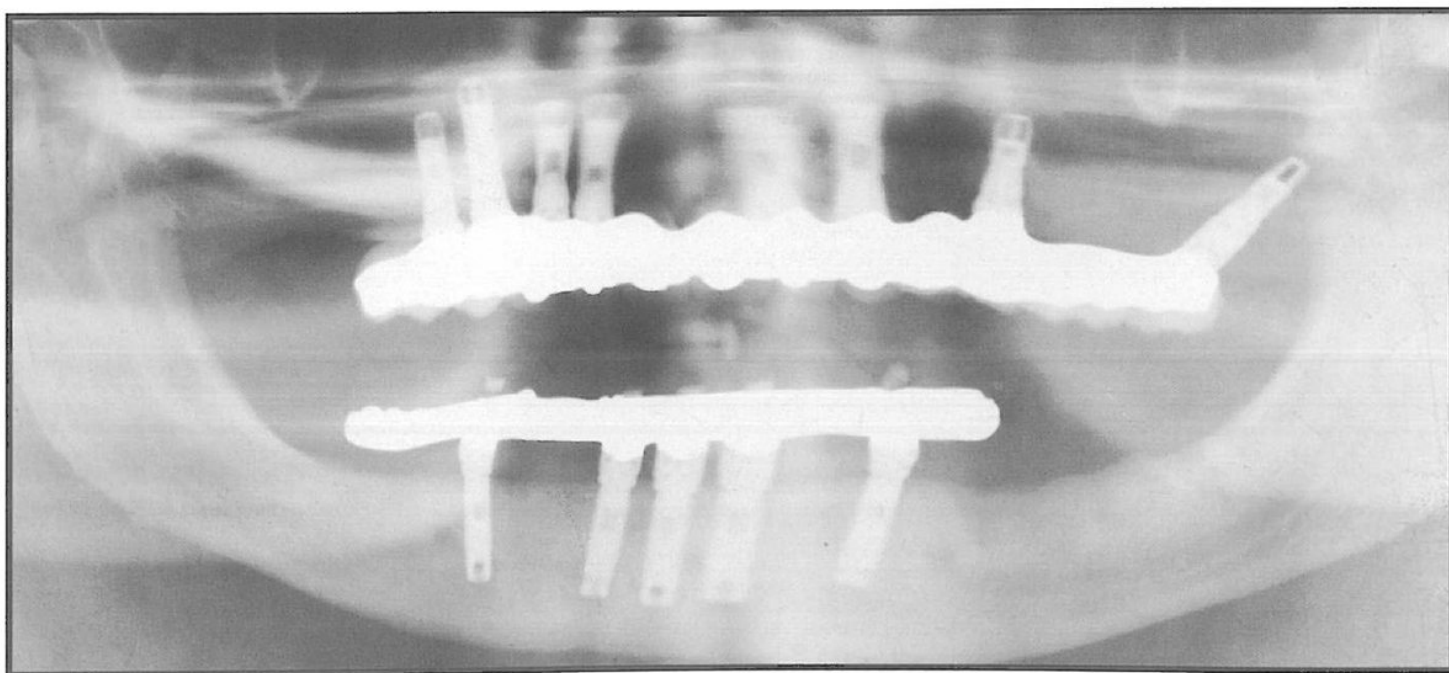
\* Associate Clinical Professor, Department of Fixed Partial Prosthodontics and Graduate Prosthodontics, Temple University, School of Dentistry, Philadelphia, Pennsylvania; Prosthodontics Intermedica, Institute for Facial Esthetics, 467 Pennsylvania Avenue, Fort Washington, Pennsylvania 19034.

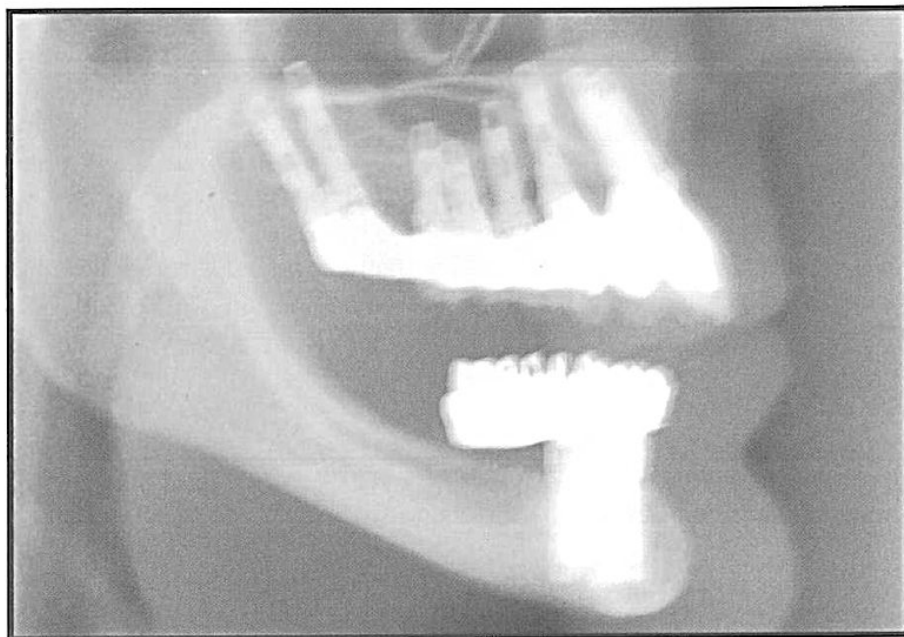




*Fig 1 Complete-arch fixed conversion prosthesis supported by maxillary posterior pterygomaxillary fixtures. This is an intermediate step in the gradual loading process, taking place before the initiation of mandibular reconstruction and before the occlusal scheme has been finalized.*

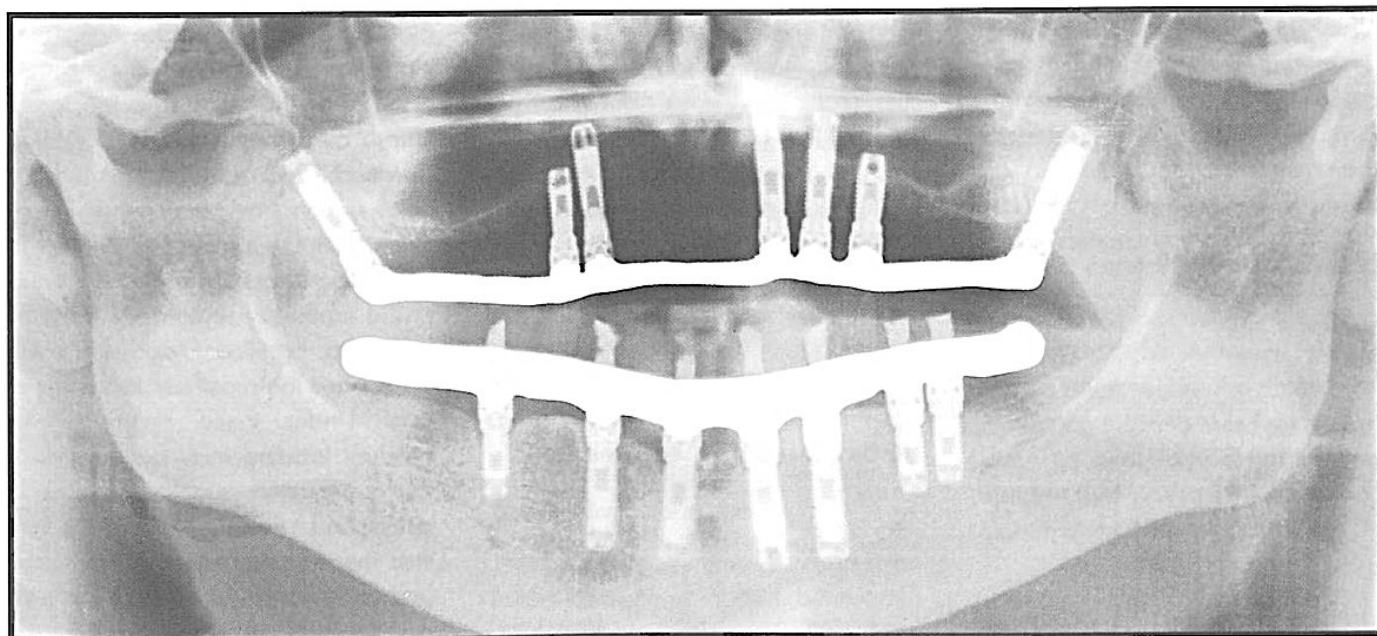
*Fig 2a Single pterygomaxillary fixture on the right side provides posterior support, eliminating the cantilever effect. Only a short (10-mm) cantilever extends posteriorly on the maxillary right side.*





*Fig 2b Lateral cephalometric view of the tuberosity fixture providing posterior support. Note the anterior cantilever required for appropriate lip support.*

*Fig 3 Fixed retention bars are used in combination with fixtures placed bilaterally in the tuberosity region to support a complete removable overdenture. This combination eliminates the cantilever effect.*





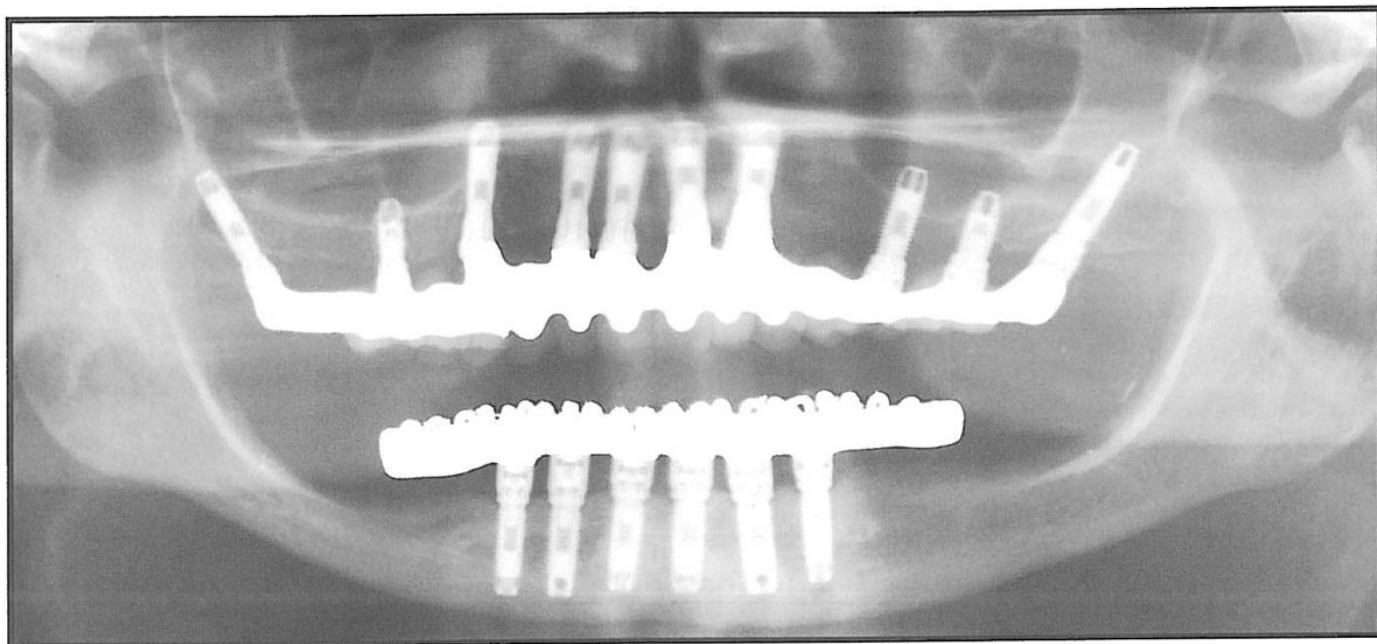


Fig 4 Bilateral tuberosity fixture support eliminates the maxillary posterior cantilever for this complete-mouth tissue-integrated rehabilitation.

#### Treatment planning considerations

When considering the use of an osseointegrated implant in the maxillary posterior dentition, the treatment team should examine several factors. The three important factors to consider for this procedure are (1) ergonomics, (2) biomechanics, and (3) anatomy.

#### Ergonomic considerations

The ergonomic factors include both surgical and prosthodontic access to the oral cavity when fixtures are intended for placement in the tuberosity or pterygomaxillary region. It is critically important to measure the amount of vertical opening the patient has available for fixture placement prior to surgery. The amount of space required for the drilling instrumentation and fixture mount as well as the length of the intended fixture to be placed must be considered.

#### Biomechanical considerations

Biomechanical considerations include analysis of the quality and quantity of the bone and the fixture length as it relates to the opposing dentition. Occlusal forces in the posterior region are greater than those exerted in the anterior region.<sup>2</sup> The inferior bone quality frequently found in the tuberosity region will be subjected to significant occlusal pressures once the prosthetic loading occurs. Under these circumstances, gradual loading may be required if the quality and quantity of bone is diminished.<sup>3</sup> For this reason, it is vital that the surgeon engage the pterygomaxillary cortical plate to achieve additional fixture stability.

### *Anatomic considerations*

Accurate radiographic analysis of available bone, using computerized tomography and panoramic radiographs, is helpful in determining the feasibility of fixture placement in the tuberosity or pterygoid region. The previously mentioned engagement of the pterygomaxillary plate is crucial, especially if minimal bone volume is available. Although placement of small fixtures in the maxillary posterior region have been attempted, the failure rate with 7-mm fixtures is significantly higher than that with longer fixtures. In a prospective, multicenter study of 159 partially edentulous patients between 18 and 70 years of age, the shortest fixtures (7 mm) used in the maxilla had an associated failure rate of 10.7% (3 of 28), while 10- and 13-mm fixtures had a failure rate of approximately 5.9% (8 of 135) in the same jaw. None of the maxillary fixtures that were 15 mm and longer failed (of a total of 54).<sup>4</sup> For this reason, a fixture no smaller than 10 mm should be placed in the tuberosity region.

### *Surgical aspects*

Restoration of the maxillary posterior dentition with endosseous implants relies on fixture stability and osseointegration. Tuberosity bone is often of poor quality, with low density and volume. In many instances, implants placed in the maxillary posterior area extend beyond tuberosity bone and gain stability by surgically engaging the dense cortical bone of the pterygoid plate. The denser cortical bone of the pterygoid plate has been successfully used as an implant receptor site.<sup>5</sup>

The surgical approach for placement of osseointegrated fixtures traditionally involves an incision in the buccal vestibule. This approach has been modified to a crestal incision extending carefully to the most posterior aspect of the maxillary bone. Buccal and palatal full flaps are used to expose the facial and palatal surfaces of the alveolar ridge as well as the posterior border of the maxilla. Careful dissection is required to avoid injury to the associated neurovascular structures that emanate from the osseous foramen and are abundant in the adjacent soft tissues.

This surgical approach has been described as difficult for the placement of endosseous implants intended for osseointegration. Worthington<sup>6</sup> recommends that this approach be used after the clinician has had extensive experience with fixture placement in other areas of the maxilla.

### *Fixture site preparation*

The graduated drill size site preparation as recommended by Brånemark (personal communication, June

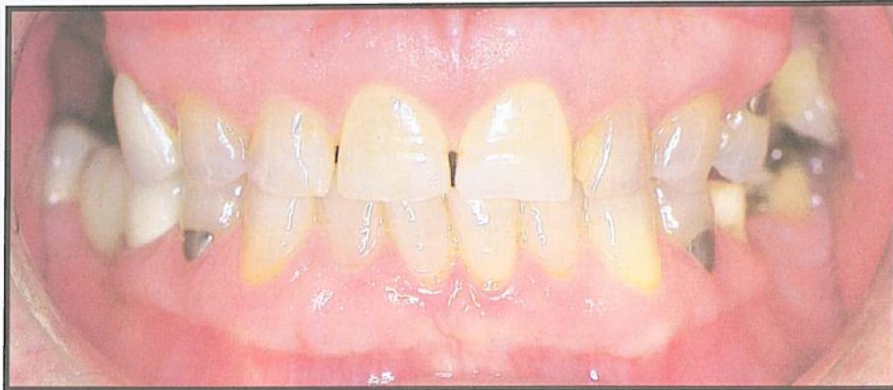1986) may be modified to eliminate the need for placement of a countersink bevel and the tapping threads. Cortical bone at the crest of the ridge in the maxillary posterior area is usually exceptionally thin or nonexistent. The trabecular density of the tuberosity bone is frequently sparse. In lieu of thread tapping as prescribed by the original Brånemark method, tuberosity and pterygoid maxillary fixture placement should be accomplished with the use of self-tapping fixtures.

Site preparation is completed with the 3.0-mm-diameter drill used under sterile saline irrigation. The titanium fixture is then placed with the mechanical drill set to 45 N/cm torquing force. If the pterygoid plate is engaged, the drill should be stopped so that the fixture can be hand-tightened and finally seated to the level of the ridge crest.

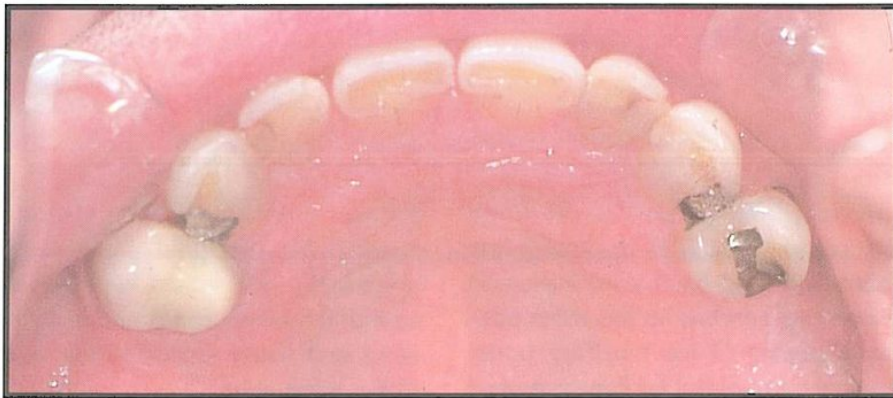
Following removal of the fixture mount, an antimicrobial ointment is placed in the screw hole of the fixture. The titanium cover screw is tightened in place and should be only 0.5 to 1.0 mm above the ridge crest. Sterile saline irrigation is used to cleanse the surgical site prior to flap closure, which is done with Vicryl suture material.

### *Prosthetic considerations*

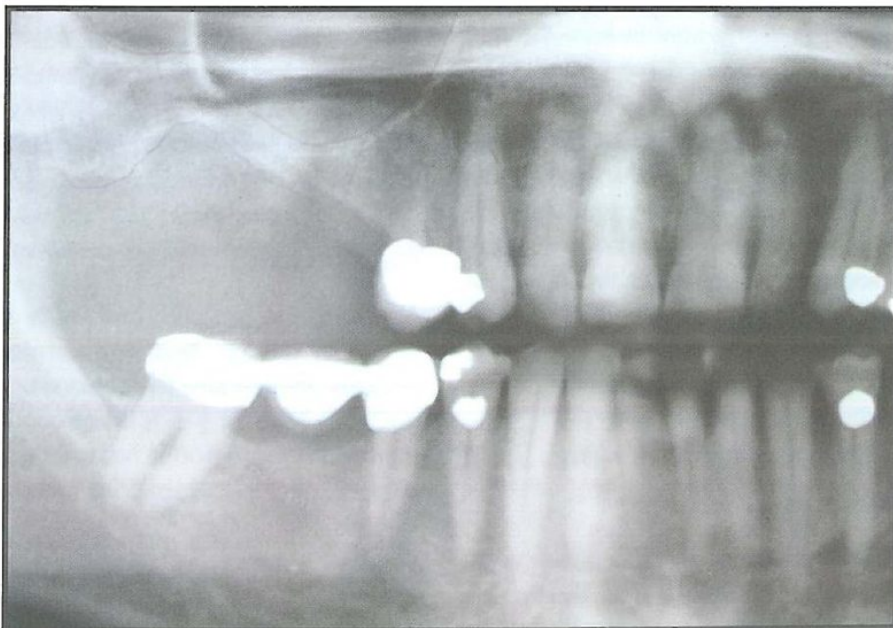Access to the posterior oral cavity is frequently difficult. Anatomic considerations often require the anterior angulation of the long-axis fixture alignment. This angulation is not only acceptable, but preferable, for prosthodontic component installation.



*Fig 5a Preoperative frontal clinical view.*



*Fig 5b Preoperative palatal view; maxillary right molars and second premolar are missing.*



*Fig 6 Preoperative radiograph of maxillary right posterior quadrant, showing prominence of the antrum.*

## Case report

A 59-year-old man presented in excellent health and demonstrated an aversion toward the use of a removable partial denture for the replacement of missing teeth. His chief complaint was the esthetic embarrassment of missing teeth in the maxillary right posterior quadrant (Figs 5a and b). Clinically, the patient presented with posterior debilitation including missing teeth in all posterior quadrants. A defective fixed partial denture continued to function in the mandibular right posterior area. All molars and the second premolar were missing from the maxillary right quadrant.

Radiographic examination confirmed the need for replacement of the mandibular right posterior fixed partial denture, as well as missing teeth in the remaining maxillary and mandibular posterior quadrants (Fig 6). The prominence of the maxillary antrum prohibited multiple fixture placement in the right second premolar and first molar regions. Adequate bone appeared to be available in the tuberosity region.

The treatment plan called for a fixed prosthesis to replace the first and second molars and the second premolar, using an osseointegrated titanium fixture placed in the tuberosity bone. The first premolar would serve as the anterior abutment. Connecting osseointegrated implants to the natural dentition has been described by Ericsson et al<sup>7</sup> in a study of ten patients; evaluation periods of 6 to 30 months postoperatively have revealed good clinical results. However, none of the fixtures was placed in the tuberosity region or beyond the maxillary first molar area.

### *Clinical procedures*

Following a diagnostic waxup, the patient used an all-acrylic resin provisional removable partial denture to replace the missing molars and second premolar, and this confirmed his distaste for the appliance. However, this provisional prosthesis did provide the necessary guidance for fabrication of a precision surgical guide stent to orient the long axis fixture angulation.<sup>8</sup> Fixture placement was followed by a 6-month healing period, after which stage-two surgery was successfully completed.

A combination conventional impression using cord retraction for the first premolar and a square impression cylinder over the fixture was used to produce the master cast (Fig 7). The laboratory prescription for the final retrievable tissue-integrated prosthesis included the design of a special telescopic coping with a distal cantilevered extension containing the occlusal portion of a titanium abutment screw (Nobelpharma) (Fig 8). This screw would act as the receptacle for stabilizing the anterior

portion of the tissue-integrated prosthesis overcasting. Complete finishing of the telescopic coping (Fig 9) was followed by fabrication of the gold alloy, porcelain-veneered overcasting (Fig 10).

Flat-headed screws (Figs 11a and b) were used to stabilize the overcasting tissue-integrated prosthesis to both the tuberosity-positioned titanium abutment cylinder and the palatal distal extension of the telescopic coping. Conventional pontic contours facing the residual ridge were established when the telescopic coping and overcasting were united (Figs 11c and d).

### *Prosthesis delivery*

The telescopic coping was fixed to the first premolar abutment tooth using zinc oxyphosphate cement (Fig 12). A silicone cement was used to seal the microscopic space between the telescopic coping and the overcasting<sup>9</sup> (Fig 13). Delivery of the porcelain-fused-to-gold, tissue-integrated prosthesis resulted in the extrusion of the silicone cement from the lingual cusp screw-access opening (Fig 14).

The buccofacial view of the final prosthesis (Fig 15) shows the posterior crossbite established in an effort to direct the occlusal forces more favorably along the long axis of the titanium osseointegrated fixture.



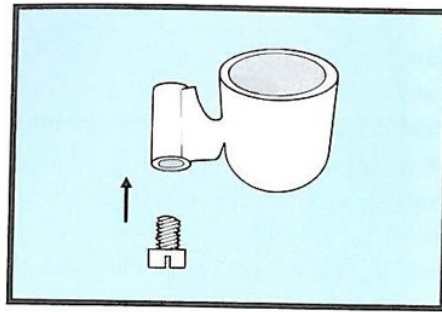
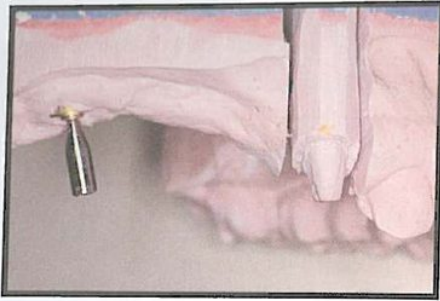


Fig 7 (left) A guide pin placed in brass abutment analog demonstrates the angulation required to take advantage of maximum available bone.

Fig 8 (right) Diagram of the telescopic coping for the first premolar. It incorporates a distal cantilevered paternal extension containing a titanium abutment screw.

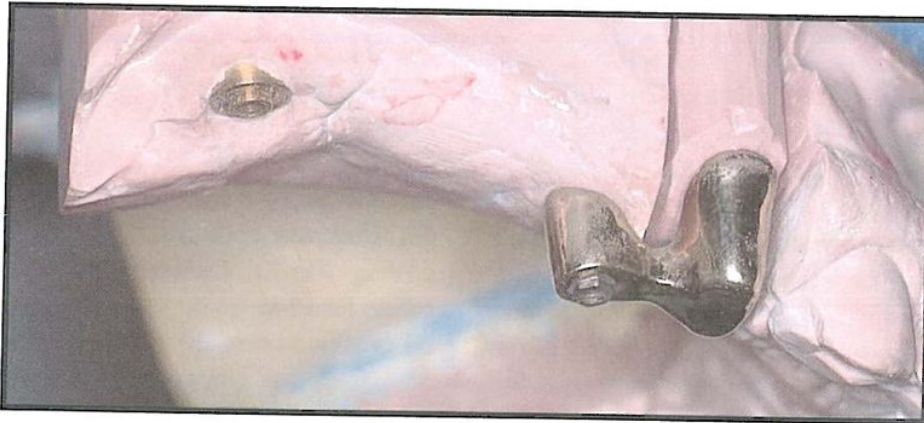


Fig 9 Completed gold telescopic coping and screw attachment seated in preparation for the fabrication of the tissue-integrated prosthesis.

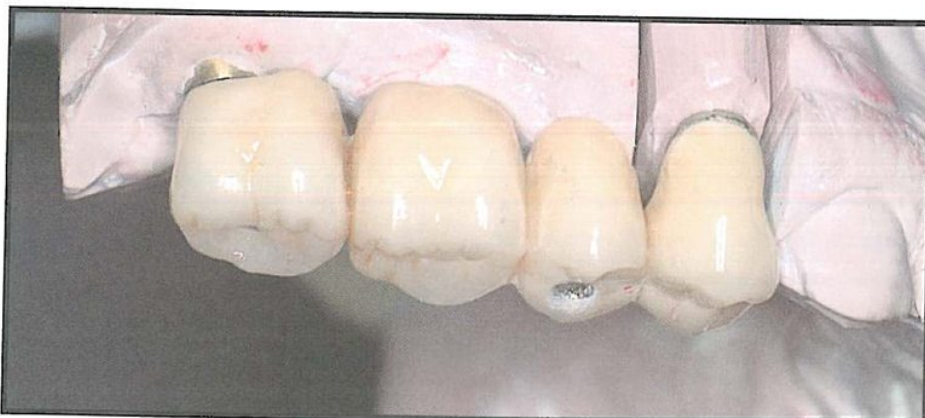
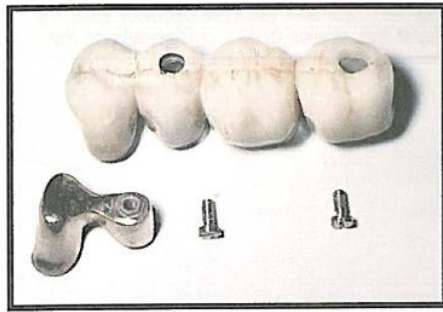
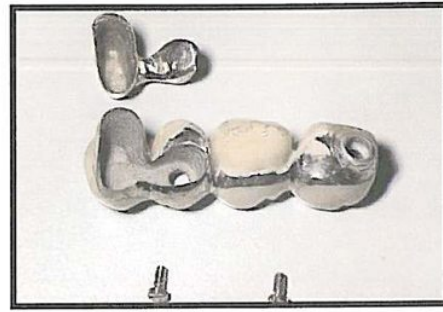


Fig 10 Porcelain-fused-to-gold tissue-integrated prosthesis replacing the posterior dentition.

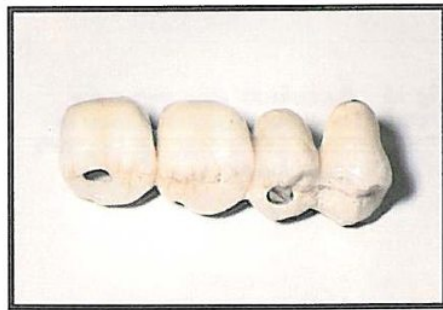


*Fig 11a Disassembled occlusal view shows telescopic coping with distal paternal extension, the porcelain-fused-to-gold overcasting, and the gold flat-headed fastening screws.*

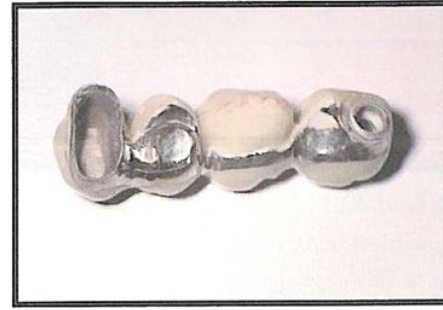

*Fig 11b Cervical view of disassembled components of the final tissue-integrated prosthesis.*

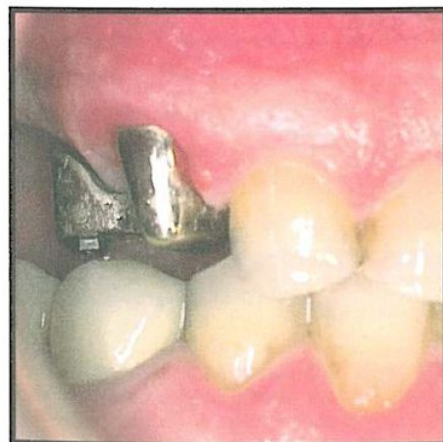
*Fig 11c Occlusal view of the assembled tissue-integrated prosthesis.*



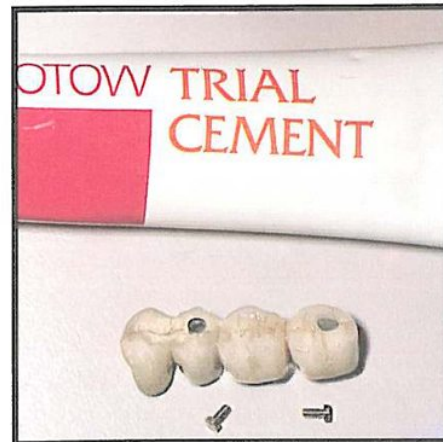
*Fig 11d Assembled components produce a pontic form conducive to proper oral hygiene.*



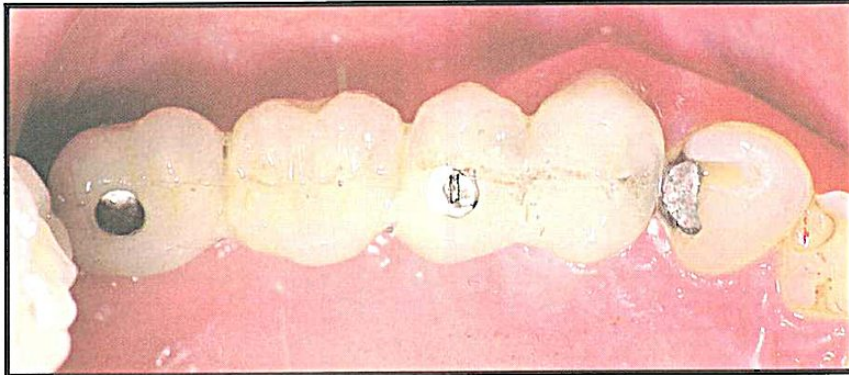
*Fig 12 Seated telescopic coping. Occlusal clearance for the gold screw accesses through the lingual cusp of the pontic.*



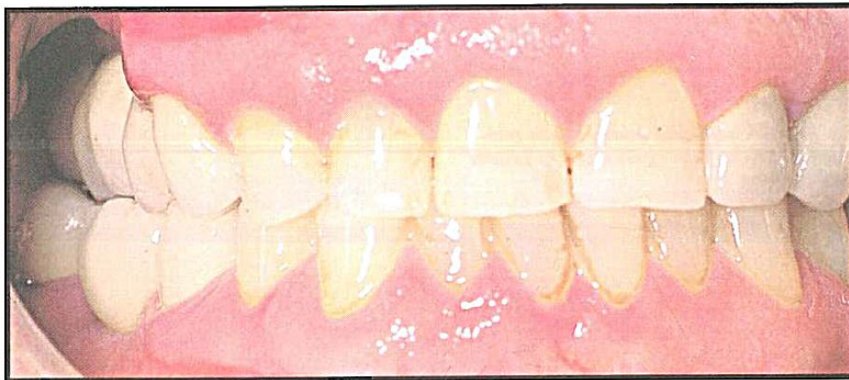
*Fig 13 Silicone cement to be used between the telescopic coping and the overcasting.*



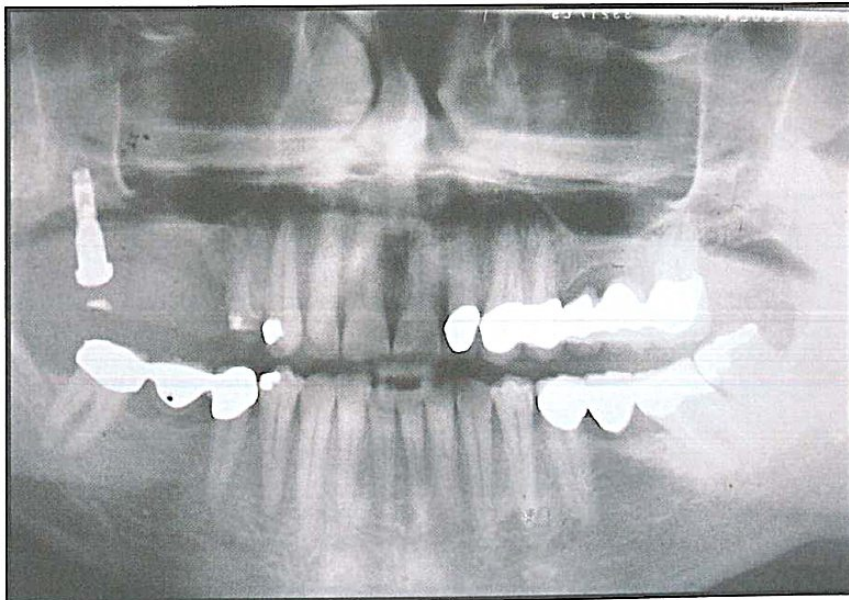




*Fig 14 Excess silicone cement extends from the screw hole on delivery of the tissue-integrated prosthesis.*



*Fig 15 Buccofacial view shows the crossbite occlusal relationship used to direct occlusal forces over the long axis of the titanium fixture.*



*Fig 16a Panoramic radiograph with provisional conversion prosthesis supported by recently uncovered osseointegrated tuberosity fixture.*

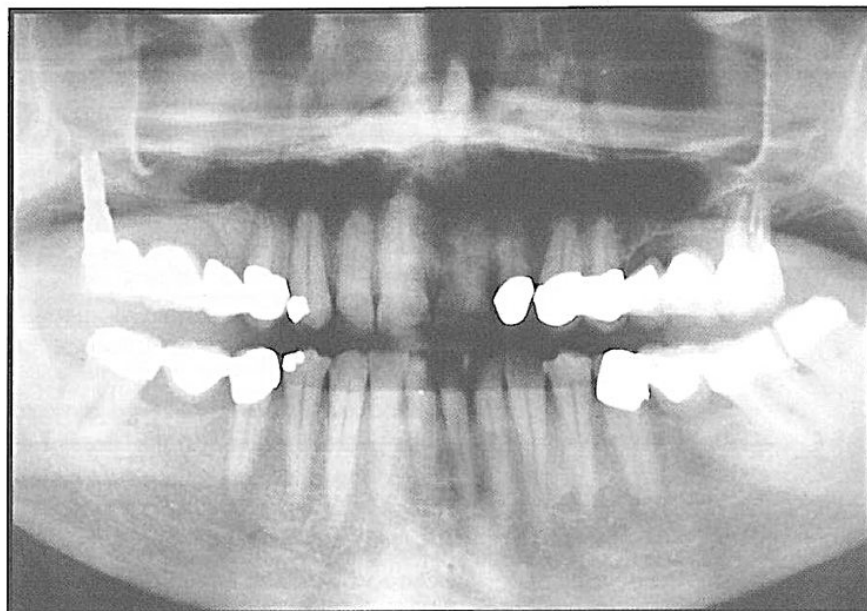

Fig 16b Postoperative panoramic radiograph of the final tissue-integrated prosthesis. The mandibular right fixed partial denture awaits replacement.

During the laboratory fabrication of the final prosthesis, the patient functioned comfortably with a conversion prosthesis<sup>10,11</sup> in which the teeth of the provisional removable partial denture were modified and affixed to the titanium abutment. Figure 16a shows the position of the conversion prosthesis supported by the first premolar abutment tooth and the tuberosity fixture. Accurate fit of the casting for the final tissue-integrated prosthesis was confirmed radiographically (Fig 16b).

## Discussion

### *Conceptual and anatomic considerations*

Use of a single posterior fixture to support a tissue-integrated prosthesis can be an acceptable method for fixed prosthodontic rehabilitation of the partially edentulous patient in whom the maxillary antrum prohibits the successful placement of multiple fixtures. The bone in the tuberosity region is frequently less dense than it is in other areas of the maxilla. Longer unloaded healing time should be considered for fixtures placed in tuberosity bone of low density. However, if adequate fixture length and

stability are obtained during the surgical installation, the likelihood for osseointegration is excellent. Skeletal anatomy often requires anterior angulation of tuberosity fixtures to secure the maximum length and stability from frequently engaging the posterior cortical plate of the maxilla.

Normal fixture support and soft tissue response has been noted in this patient as well as in 30 other patients currently functioning with a tissue-integrated prosthesis that is supported by tuberosity fixtures; the length of function ranges from 6 months to 3 years.



### *Laboratory design*

The laboratory design of the tuberosity fixture-supported final prosthesis should follow the parameters established for all tissue-integrated prostheses with regard to retrievability and facultative removal.

### *Functional and biomechanical considerations*

Occlusal forces should be directed for axial loading of the prosthesis and the abutments. Empirical observations and clinical studies<sup>12</sup> have indicated that, if an anterior tooth is used as a fixed partial denture abutment, the tooth must be periodontally sound with negligible mobility if rigidly connected to the pontics.<sup>13</sup> Even with a periodontally sound abutment tooth, the minimum movement of the prosthesis permitted by the periodontal ligament produces a bending moment for the prosthesis, osseointegrated fixture, abutment, and screws, as well as the surrounding bone. For this reason, an increased distance between the tuberosity fixture and the anterior abutment is desirable to help decrease the torquing forces applied to the screw joint components of the bone-anchored unit. Continued long-term clinical investigations as well as biomechanical analysis of bone flexibility are required to determine the efficacy of a tuberosity fixture-supported prosthesis.

### **Summary**

Fixed prosthodontic rehabilitation of a partially edentulous patient in an area where the maxillary antrum prohibited the successful placement of multiple fixtures has been described. A single posterior fixture was placed in the tuberosity region to support a tissue-integrated prosthesis directly connected to a periodontally sound anterior abutment tooth. Normal fixture support and soft tissue response were observed clinically.

Based on this clinical observation and the successful use of tuberosity/pterygomaxillary-osseointegrated fixtures, prospective scientific studies should be made to determine the predictability of this treatment method.

## References

1. Hure G: Scanner superimposed technique for the supero-ptyergoid implant positioning. Presented at the Advanced Osseointegration Course, Courchevel, France, February 1991.
2. Balshi T: T-Scan analysis of occlusal forces in patients with osseointegrated implants. Unpublished data.
3. Balshi T: Overload management of osseointegrated fixtures to achieve optimum bone remodelling through multistage prosthodontic loading. Presented at the 2nd International Congress on Tissue Integration in Oral, Orthopedic and Maxillofacial Reconstruction, Mayo Medical Center, Rochester, Minn, Sept 23-27, 1990.
4. van Steenberghe D, Bolender C, Henry P, et al: The applicability of osseointegrated oral implants in the rehabilitation of partial edentulism: a prospective multicenter study on 558 fixtures. *Int J Oral Maxillofac Implants* 1990; 5:272-280.
5. Tulasne J-F: Implant treatment of the missing posterior dentition, in Albrektsson T, Zarb G (eds): *The Brånemark Osseointegrated Implant*. Chicago, Quintessence Publ Co, 1989, chap 6.
6. Worthington P: Paper presented at the IX Annual Fall Conference on Dental Geriatrics, Milwaukee, Wis, Sept 6-7, 1990.
7. Ericsson I, Lekholm U, Brånemark P-I, et al: Restorations supported by the combination of teeth and osseointegrated titanium implants. *J Clin Periodontol* 1986;13:307-312.
8. Balshi T, Garver D: Surgical guide-stents for placement of implants. *J Oral Maxillofac Surg* 1987;45:463-465.
9. Henry P, Schibli L: Two-piece cast superstructure for mandibular osseointegrated bridgework. *Quintessence Dent Technol* 1987;11:321-327.
10. Balshi T: The Biotes conversion prosthesis: a provisional fixed prosthesis supported by osseointegrated titanium fixtures for restoration of the edentulous jaw. *Quintessence Int* 1985;16:667-677.
11. van Steenberghe D, Albrektsson T, Brånemark P-I, et al (eds): *Tissue Integration in Oral and Maxillofacial Reconstruction*. Amsterdam, Excerpta Medica, 1986.
12. Sullivan DY: A solution for the prosthetic problem of the hemidentate arch-tissue integrated prosthesis. *Int J Periodont Rest Dent* 1986;6(4):67-68.
13. Rangert B, Jemt T, Jorneus L: Forces and moments on Brånemark implants. *Int J Oral Maxillofac Implants* 1989;4:241-247.