

# Two-Implant-Supported Single Molar Replacement: Interdental Space Requirements and Comparison to Alternative Options



Thomas J. Balshi, DDS, FACP\*  
Glenn J. Wolfinger, DMD, FACP\*\*

*Posterior single-tooth implant restorations are subjected to an increased risk of bending overload. A high incidence of implant fracture has been reported when using a single standard 3.75-mm-diameter implant to support a molar restoration. The purpose of this article is to demonstrate the clinical feasibility of placing two implants to support a molar restoration and to compare this treatment option to the use of a single standard implant or a wide-diameter implant. Two osseointegrated dental implants used to support a molar restoration in interdental spaces as small as 10 mm is shown to be effective and predictable in 60 restorations over the past 7 years. The use of two implants provides more surface area for osseointegration and spreads the occlusal loading forces out over a wider area, reducing the potential bending forces that would otherwise exist in a single-implant molar restoration. (Int J Periodont Rest Dent 1997; 17:427-435.)*

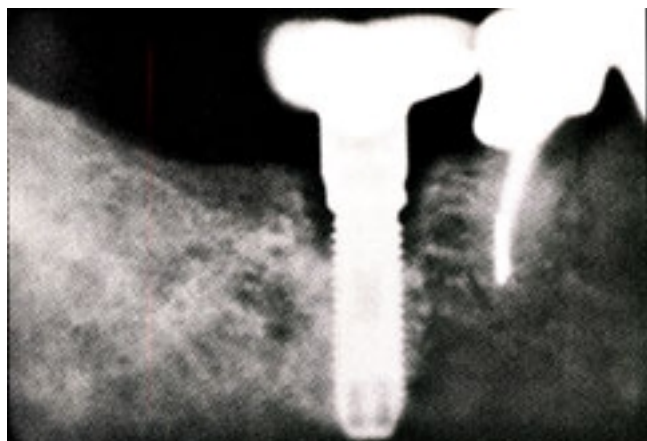
\* Diplomate, American Board of Prosthodontics; and Private Practice, Fort Washington, Pennsylvania.

\*\* Staff Prosthodontist, Veteran's Administration Medical Center, Philadelphia, Pennsylvania; and Private Practice, Fort Washington, Pennsylvania.

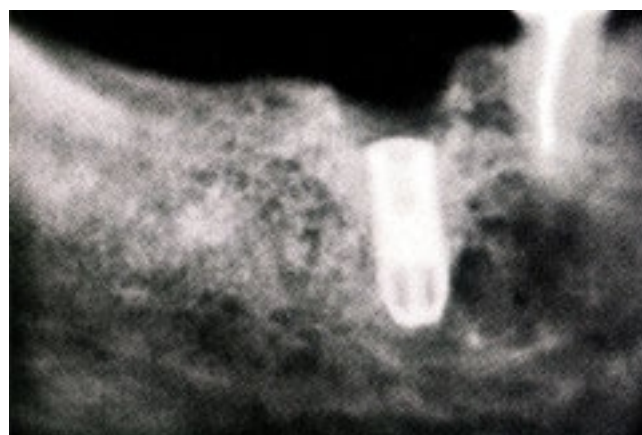In the past, options for replacement of a single missing tooth involved either a removable or a fixed partial denture. A fixed partial denture has been a well-accepted treatment modality.<sup>1</sup> However, because of the potential for marginal deterioration and periodontal disease, it may be contraindicated today to prepare healthy teeth proximal to an edentulous space for crowns,<sup>2</sup> and resin-bonded retainers have a high incidence (31%) of prosthesis debonding.<sup>3</sup>

The discovery of osseointegration and its introduction into dentistry<sup>4,5</sup> has enabled the predictable restoration of fully<sup>6</sup> and partially<sup>7</sup> edentulous patients with fixed prostheses. Single-tooth implant replacement is also an effective treatment modality.<sup>8,9</sup>

However, the predictability of implant osseointegration in the posterior is not as great as in the anterior<sup>10</sup> because of increased occlusal forces, limited bone quantity, and poor bone quality in that region.



*Fig 1a* Marginal bone loss occurring around a single 3.75-mm implant supporting a molar restoration at follow-up after several years.



*Fig 1b* Subsequent fractured implant resulting from bone loss that concentrated the occlusal forces at the weakest area of the implant. (Slides courtesy of Dr. Leonard Shulman, Waltham, MA)

Studies on bite force measurement indicate that there is considerably greater force generated in the posterior compared to the anterior part of the same jaw.<sup>11</sup> Occlusal forces can be three to four times as great in the molar region compared to the incisor region.<sup>12,13</sup> The quantity of available bone for implant placement in the posterior is limited by the lingual concavity and the inferior alveolar nerve in the mandible, and by the sinuses in the maxilla. There is also generally an inferior quality of bone in the posterior region compared to the anterior region of the same arch.<sup>14</sup> These conditions create a need to treatment plan posterior single-tooth replacement using osseointegrated dental implants differently.

Molar restorations on a single standard 3.75-mm-diameter

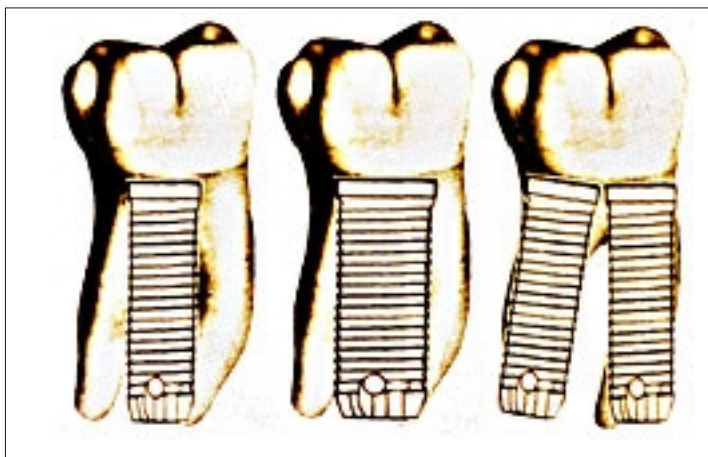
implant may present esthetic functional, and biomechanical problems. Although esthetics in the molar region are usually of minor concern, it is difficult to provide appropriate emergence profiles with a single implant. Functional complications include abutment screw loosening or fracture. Marginal bone loss and thread exposure are the principal biomechanical problems.

The most common problems reported with the early single-tooth implant restorations were loose screws. Jemt<sup>15</sup> reported a 26% incidence of screw loosening in the first year. The Brånemark System (Nobel Biocare) made improvements to their single-tooth abutment system, resulting in the CeraOne abutment system using a gold screw torqued to 32 Ncm to prevent loosening.<sup>16,17</sup> Although this appears to have solved the

problem for anterior single-implant restorations, the authors have still experienced screw loosening in some posterior CeraOne implant restorations. Becker and Becker<sup>18</sup> reported a 38% incidence of screw loosening over a 2-year period on single-implant molar restorations restored on single-tooth non-rotating abutments with gold cylinders. This occurred despite the exclusion of known bruxers and clenchers, careful occlusal adjustments, and reduction of occlusal tables.

Overload-induced bone resorption appeared to precede implant fracture in a significant number of single molar, single-implant restoration<sup>19</sup> (Figs 1a and 1b). Consequently, bone has been a weak link in these situations.<sup>20</sup> A correlation between overload and bone

*Fig 2 A single 3.75-mm standard implant to replace a missing molar does not restore the crown-to-root ratio; a wide-diameter implant offers an improvement; but two 3.75-mm standard implants most closely mimic the crown-to-root ratio that previously existed.*



resorption was demonstrated in a retrospective analysis of bone loss around implants<sup>21</sup> and in an experimental loading study in the long bones of dogs.<sup>22</sup> Marginal bone resorption increases the load on the remaining bone-to-implant interface by reducing the surface area for osseointegration and increasing the bending moment resulting from the increased lever arm.<sup>20,23</sup>

Sullivan<sup>24</sup> reported a 14% incidence of implant fracture on molar restorations supported by a single standard 3.75-mm implant, which he considers unacceptable. When using a commercially pure titanium implant, the most effective way of increasing implant strength is to increase its diameter. The 4-mm Brånemark implant is recommended for posterior restoration.<sup>20</sup> It has a fatigue

strength approximately 30% higher than the 3.75-mm Brånemark implant,<sup>25</sup> and establishes a more favorable screw joint and implant strength relationship. If overload occurs, screw loosening and screw fracture would be evident prior to the risk of implant fracture. The suggested method of restoring a single implant-supported molar is to control the occlusion by reducing the force level and centering its action relative to the implant axis.

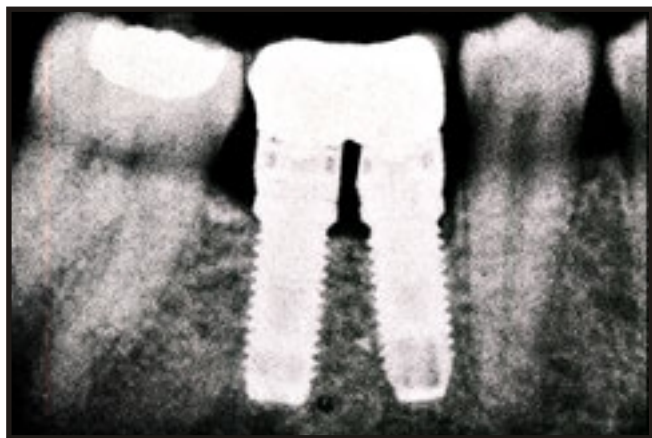However, a single implant for a molar does not replace the crown-to-root ratio that previously existed, and may subject the implant to overload. Dental implants are intended to replace the missing roots of the teeth. Therefore, a logical solution to implant overload is the use of two implants to replace the roots of a missing molar (Fig 2).<sup>26</sup> The purpose of this article is to

evaluate the clinical feasibility and advantages of using two implants to support a molar restoration.

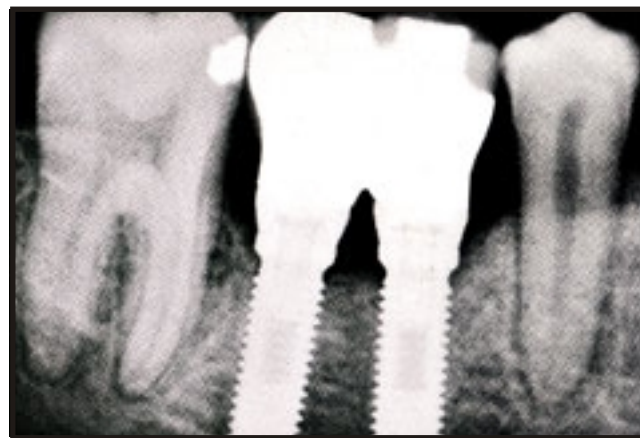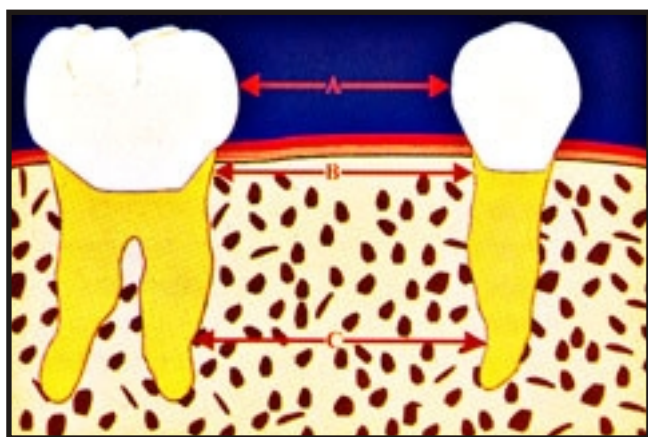
### Method and materials

A retrospective study evaluating the interdental space of 60 two-implant molar restorations restored over a 7-year period was conducted at Prosthodontics Intermedica, Fort Washington, Pennsylvania. The spaces were measured on periapical radiographs by a single investigator at three different levels. The ranges and means of these spaces were noted.

Twenty-five of the 60 sites presented with the tooth missing with no replacement. Nineteen of the 25 sites required orthodontics to restore the space



*Fig 3 Standard abutments required modification to provide space for restorative treatment and hygiene maintenance.*



*Fig 4 Estheticone abutments provided adequate space for esthetic restorative procedures and hygiene maintenance. Bone level has been maintained for over 2 years of functional loading.*

*Fig 5 Range and mean of interdental space measurements at three levels. A = Range of 10 to 17 mm and mean of 12 mm; B = range of 12 to 20 mm and mean of 15 mm; C = range of 12.5 to 24.5 mm and mean of 18 mm.*

necessary for ideal implant replacement.

Long shank burs and long fixtures mounts were used to surgically place the implants close to the proximal teeth. Using long shank burs in the posterior region requires a minimum of approximately 35 mm of inter-occlusal space for access. Implants were placed with their apical portions slightly divergent.

Standard abutments were routinely used at stage-two surgery in the early cases. Abutments

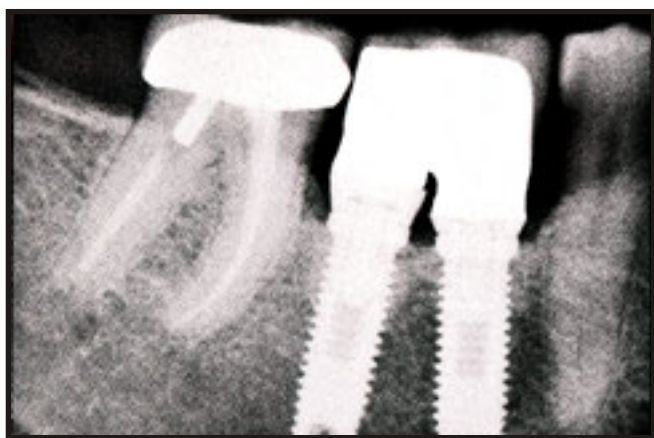were modified on one occasion to avoid contact when the implants were too convergent (Fig 3). UCLA abutments (Implant Innovations) were used when vertical space was limited. Estheticone abutments (Nobel Biocare) were used when they became available to provide increased inter-abutment space for easier hygiene access and an improved esthetic result (Fig 4). Screw-retained impression copings were modified for the impression procedure and the fabrication of a conversion prosthesis, a fixed provisional

acrylic restoration.<sup>27,28</sup> The conversion prosthesis enabled immediate implant loading following stage-two surgery.

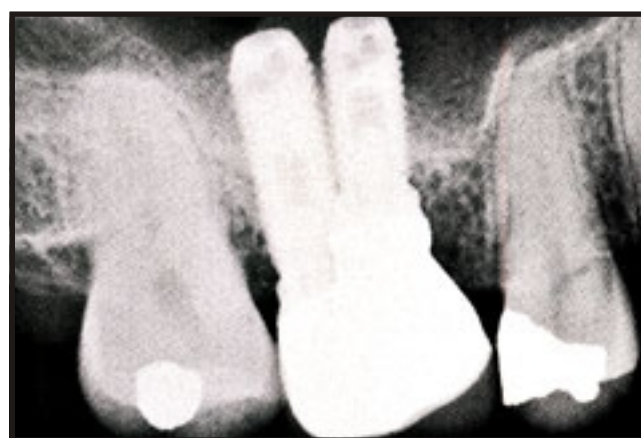## Results

Sixty sites had teeth located mesial and distal to the site, enabling periapical radiographic analysis of the interdental space at three levels: (A) between the proximal contact points; (B) at the crestal bone; and (C) at the mid-root length (Fig 5).





**Fig 6** Periapical radiograph of a 4-year follow-up on a mandibular two-implant-supported molar with interdental space measurements of 10 mm between proximal contacts and 12 mm at the level of the crest of the bone.



**Fig 7** Two-implant-supported maxillary molars can be restored with minimal interdental space when implants are placed in buccal and palatal positions.

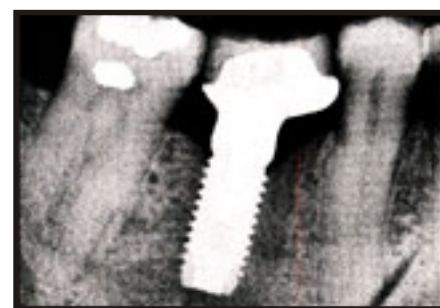While wide-diameter implants may have advantages over single standard-diameter implants, the use of two implants to replace a single molar provides more surface area for osseointegration (Table 1) and distributes the occlusal forces over a larger area within the bone compared to one wide-diameter implant of the same strength.

## Discussion

According to Becker and Becker,<sup>18</sup> "Ideally, two implants should be used to replace a single molar; however, a molar edentulous space is often bound by natural teeth, which results in insufficient mesiodistal bone width for placement of more than one (3.75-mm-wide) implant." According to Saadoun et al,<sup>29</sup> a

minimum interdental space of 12.5 to 14 mm is necessary to successfully place and restore two 3.25-mm-diameter implants for a missing molar. The present study indicates that two standard-diameter implants (3.75 mm) can successfully be placed in sites with as little as 10 mm of interproximal space. The more important measurement, however, is at the level of the crestal bone, where two implants were placed in as little as 12.0 mm of interdental space (Figs 6 and 7).

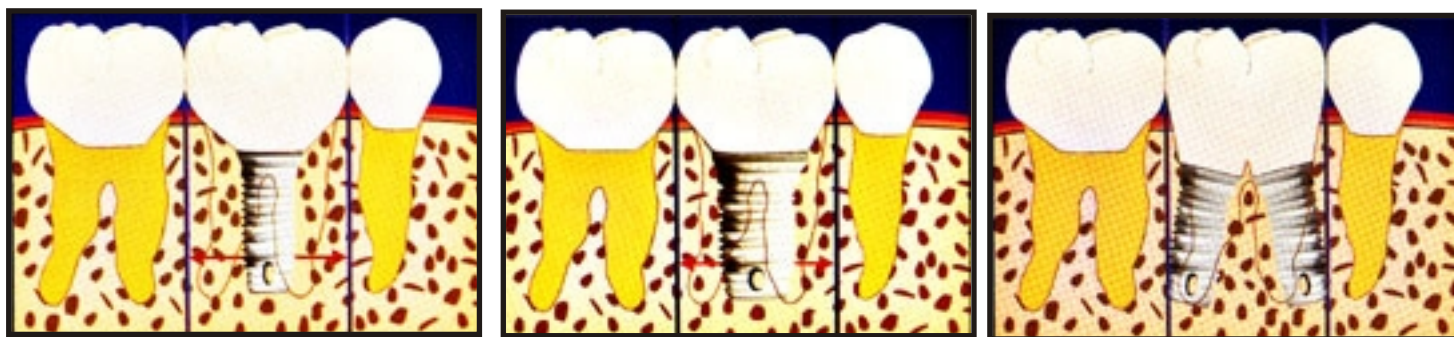
Because a molar is not equally wide and long, it is impossible to provide optimal root-form support with one cylindrical implant (Fig 8). However, two implants replace the missing tooth roots more naturally in position and direction. This should help to preserve and maintain crestal



**Fig 8** Wide-diameter implants used for single-tooth molar replacement leave cantilevered portions that may be susceptible to biomechanical problems.

**Table 1** Comparative surface areas of screw-type implants with different diameters

Implant size (diameter)	Surface area
3.75 mm	Baseline
4.0 mm	+8%
5.0 mm	+35%
6.0 mm	+61%
3.75 mm x 2	+100%



**Figs 9a to 9c** Support gained by the three different implant-supported molar restoration design. (left) The largest cantilevering effect is on the single 3.75-mm implant. (center) Wide-diameter implant reduces the cantilevering effect. (right) Two standard implants reduce, if not eliminate, the cantilevering effect.

bone. It should also provide better support against bucco-lingual and mesiodistal bending. In addition, the use of two implants reduces the loosening by decreasing the rotating forces around the implant axis. Two implants also eliminate the inherent mesiodistal cantilever and reduce the potential for overload (Figs 9a to 9c).

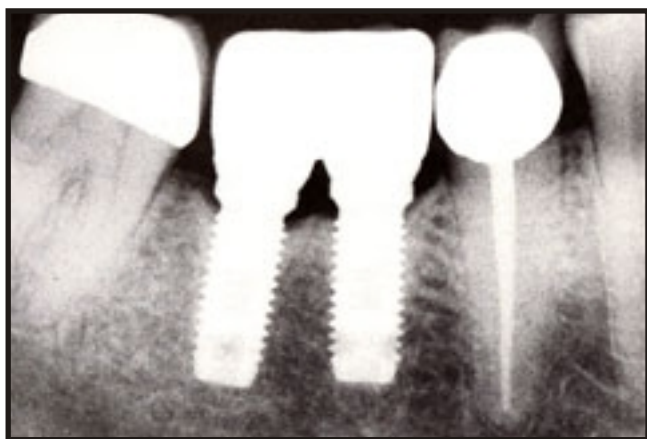
In a comparative study it was shown that molar restorations supported by two implants exhibit fewer complications than those supported by one implant.<sup>30</sup> Prosthesis mobility and screw loosening were the most frequent complications associated with one-implant molar restorations. In another study, a 38% incidence of screw loosening on single-implant molar restorations over a 2-year period was reported, despite the fact that bruxers and clenchers were excluded, and reduced occlusal tables were fabricated.<sup>18</sup>

This high incidence of screw loosening may be a warning sign of a potentially more serious complication, implant fixture fracture, that may arise over time with these restorations, as noted by Rangert et al.<sup>19</sup> The present study involves 60 restorations followed for 7 years in which bruxers and clenchers were not excluded from treatment, and normal size occlusal tables were fabricated.

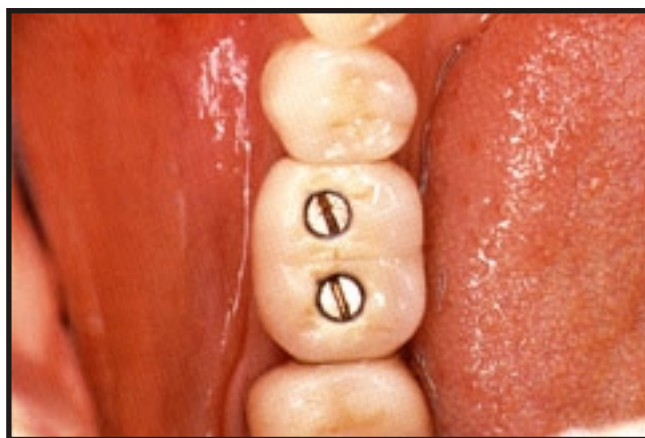
Most patients were capable of performing adequate oral hygiene and have little or no soft or hard tissue problems as a result of the proximity of the two implants. Patients have been able to successfully clean between the two implants using a variety of oral hygiene methods: superfloss, floss threaders, proxy brushes, and water piks, along with normal toothbrush procedures (Fig 10a to 10d). In addition, the two-implant screw-

retained molar restoration maintains prosthesis retrievability. Orthodontic repositioning can be considered in areas with insufficient interdental space, whereas enameloplasty can be performed to alleviate minor space difficulties between the crowns and simultaneously create broader interproximal contact areas to resist rotation.

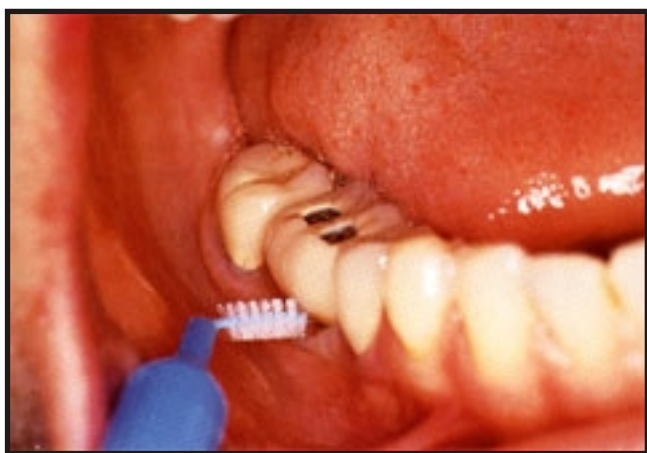Wide-diameter implants for molar replacement still leave cantilevered portions of the restoration that are potential biomechanical problems. Some wide-diameter implants (Implant Innovations) also have an enlarged implant shoulder area, providing more primary surface area for abutment-to-implant interface, increasing prosthesis stability, and enabling a wider emergence profile.<sup>31</sup>



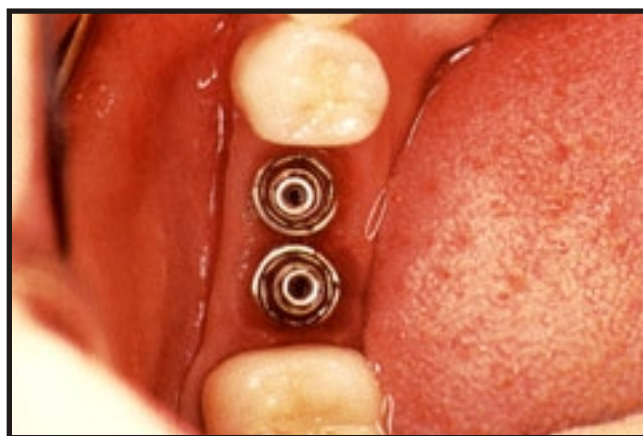
**Fig 10a** *Periapical radiograph of a two-implant-supported molar that has been in function for over 2 years.*



**Fig 10b** *Clinical view of two-implant-supported molar restoration. Notice broad interproximal contacts that were designed to resist rotation.*



**Fig 10c** *Hygiene between the two implants can be accomplished with proxy brush or other hygiene aids.*



**Fig 10d** *Clinical view of soft tissue response beneath a two-implant-supported molar after over 2 years of function.*

Wide-diameter implants may be indicated in molar areas where inadequate space does not permit the placement of two implants, and where excessive occlusal forces exist. The disadvantage of starting with the wide diameter implant is that if the implant fails to osseointegrate, a

"backup/rescue implant" or wider implant for immediate replacement is not available. Also, many ridges will not accommodate a wide-diameter implant in the buccolingual dimension without augmentation. Ideally, a minimum of 1 to 2 mm of bone should remain around the

implant for osseointegration to occur. Thus, a buccolingual ridge width of 7 to 10 mm must exist for the placement of a 5 to 6 mm wide implant.



## References

## Conclusion

Single 3.75-mm-diameter implants are incapable of predictably withstanding molar masticatory function and occlusal loading forces. Wide-diameter implants are a suitable alternative for replacing a missing molar in some cases; however, the use of two implants has been successfully demonstrated to be a more functional and biomechanically sound method of molar replacement. The difference in cost between placing one or two implants is minimal, and the advantages outweigh the disadvantages. The results of this study indicate that the placement of two implants is possible in sites with as little as 10 mm of interproximal space. Further study on a greater number of implants loaded over 5 years, evaluating bone response, is necessary to further validate the success of this treatment option.

## Acknowledgements

The authors wish to thank Dr. Bo Rangert for his technical assistance, Chris Raines for computer graphics, and Liz Kirk for manuscript preparation.

1. Rueger K. Investigation on Long-term Prognosis of Fixed Prosthodontics (Doctoral thesis). Zurich: Zurich University, 1979.
2. Balshi TJ. Candidates and requirements for single-tooth implant prostheses. *Int J Periodont Rest Dent* 1994;14:317-331.
3. Williams VD, Thayer KE, Dehehy GE, Boyer DB. Cast metal, resin-bonded prostheses: A 10-year retrospective study. *J Prosthet Dent* 1989;61: 436-441.
4. Brånemark P-I, Breine U, Adell R, Hansson B, Lindstrom J, Ohlsson A. Intraosseous anchorage of dental prostheses: Experimental studies. *Scand J Plast Reconstr Surg* 1969;3:81-100.
5. Brånemark P-I, Introduction to osseointegration. In: Brånemark P-I, Zarb GA, Albrektsson T. *Tissue-Integrated Prostheses: Osseointegration in Clinical Dentistry*. Chicago; Quintessence, 1985:11-76.
6. Adell R, Lekholm U, Rockler B, Brånemark P-I. A 15-year study of osseointegrated implants in the treatment of edentulous jaw. *Int J Oral Surg* 1981;10:387-416.
7. Jemt T, Lekholm U, Adell R. Osseointegrated implants in the treatment of partially edentulous patients. A preliminary study of 876 consecutively installed fixtures. *Int J Oral Maxillofac Implants* 1989;4:211-217.
8. Schmitt A, Zarb GA. The longitudinal clinical effectiveness of osseointegrated dental implants for single-tooth replacement. *Int J Prosthodont* 1993;6:197-202.
9. Laney WR, Jemt T, Harris D, Henry PJ, Krogh PH, Polizzi G, et al. Osseointegrated implants for single-tooth replacement: Progress report from a multicenter prospective study after 3 years. *Int J Oral Maxillofac Implants* 1994;9:49-54.



10. Da Silva JD, Schnitman PA, Wohrle PS, Wang HN, Koch GG. Influence of site on implant survival: 6 year result. *J Dent Res* 1992;71:256.
11. Haraldson T, Carlsson GE, Ingervall B. Functional state, bite force and postural activity in patients with osseointegrated oral implant bridges. *Acta Odontol Scand* 1979;37:195.
12. Craig RG. *Restorative Dental Materials*, ed 7. St Louis, MO: Mosby, 1985:60.
13. Knoblauch KR. In-vivo Occlusal Force Determination (Master's thesis). Philadelphia, PA: Drexel University, 1971:72.
14. Orenstein IH, Synan WJ, Truhlar RS, Morris HF, Ochi S. Dental Implant Clinical Research Group. Bone quality in patients receiving endosseous dental implants: DICRG Interim Report No. 1. *Implant Dent* 1994;3(2):90-94.
15. Jemt T. Modified single and short span restorations supported by osseointegrated fixtures in the partially edentulous jaw. *J Prosthet Dent* 1986;55:243-247.
16. Jörn  us L, Jemt T, Carlsson L. Loads and designs of screw joints for single crowns supported by osseointegrated implants. *Int J Oral Maxillofac Implants* 1992;7:353-359.
17. Andersson B, Odman P, Carlsson L, Br  nemark P-I. A new Br  nemark single tooth abutment: Handling and early clinical experiences. *Int J Oral Maxillofac Implants* 1992;7:105-111.
18. Becker W, Becker BE. Replacement of maxillary and mandibular molars with single endosseous implant restorations: A retrospective study. *J Prosthet Dent* 1995;74:51-55.
19. Rangert B, Krogh PH, Langer B, Van Roekel N. Bending overload and fixture fracture: A retrospective clinical analysis. *Int J Oral Maxillofac Implants* 1995;10:326-334.
20. Rangert B. Biomechanics of the Br  nemark System. *Aust Prosthodont J* 1995;9(suppl):39-48.
21. Quirynen M, Naert I, van Steenberghe D. Fixture design and overload influence marginal bone loss and fixture success in the Br  nemark System. *Clin Oral Implants Res* 1992;3:104-111.
22. Hoshaw SJ, Brunski JB, Cochran GV. Mechanical loading of Br  nemark implants affects interfacial bone modeling and remodeling. *Int J Oral Maxillofac Implants*, 1994;9:345-359.
23. J  rn  us L. Avoiding overload in single-tooth restorations. *Nobelpharma News* 1992;6:3.
24. Sullivan D. Wide implants for wide teeth. *Dent Econ* 1994;84:82-83.
25. Rangert B, Formalm G. Strength characteristics of CP titanium. *Nobelpharma News* 1994;8:7.
26. Balshi TJ. First molar replacement with an osseointegrated implant. *Quintessence Int* 1990;21:61-65.
27. Balshi TJ. The conversion prosthesis: A provisional fixed prosthesis supported by osseointegrated titanium fixtures. In: van Steenberghe D (ed). *Tissue Integration in Oral and Maxillofacial Reconstruction* (Proceedings of an International Congress, May 1985, Brussels). The Netherlands: Excerpta Medica, 1986:354-356.
28. Balshi T. The Biotes conversion prosthesis: A provisional fixed prosthesis supported by osseointegrated titanium fixtures for restoration of the edentulous jaw. *Quintessence Int* 1985;16:667-677.
29. Saadoun AP, Sullivan DY, Kirschek M, LeGall M. Single-tooth implant management for success. *Pract Periodontics Aesthet Dent* 1994;16:73-82.
30. Balshi TJ, Hernandez RE, Pryszlak MC, Rangert B. A comparable study between one implant vs two implants replacing a single molar. *Int J Oral Maxillofac Implants* 1996;11:372-378.
31. Sullivan DY, Siddiqui A. Wide-diameter implants: Overcoming problems. *Dent Today* 1994; 13:50-57.