

***Oral and
Maxillofacial Surgery
Clinics of North America***

IMPLANTS

**Philip Worthington, MD, BSc, FDSRCS
O. Ross Beirne, DMD, PhD
Guest Editors**

NOVEMBER 1991

Advantages and Disadvantages of Linking Implants to the Natural Dentition

Thomas J. Balshi, DDS*

Restoration of the partially edentulous patient has been managed by traditional prosthodontic methods including fixed prosthodontic treatment, when sufficient abutment teeth are available; conventional and precision-attachment removable partial dentures; and distal-extension removable partial dentures, when posterior abutments are inadequate. In limited circumstances, tooth-supported long and short cantilevered restorations have functioned successfully. However, some patients have either too few teeth in a poor distribution or insufficient periodontal support to provide abutment teeth for traditional fixed prostheses. A removable prosthesis may not be desired by the patient or biomechanically indicated. In these situations, osseointegration should be considered. Furthermore, with the increased predictability of osseointegrated implants, the restoration of the partially edentulous patient with segmental tissue-integrated prostheses may be biologically more conservative than the traditional preparation of multiple abutment teeth.

The concept of osseointegration, as developed by P-I Brånemark, has permitted restoration of the fully edentulous patient since 1965. With more than 25 years of successful function, the bone-anchored prosthesis has taken a prominent position in prosthodontic treatment planning and oral rehabilitation.

The criteria for implants have changed over the past two decades. In 1986, Albrektsson et

al¹ set forth minimal success guidelines more rigid than previous criteria.²³ The highly predictable success experienced with osseointegrated implants is critically dependent on meticulous execution of specific surgical and prosthodontic treatment protocols.

IMPLANT ATTACHMENT TO BONE

One essential element in the long-term success of an implant-supported prosthesis for the partially edentulous patient is the development and maintenance of implant attachment to the host bone. Four general categories of mechanisms are identified, as discussed in detail earlier in this issue: (1) a highly differentiated fibrous attachment; (2) a less-differentiated fibrous attachment; (3) the use of artificial fixatives such as bone cement, typically methylmethacrylate, as in orthopedic procedures; and (4) direct implant-to-bone contact, known as osseointegration, which is generally defined as the direct contact between ordered living bone and the surface of a load-carrying implant. It is the author's opinion that only osseointegration can be considered acceptable for long-term biomechanical implant success.

The success of osseointegration depends heavily on the skill of the surgeon and the prosthodontist in providing gentle surgical manipulation of bone and soft tissue, on precise

*Director, Institute for Facial Esthetics, and Private Practice, Prosthodontics Intermedica, Fort Washington, Pennsylvania

fabrication of the prosthesis, and on the manufacturer's preparation of the implant surface and geometry. Following these standards and with successful osseointegration of titanium fixtures, restoration of the partially edentulous patient has been reported. The results of a retrospective study, summarized by van Steenberghe,²⁷ of the prosthodontic treatment of 38 partially edentulous patients by six centers on three continents show success rates for the individual fixtures in the upper and lower jaws of 87% and 92%, respectively. Approximately 58% of these implants were connected to the natural dentition.

Ericsson et al¹⁴ reported on 10 patients, ages 31 to 60, with a combination of osseointegrated fixtures and natural teeth serving as abutments. Six bridges were originally connected to tooth abutments (type A), and four were connected to an interlocking precision attachment installed in the contact area between the tooth and the fixture-supported area. Stress broken attachments were used for patients with increased mobility of their dentition. Analysis of the treatment outcome was made through clinical and radiographic measurements.

Balshi,⁵ in a paper delivered to the fourth Annual Scientific Session of the Academy of Osseointegration, described a study of 214 fixtures used to support 60 bridges in partially edentulous patients. In most cases, either two or three fixtures were used to support the prosthesis. The duration of prosthesis use ranged from 6 months to 4 years. All bridges were fabricated of porcelain fused to gold, and 16% were connected to natural teeth. All prostheses in this study were completely retrievable. Those connected to natural teeth were joined by either telescopic copings (11 cases) or interlocking precision attachments (2 cases). A multitude of parameters were studied, including marginal bone loss measured radiographically. Only 8 of the 209 surviving fixtures demonstrated bone loss, predominantly between 0.5 and 1.0 mm, with the exception of one fixture with a 5-mm bone loss that was accounted for by extraction surgery immediately adjacent to the implants.

The discussion of implants to restore partially edentulous patients must include consideration of bone quality and quantity because of the significant differences between the maxilla and the mandible. Hobo et al¹⁶ state that "a maxillary prosthesis may require attachment using a

non-rigid connector to a natural tooth . . . to include cantilever extension." The concept of time, functional loading, and bone remodeling around osseointegrated implants was presented at the second International Congress on Tissue Integration in Oral, Orthopedic and Maxillofacial Implants. This paper described the gradual loading time versus prosthetic design criteria for optimal bone remodeling around implants that may be subjected to excessive loads in patients suffering from parafunctional habits.⁷

CONNECTING OSSEOINTEGRATED IMPLANT FIXTURES TO NATURAL TEETH

There are two possible methods of connecting an osseointegrated implant to a natural tooth: rigid and nonrigid. The rigid connection of a single osseointegrated implant to a natural tooth, when loaded, produces a differential be-

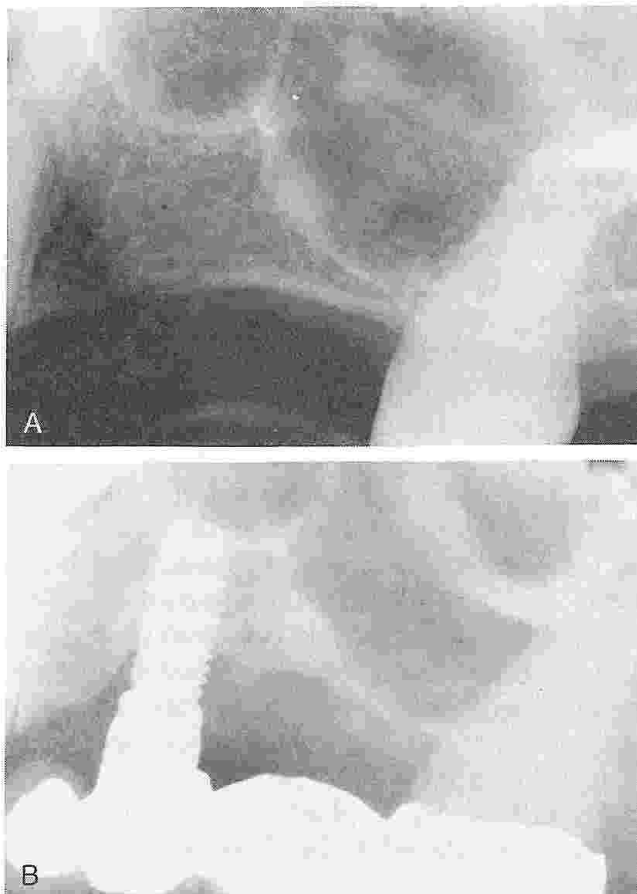


Figure 1. A, Loss of bone around implant site. Preoperative radiograph of site. B, Rigid connection between osseointegrated implant and second molar. Note angular bone loss mesial and distal to the implant.

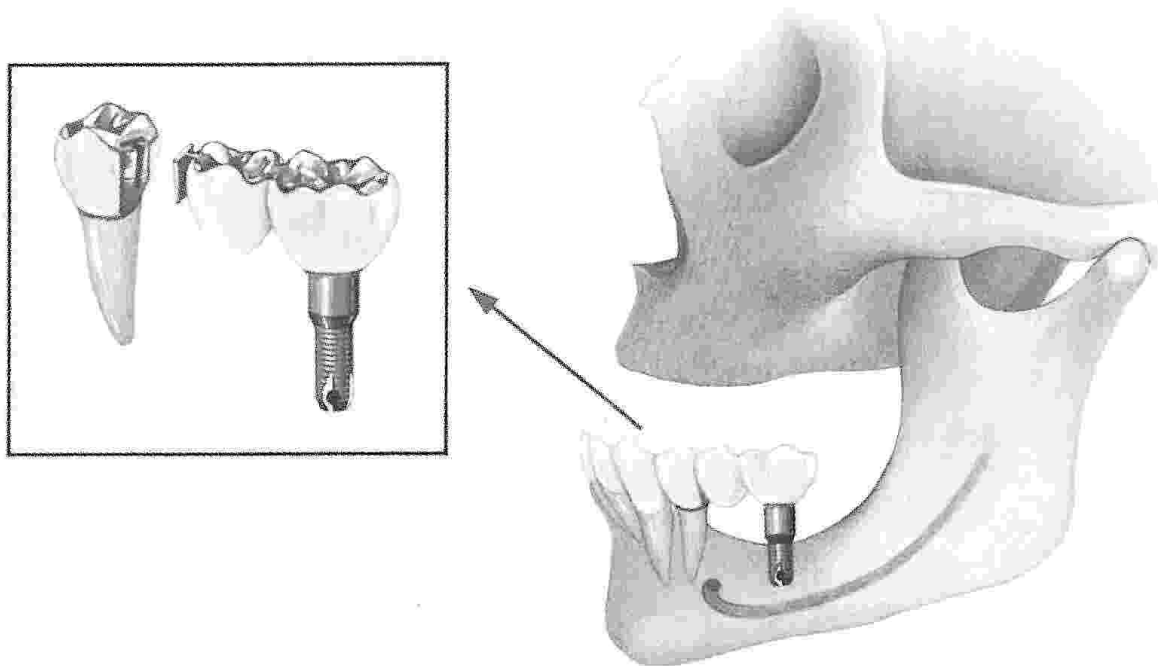


Figure 2. Fixed partial denture supported by a natural tooth as the anterior abutment and an implant as the posterior abutment. The two sections are joined using a nonrigid connector distal to the natural tooth. This type of attachment allows the natural tooth physiologic mobility. (From Hobo S, Ichida E, Garcia LT: *Osseointegration and Occlusal Rehabilitation*. Tokyo, Quintessence, 1989, p 80; with permission.)

tween the viscoelastic deflection of the tooth via the periodontal ligament and an almost negligible elastic deformation of the osseointegrated fixture.^{11, 19} In some of these cases, angular bone loss around the implants has been noted (Fig. 1).

Because the long-term effects of rigid connection are not yet known,⁶ the use of a nonrigid connection has been advocated¹² (Fig. 2) and used clinically^{13, 24, 25} with success, as illustrated by Langer and Sullivan²⁰ (Figs. 3 and 4). Using finite element analysis, van Rosson et al²⁶ con-

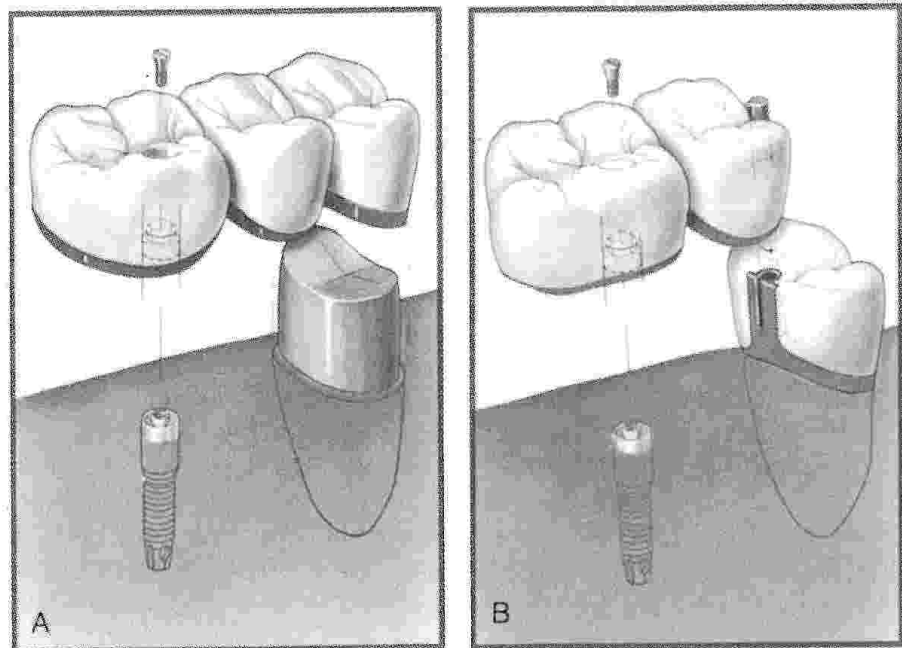


Figure 3. Types of nonrigid connections. *A*, Using a telescopic coping on the natural tooth. *B*, Using a male-female interlock between the implant and the crowned abutment tooth. (From Langer B, Sullivan D: *Osseointegration: Its impact on the relationship of periodontics and restorative dentistry*. *Int J Periodont Restor Dentist* 9:165-184, 1989; with permission.)

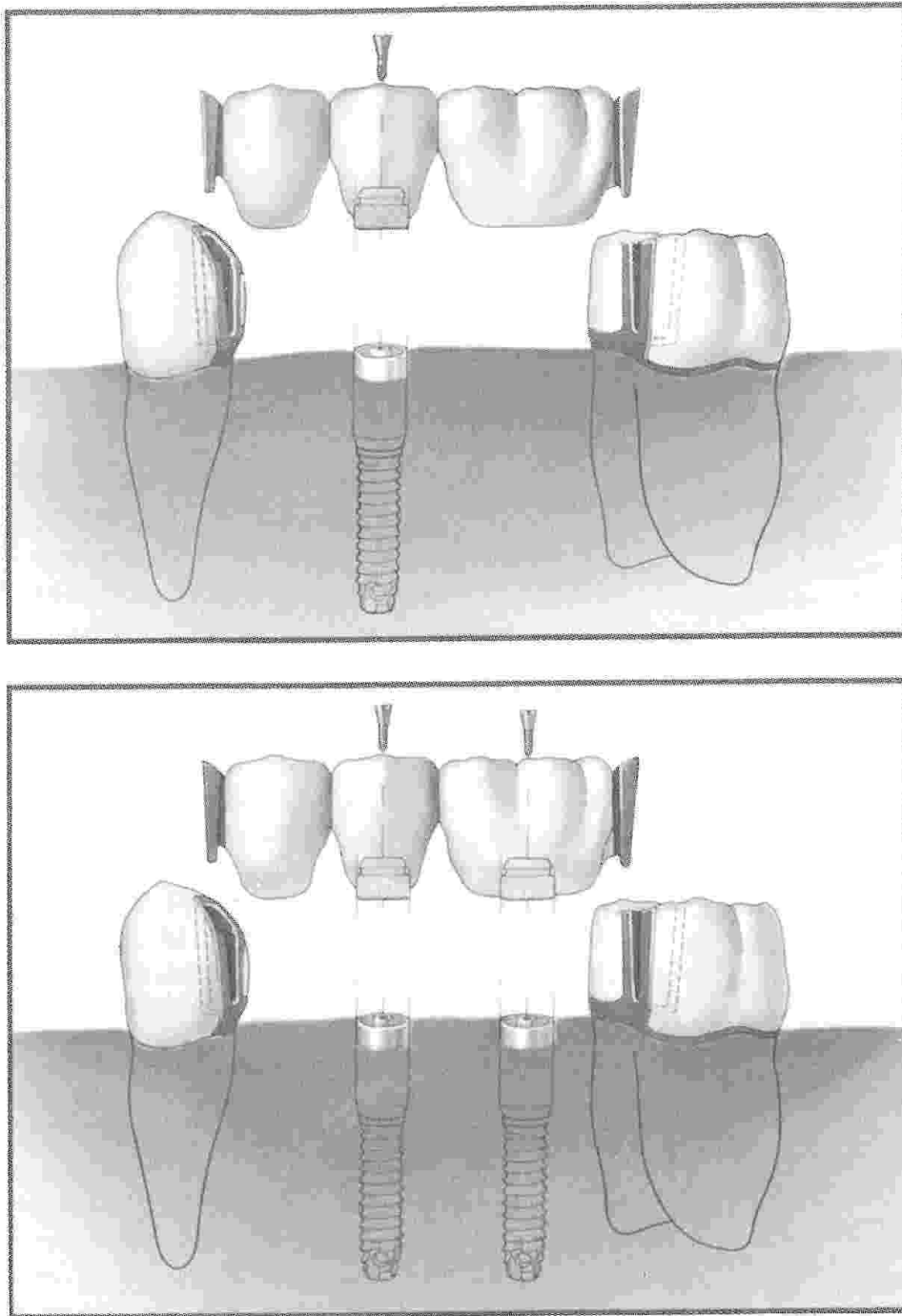


Figure 4. Precision attachments create a nonrigid connection to the natural teeth. (From Langer B, Sullivan D: Osseointegration: Its impact on the relationship of periodontics and restorative dentistry. *Int J Periodont Restor Dentist* 9:165-184, 1989; with permission.)

cluded that more uniform stress was obtained around the implant with a low E-modulus of the stress-absorbing element. This study also showed that the bone surrounding the natural tooth revealed a decrease in the height of the peak stresses.

Rigid connection, if close enough to the natural tooth, may immobilize teeth. This concept has been effective in the treatment of periodontally mobile teeth^{3, 4} (Fig. 5).

THE PERIODONTAL LIGAMENT

When reviewing osseointegrated implants connected to natural teeth, one must consider the effect of the periodontal ligament. This structure is organized fibrous connective tissue with a specific functional orientation and acts as a protective mechanism, providing resiliency and shock absorption. It stimulates surrounding bone to effect bone remodeling, as seen in

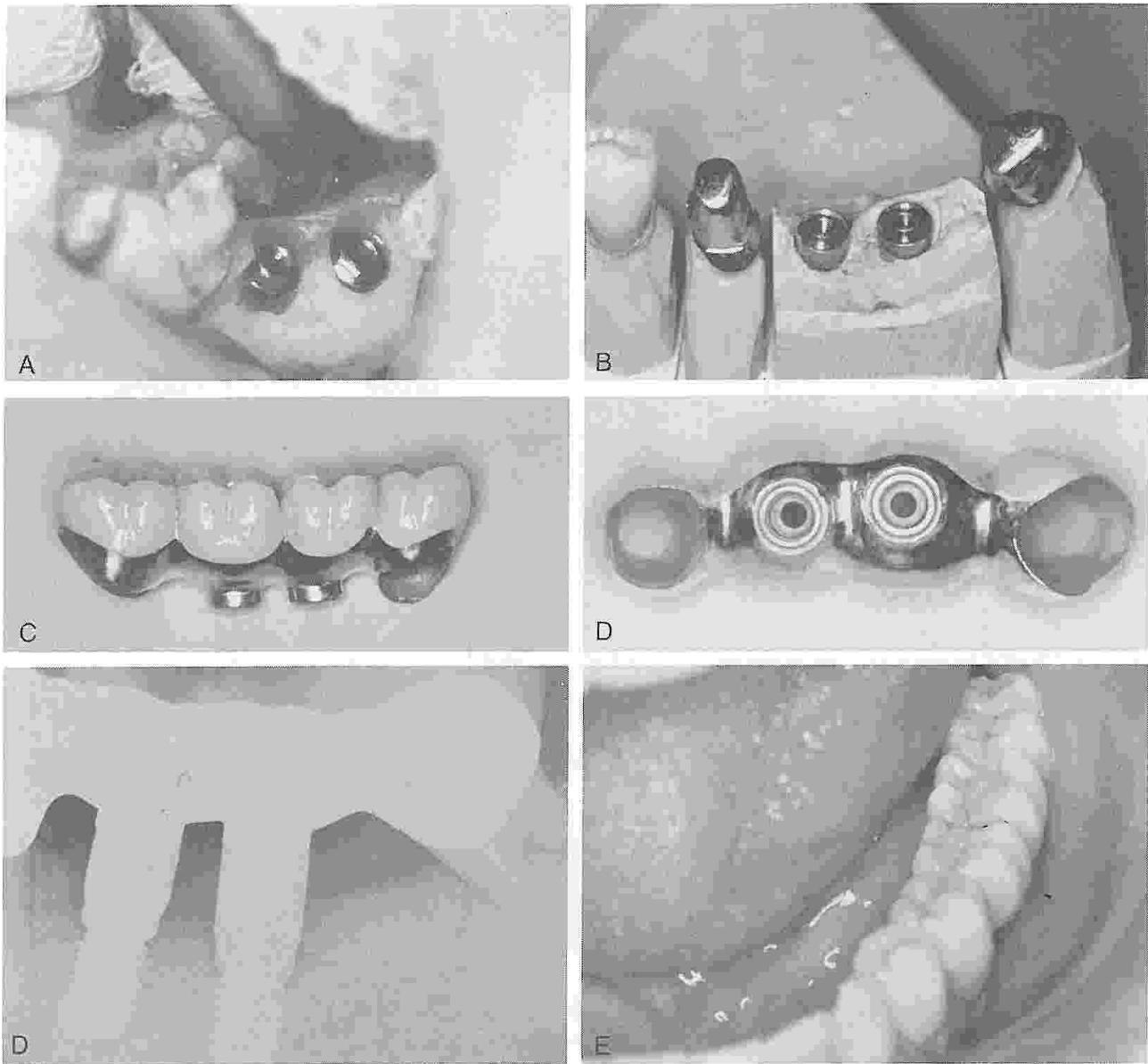


Figure 5. Use of rigid connection to control periodontically mobile teeth. *A*, Two 10-mm Brånemark fixtures are placed at the crest of the residual ridge in the area of the first and second molars. *B*, Gold telescopic copings are cemented to the periodontically mobile molar and bicuspid. *C*, Lingual view of the two fixture-supported tissue-integrated prostheses. *D*, Ridge facing view of the implants with molar and bicuspid overcasting. *E*, Postdelivery radiograph. *F*, Clinical occlusal view of complete prosthesis stabilizing the molar and bicuspid.

orthodontic tooth movement. Through its neuroreceptors, the ligament provides a proprioceptive response mechanism. It is, however, the resiliency factor that makes the ligament-supported tooth so very different from the osseointegrated implant, especially when connection of the two with a prosthesis is contemplated.

The stabilization of periodontally mobile teeth using osseointegration in adjacent edentulous areas has been described³ (see Fig. 5) for partially edentulous arch segments as well as

for full-arch rehabilitation incorporating periodontally mobile teeth⁴ joined to the tissue-integrated prosthesis with telescopic copings (Fig. 6).

When connecting natural teeth to osseointegrated implants, the surgeon should consider the fact that the implants and prosthesis will have virtually no movement, whereas teeth will move to various degrees in the sockets. The closer the implant and the teeth, the less movement or functional support is provided by the tooth, whereas with increased distance, more

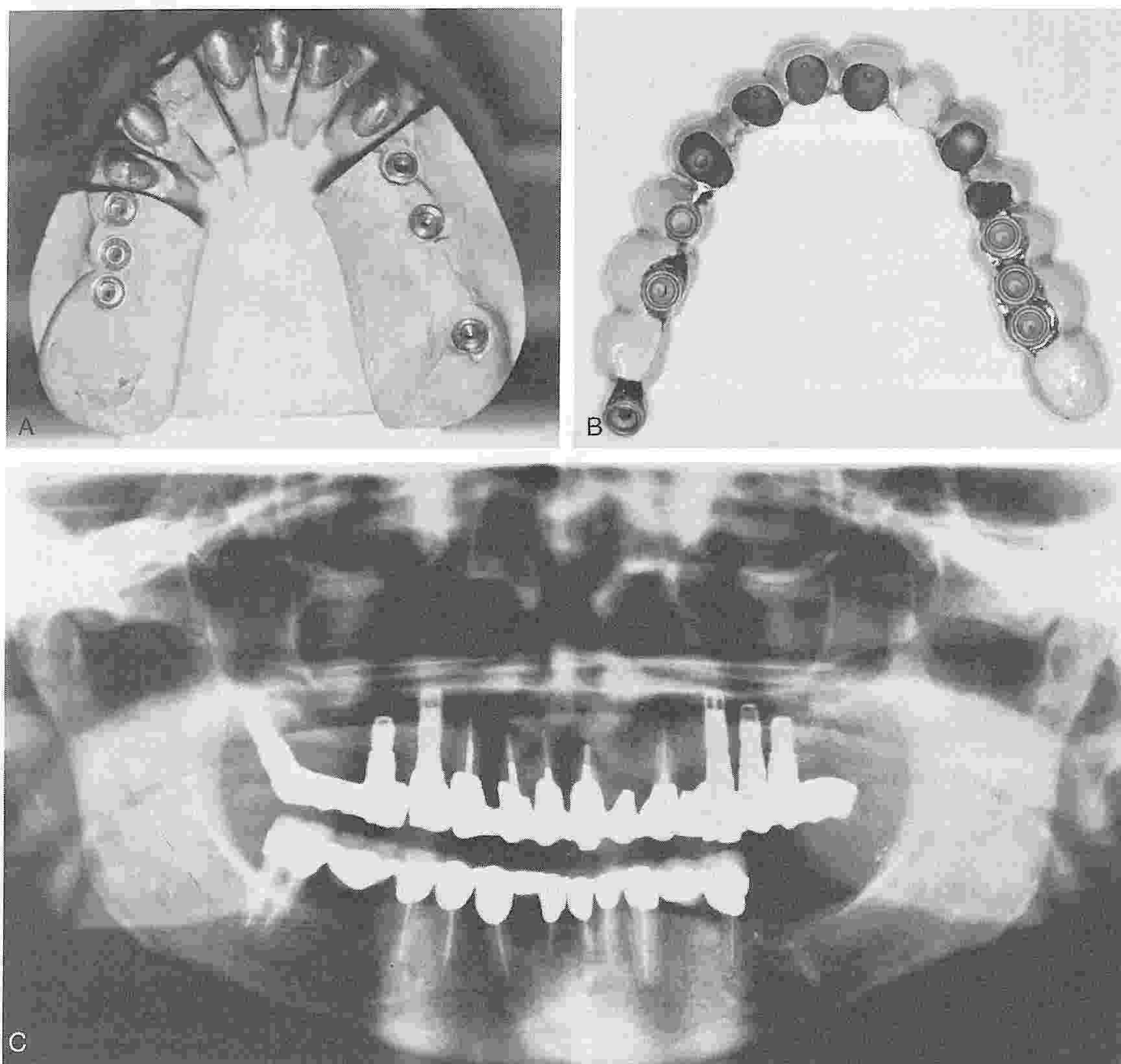


Figure 6. Full arch rehabilitation. *A*, Maxillary anterior teeth are restored with cast gold telescopic copings. *B*, The porcelain-gold prosthesis is supported by Brånemark fixtures in the posterior edentulous areas and periodontally compromised teeth in the anterior areas. *C*, Fixture position relative to the natural dentition supporting the full reconstruction.

functional support will be provided. Such an example is diagrammatically illustrated by Langer and Sullivan^{20, 20a} (Fig. 7). A fixed bridge is supported by a single canine and a single canine implant on the opposite side.

IMPLANT LOCATION FOR PARTIAL PROSTHESIS

The location of fixtures for the partially edentulous patient must take account of four biologic considerations: (1) bone quality; (2) bone quantity; (3) bone configuration; and (4) remaining teeth. The quality and quantity of bone will influence the number, location, and size of the fixtures used to restore a partially edentulous area. The generally accepted rule calls for the greatest number of fixtures of the longest length for areas of inferior bone quality and quantity, such as the mandibular posterior and maxillary posterior regions.

Although the maxillary tuberosity has poor-quality bone, the region of the pterygoid plates beyond the tuberosity has proved to provide ample stability for osseointegration and for posterior prosthesis support (Fig. 8). Bone configuration in both jaws affects the use of osseointegrated implants and must be considered in the treatment planning stages. The most important factors are the general osseous form, the contents of the body of bone, its border limitations, and adjacent structures.

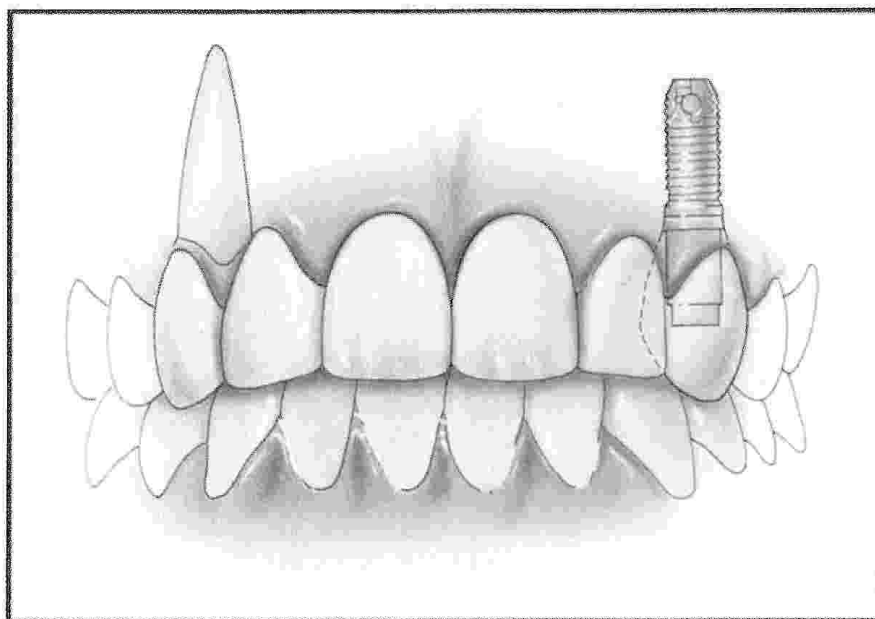
The neurovascular bundle in the body of the mandible frequently inhibits direct fixture placement in longstanding partially edentulous areas where resorption is advanced (Fig. 9). The accurate location of the neurovascular bundle via CT scan reformatted imaging or conventional tomograms is helpful, as discussed earlier in this issue. When insufficient bone is available above the neurovascular bundle, buccal displacement of the bundle should be considered. When the bundle is moved laterally, the surgeon can take advantage of the full length of the remaining mandibular bone, providing longer fixtures (Fig. 10).

In the maxilla, an inadequate amount of bone in the area of the antrum or the floor of the nose may be treated through the use of autogenous bone grafting from a variety of donor sites, depending on the volume required. With the exception of a rigid block section of donor bone, most grafts should be allowed to heal for a minimum of 4 months, and preferably 6 months, prior to fixture placement. Grafting is discussed extensively in earlier articles in this issue.

MAXILLARY ANATOMIC CONSIDERATIONS FOR THE PARTIALLY EDENTULOUS

The nasal cavity generally does not present a problem for the partially edentulous patient
(Text continued on page 956)

Figure 7. Appropriate position of osseointegrated fixture in anterior maxilla. Fixture should be positioned apical to the cemento-enamel junction of contralateral tooth to allow for prosthetic components. (From Langer B, Sullivan D: Osseointegration: Its impact on the relationship of periodontics and restorative dentistry. *Int J Periodont Restor Dentist* 9:165-184, 1989; with permission.)



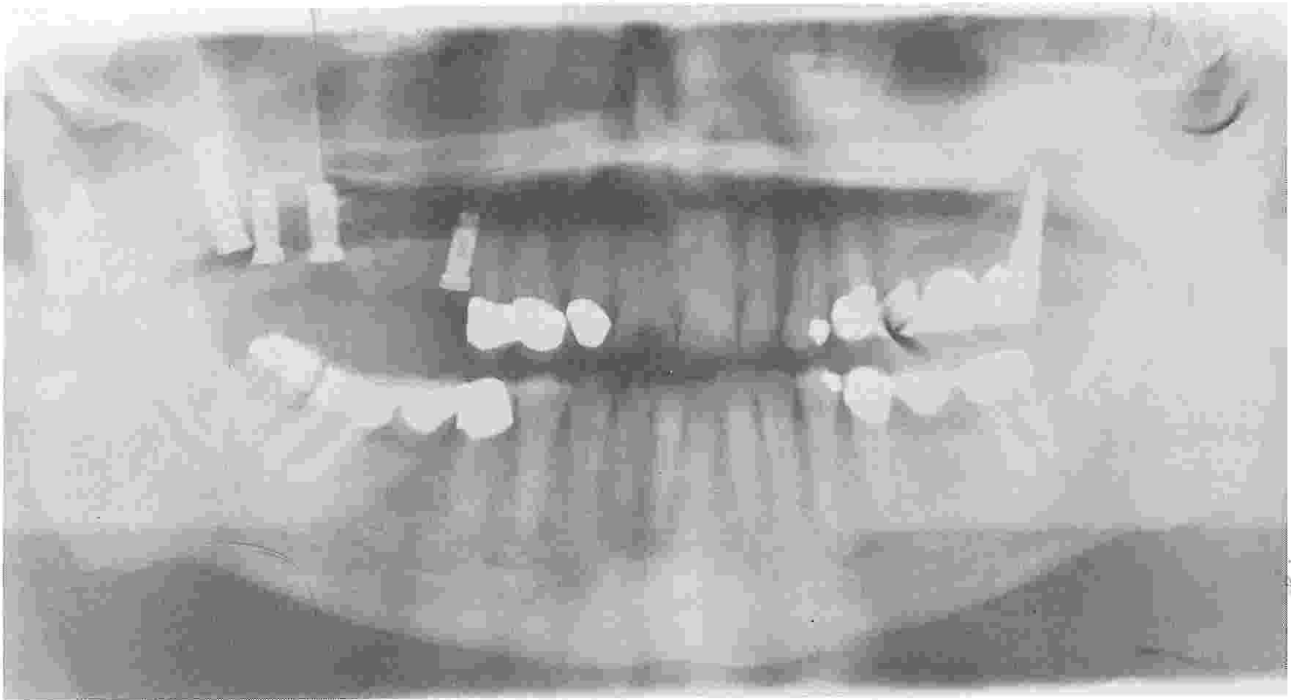


Figure 8. Pterygoid maxillary fixture provides the distal abutment support, with the natural premolar serving as the anterior abutment.

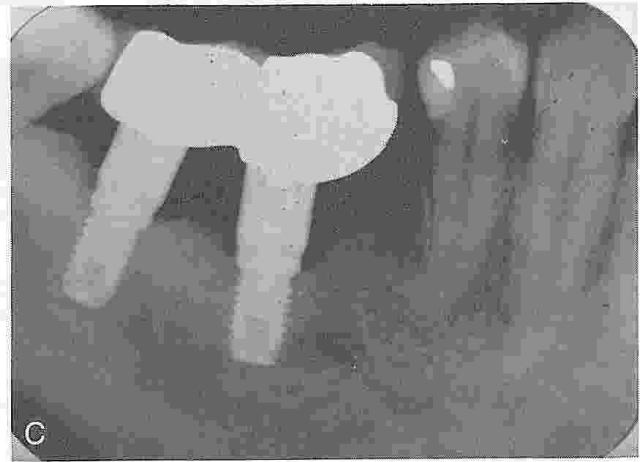
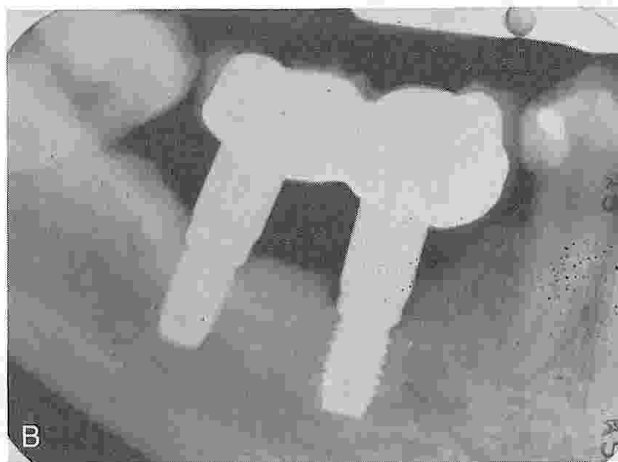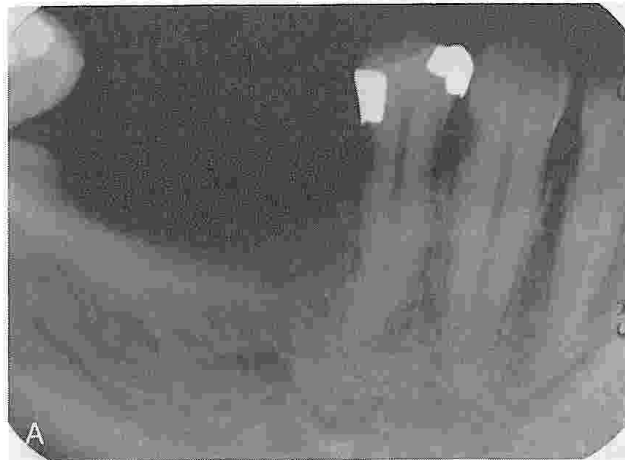


Figure 9. Avoidance of neurovascular bundle in mandible with advanced resorption. *A*, Preoperative radiograph shows bone over the inferior alveolar canal; CT scans were used to determine the position of the canal. *B*, Fixtures inserted to avoid the canal with a fixed prosthesis at time of placement. *C*, Five-year postoperative radiograph demonstrates excellent maintenance of bone.

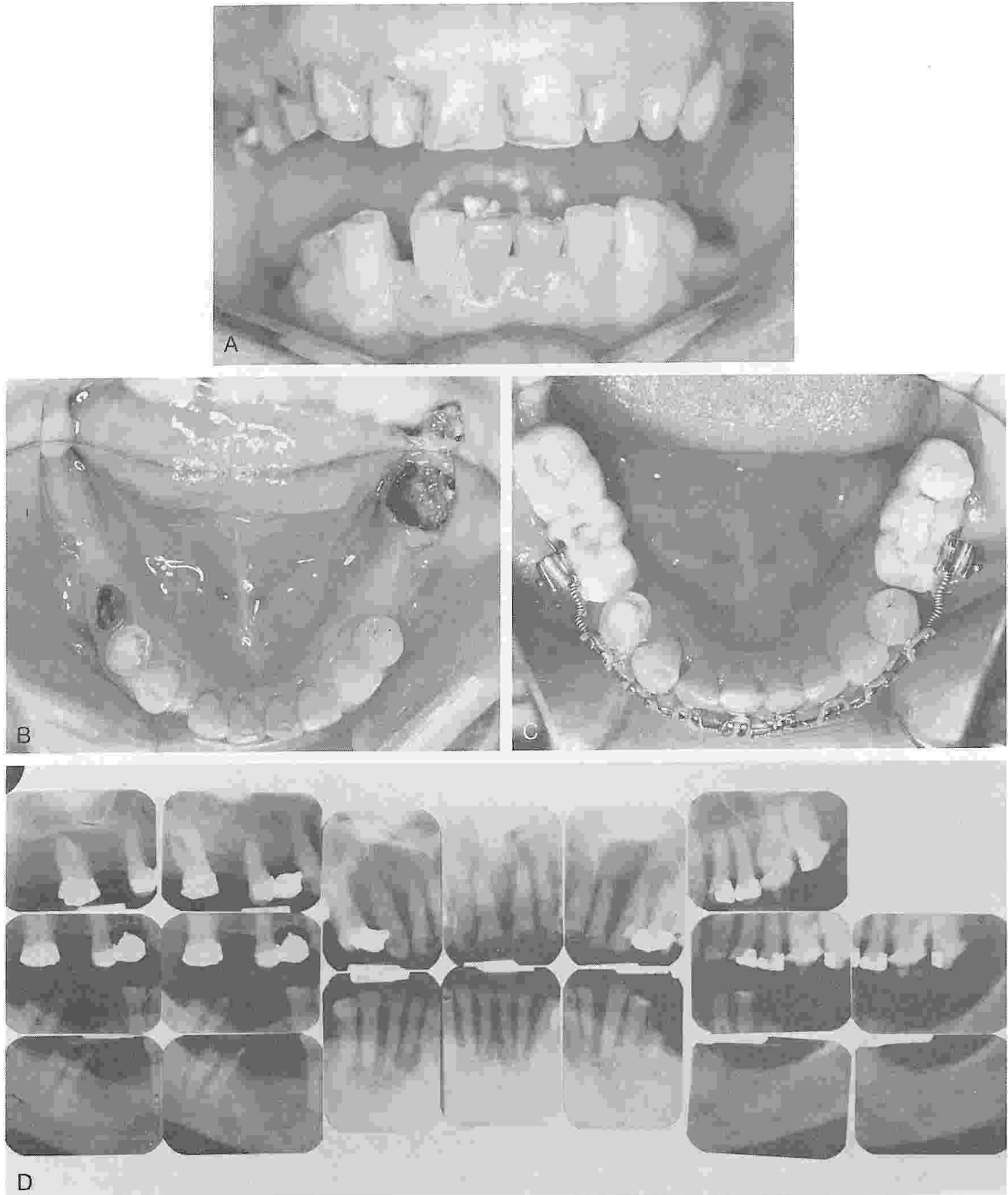


Figure 10. Placement of longer fixtures after movement of neurovascular bundle. *A*, Pretreatment anterior view shows space between mandibular right canine and lateral incisor. *B*, Occlusal view of right canine and bicuspids, which have drifted distally owing to longstanding posterior edentulism. *C*, Bilateral posterior osseointegrated implants support temporary acrylic bridges used as posterior orthodontic anchorage. Note the coiled springs and the almost-completed tooth repositioning. *D*, Pretreatment intraoral radiographs.

(Illustration continued on following page)

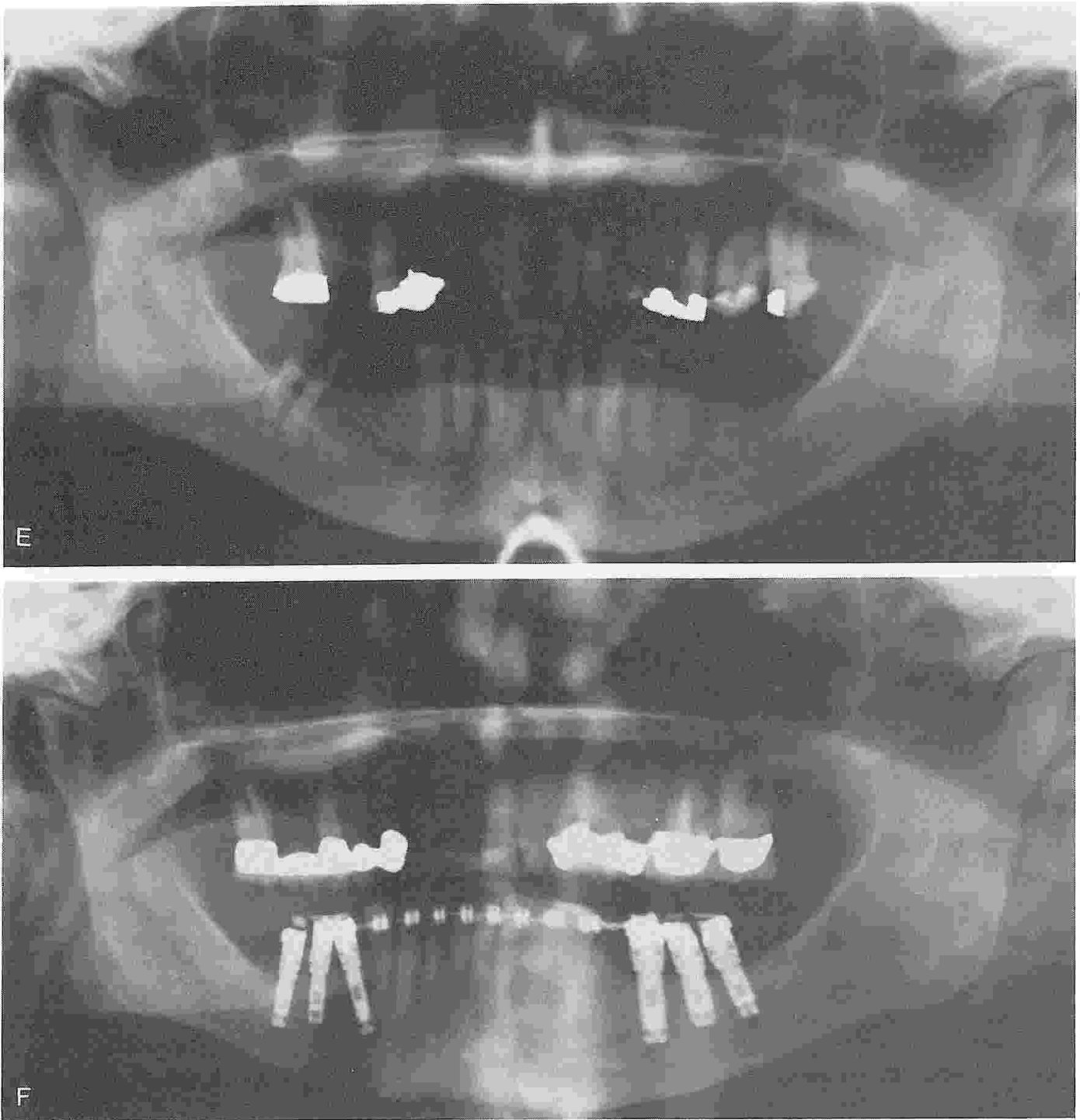


Figure 10 (Continued). *E*, Pretreatment panradiograph. Note that tooth No. 29 is not restorable. *F*, Posterior Brånemark fixtures are used for orthodontic anchorage.

(Illustration continued on opposite page)

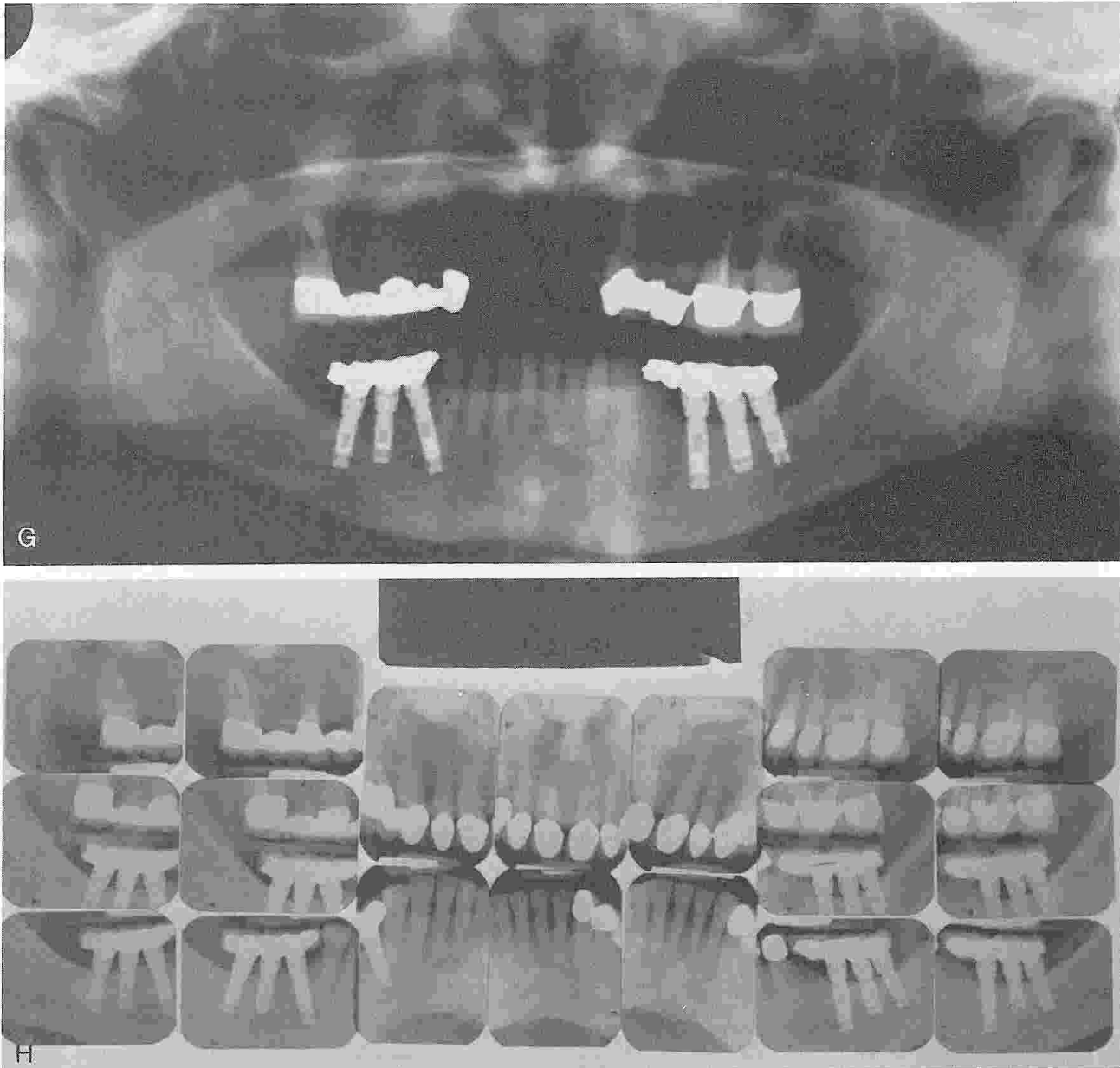


Figure 10 (Continued). *G*, Posttreatment panradiograph shows bilateral mandibular implant prosthesis after orthodontic treatment. *H*, Posttreatment intraoral radiographs demonstrate postorthodontic use of implants for independent prosthesis.

unless teeth and bone were lost in trauma (Fig. 11). If minimal bone is available, either autogenous onlay grafting from the iliac crest or autogenous inlay grafting, as described by Higuchi,¹⁵ may be necessary. If the patient has a high lip line during speech, laughing, or smiling, a gingival replacement unit should be included in the treatment plan.⁹

Below the sinuses, a minimum of 9 mm of bone is recommended for the placement of a 10-mm screw-type fixture that engages the cortical plate of the sinus floor (see Fig. 8). If less bone is available, autogenous grafts should be considered.

Although several authors have discussed the poor quality and prognosis for osseointegration in the posterior maxilla,¹⁶ other authors (T Balshi, manuscript submitted), including some clinicians previously reluctant to use the maxillary posterior region, have found that the pterygo-maxillary area often provides excellent stability on initial fixture placement and good long-term results (see Fig. 8).¹⁷ This location becomes especially important for partially edentulous patients with enlarged maxillary sinuses (P-I Brånemark, personal communication, 1989).

MANDIBULAR ANATOMIC CONSIDERATIONS FOR THE PARTIALLY EDENTULOUS

When severe resorption or traumatic loss of bone has occurred, shorter implants are re-

quired. A minimum of 8 to 9 mm of bone can be acceptable for the placement of a 10-mm fixture, with its apex penetrating the inferior cortical plate by 1 or 2 mm.

The center of the fixture placed medially to the mental foramen is generally 5 mm away for planning purposes. The surgeon must identify any possible anterior component to the neurovascular bundle. The lingual undercut should be observed during dissection to establish proper implant inclination and to prevent large perforations.

Knife-edge ridges, usually in long-span edentulous areas, may require alveoloplasty if sufficient bone is available for fixture placement above the inferior alveolar canal. If the quantity of bone is insufficient, the treatment plan may call for a dehiscence of the implant on the facial and lingual to be covered by barrier materials such as Vicryl mesh or Gore-Tex, which help promote bone growth surfaces.^{8, 18}

GUIDESTENT FABRICATION

The use of surgical guidestents with partially edentulous patients has been reported to provide distinct advantages.^{2, 10, 22} If a single 3.75-mm-diameter fixture is placed between adjacent teeth, a minimum of 7 mm of intertooth space is required to permit approximately 1.5+ mm of alveolar bone between the root cementum and the fixture threads. If two fixtures are considered, the optimal distances of the fixture

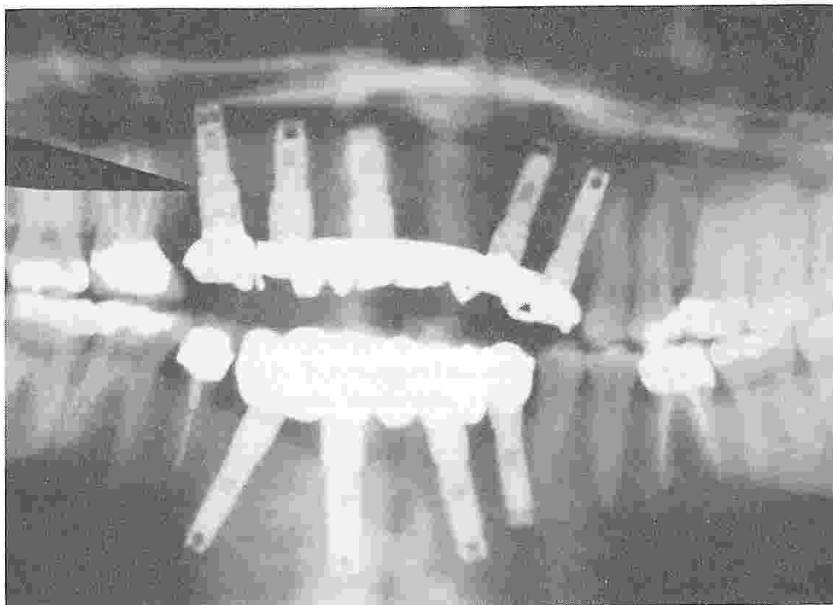


Figure 11. Maxillary anterior implants in bone remaining below the nasal cavity after traumatic loss of the alveolar ridge.

closest to the natural tooth is 3 mm. If less bone is available, the minimal distance should be 1.5 mm. The ideal interfixtural distance is also 3 mm. However, in some circumstances, such as the replacement of a single molar, two fixtures may be placed in a 12-mm space, permitting 2 mm of space between the fixtures and the teeth.^{6, 16}

TOOTH LOCATION AND IMPLANT-ASSISTED ORTHODONTICS

Examination of the location of the remaining teeth relative to the edentulous area should

include consideration of long-axis angulation. Often, in longstanding partially edentulous conditions, drifted teeth require orthodontic repositioning. Gupton has used osseointegrated fixtures successfully in adjacent edentulous areas as anchorage elements for tooth movement (S Gupton, personal communication, 1991) (see Fig. 10). Fixtures are helpful for anterior consolidation to close spaces, as well as for molar uprighting to recapture spaces where molars have been lost (Fig. 12). The posterior maxillary fixtures (Fig. 13) provided 2 years of anchorage to correct a deep overbite. These same osseointegrated fixtures may subsequently be used for prosthesis support.

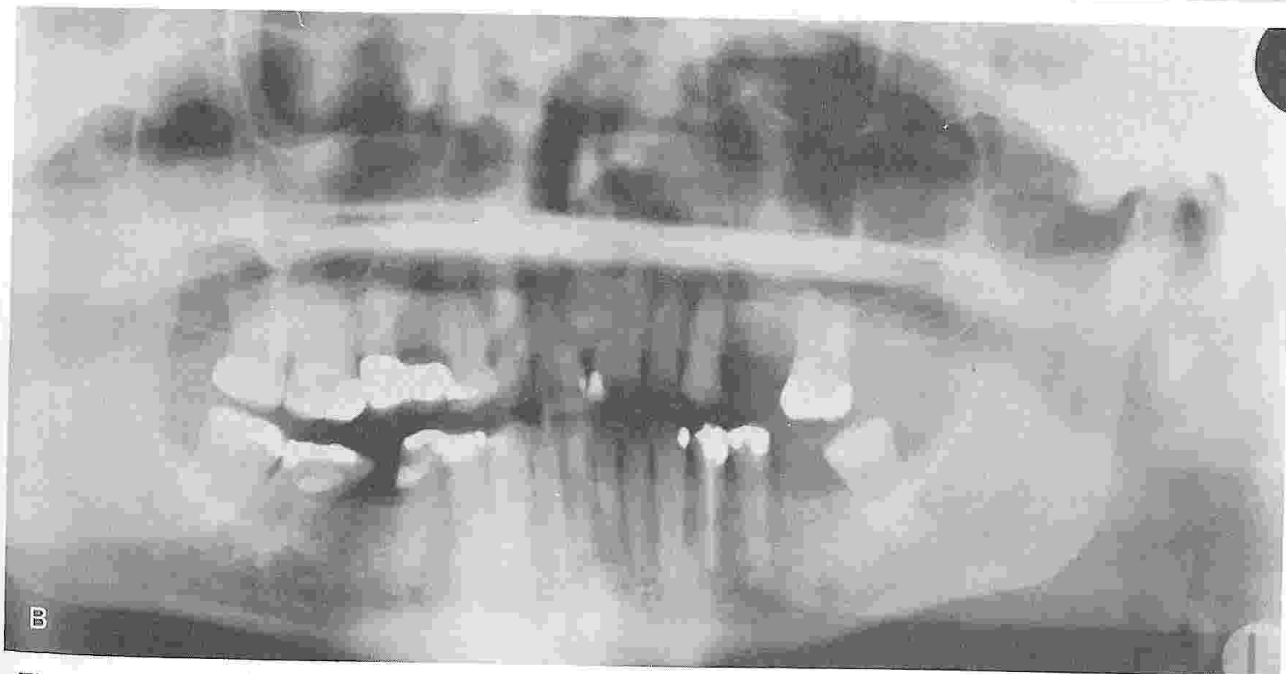
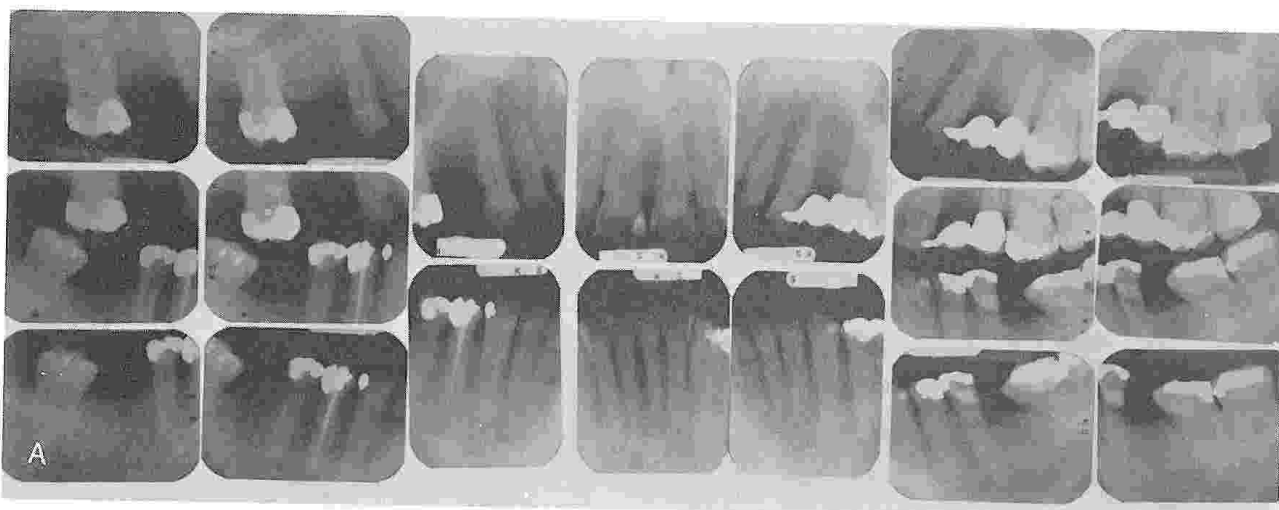


Figure 12. Use of implants in consolidation and uprighting. A, Pretreatment radiographs. Note missing mandibular molars and tilted adjacent teeth. B, Pretreatment panradiograph.

(Illustration continued on following page)

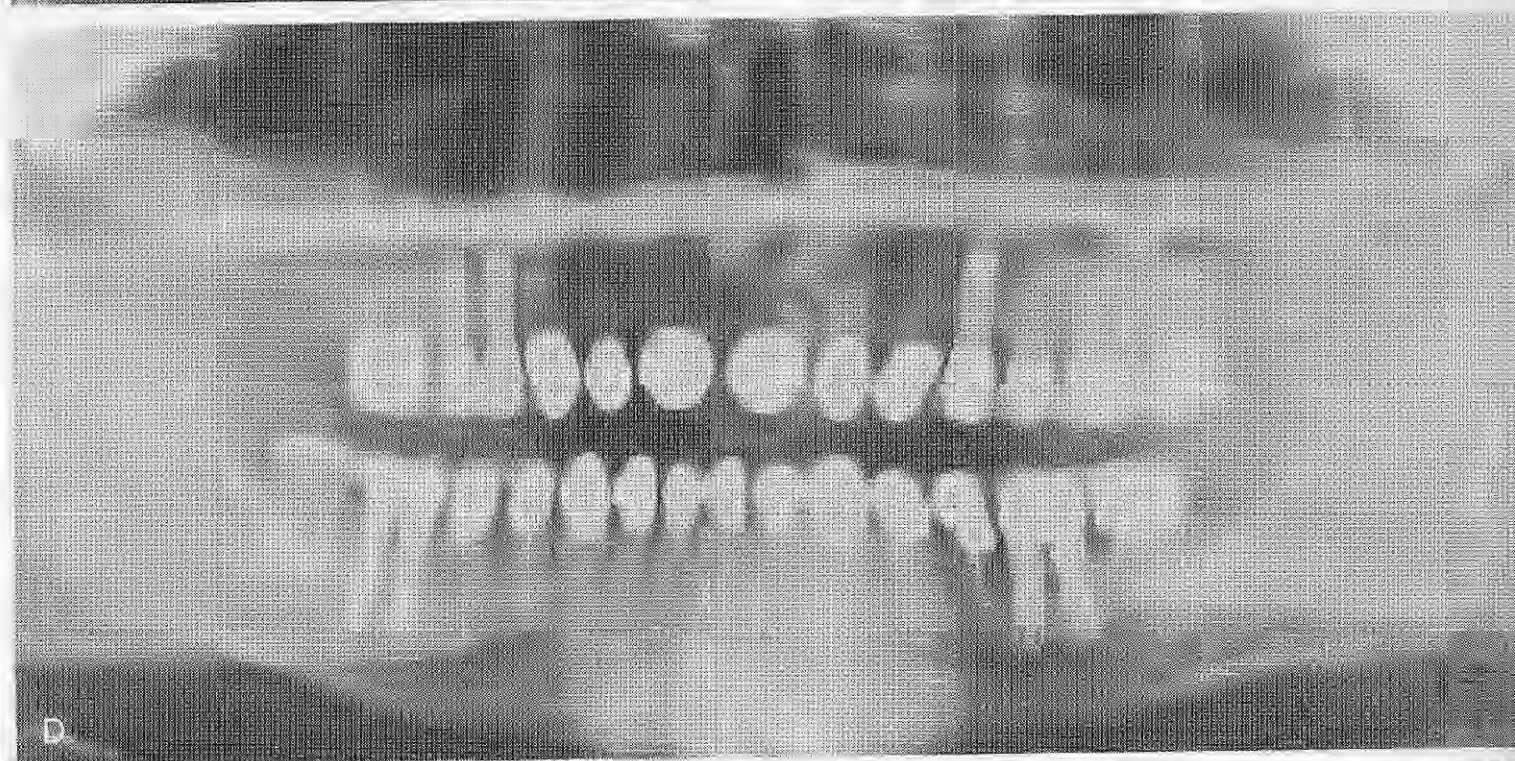



Figure 12 (Continued). C, Midtreatment panoramic radiograph. Orthodontic molar uprighting prepares space for implant placement. D, Posttreatment panoramic radiograph. Posterior tooth replacement supported by Brånemark fixtures independent of the orthodontically repositioned natural dentition.

RESTORATIVE CONDITION: VIRGIN VERSUS PRERESTORED

Fixture location is also affected by the condition of adjacent teeth. If these teeth are healthy and without restorative need, one should consider multiple fixture placement if possible, based on available bone and interdental space. The final prosthesis should not be connected to the natural dentition (see Figs. 10G, 12D, and 13F). In similar biologic circumstances where only a single fixture can be placed, antirotational prosthetic components should be used to connect the single-tooth prosthesis to the osseointegrated fixture, rather than to the natural tooth (Fig. 14).

Under no circumstances should a lingual or occlusal finger-rest or "stabilizing arm" be extended onto the virgin unrestored enamel of an adjacent tooth. Movement of the natural tooth inevitably permits bacteria to initiate caries beneath the strut of the finger-rest casting regardless of the accuracy of the contact at the time of delivery. The temptation to use resin bonding material to fasten such rest extensions

to the enamel should also be avoided, with the realization that the implant-supported prosthesis rigidly connected to the osseointegrated fixture will not have the mobility inherently provided by the periodontal ligament of the tooth intended to function as an antirotational element. Under occlusal load, the tooth may be depressed into its socket, breaking the bond between the enamel and the strut of a finger-rest.

PERIODONTAL CONDITION OF THE NATURAL TEETH

Connecting for Prosthesis Support

If only a single fixture can be placed as an abutment for a fixed prosthesis requiring the use of a natural tooth as the other abutment, the tooth should have good periodontal health with no clinical mobility. Whenever possible, the fixture should be placed over two teeth distal or mesial to the abutment tooth or several teeth away (see Fig. 7; Fig. 15).

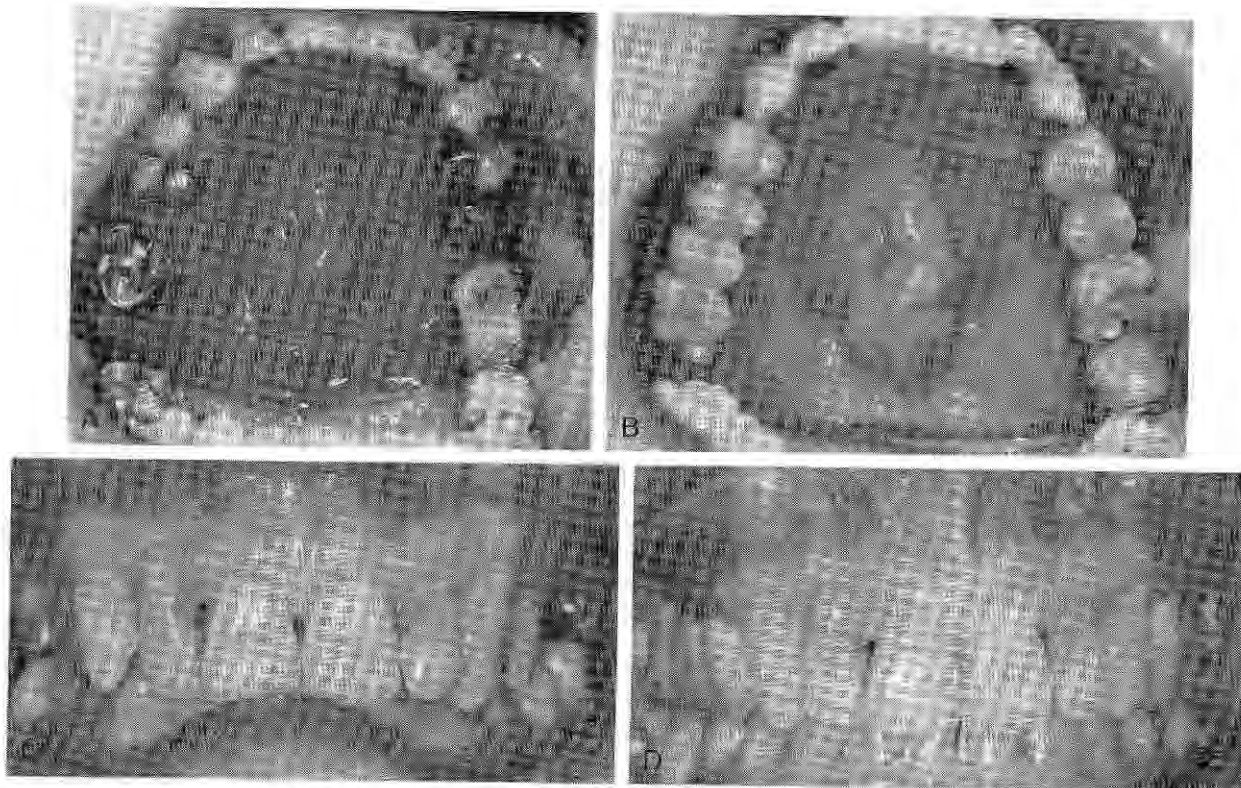


Figure 13. Correction of deep overbite with aid of posterior maxillary fixtures. A, Palatal view of active orthodontic treatment with acrylic temporary prosthesis on two osseointegrated implants used as posterior anchorage. B, Porcelain-gold implant-supported prosthesis is constructed after completed orthodontics. C, Preoperative deep overbite. D, After implant-assisted orthodontics corrected the deep overbite.

(Illustration continued on following page)

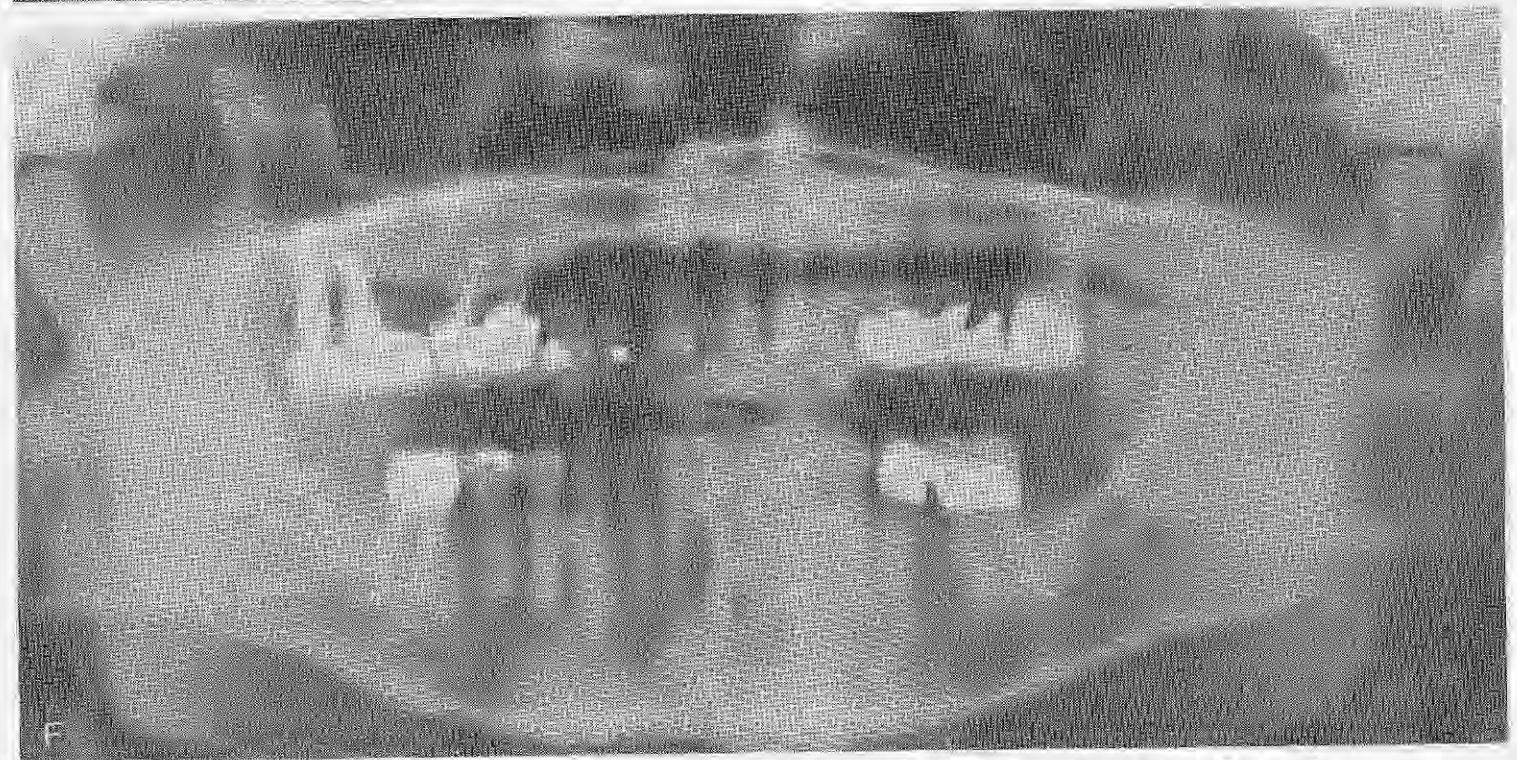
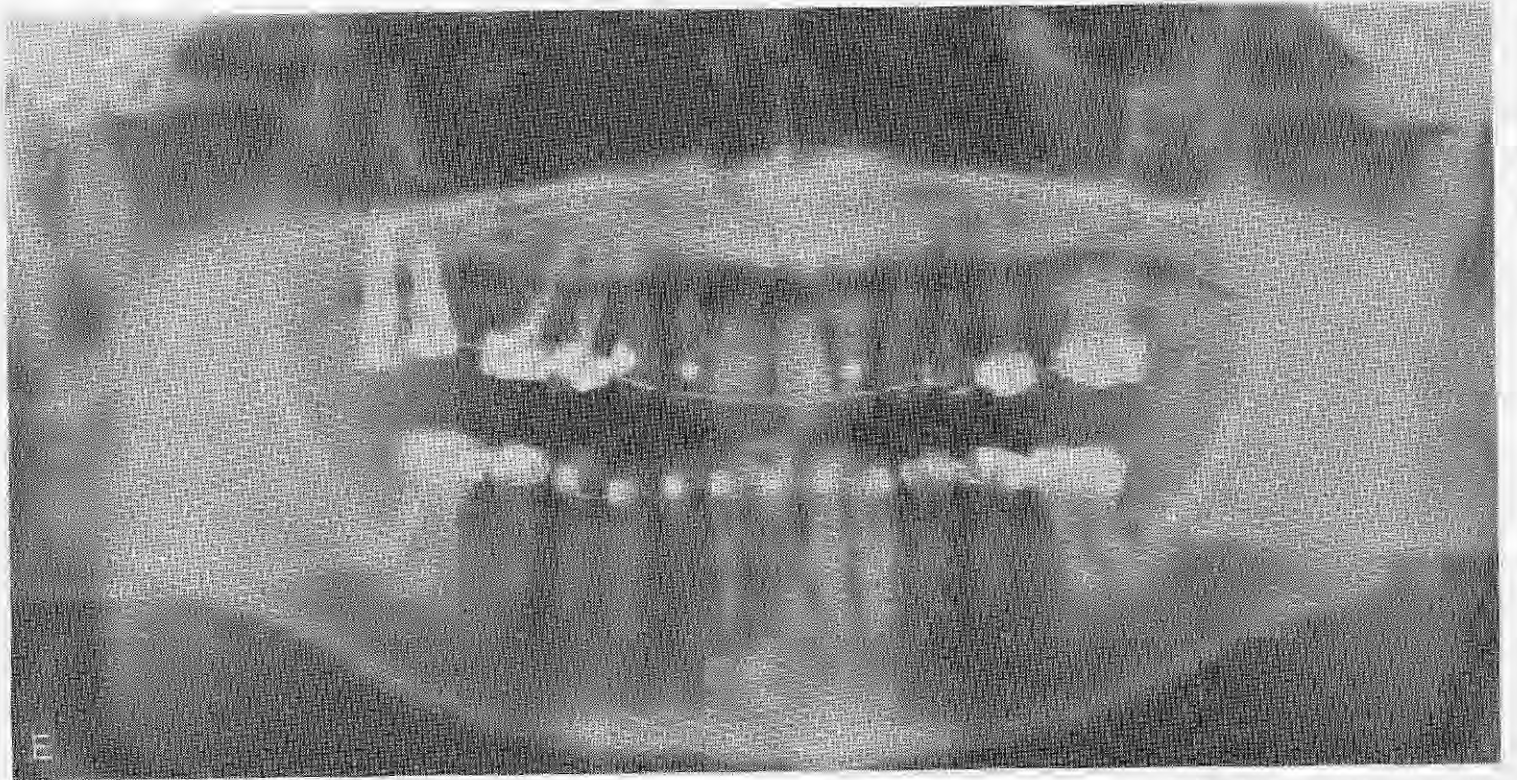


Figure 13 (Continued). E. Midorthodontic panradiograph. F. Posttreatment panradiograph.

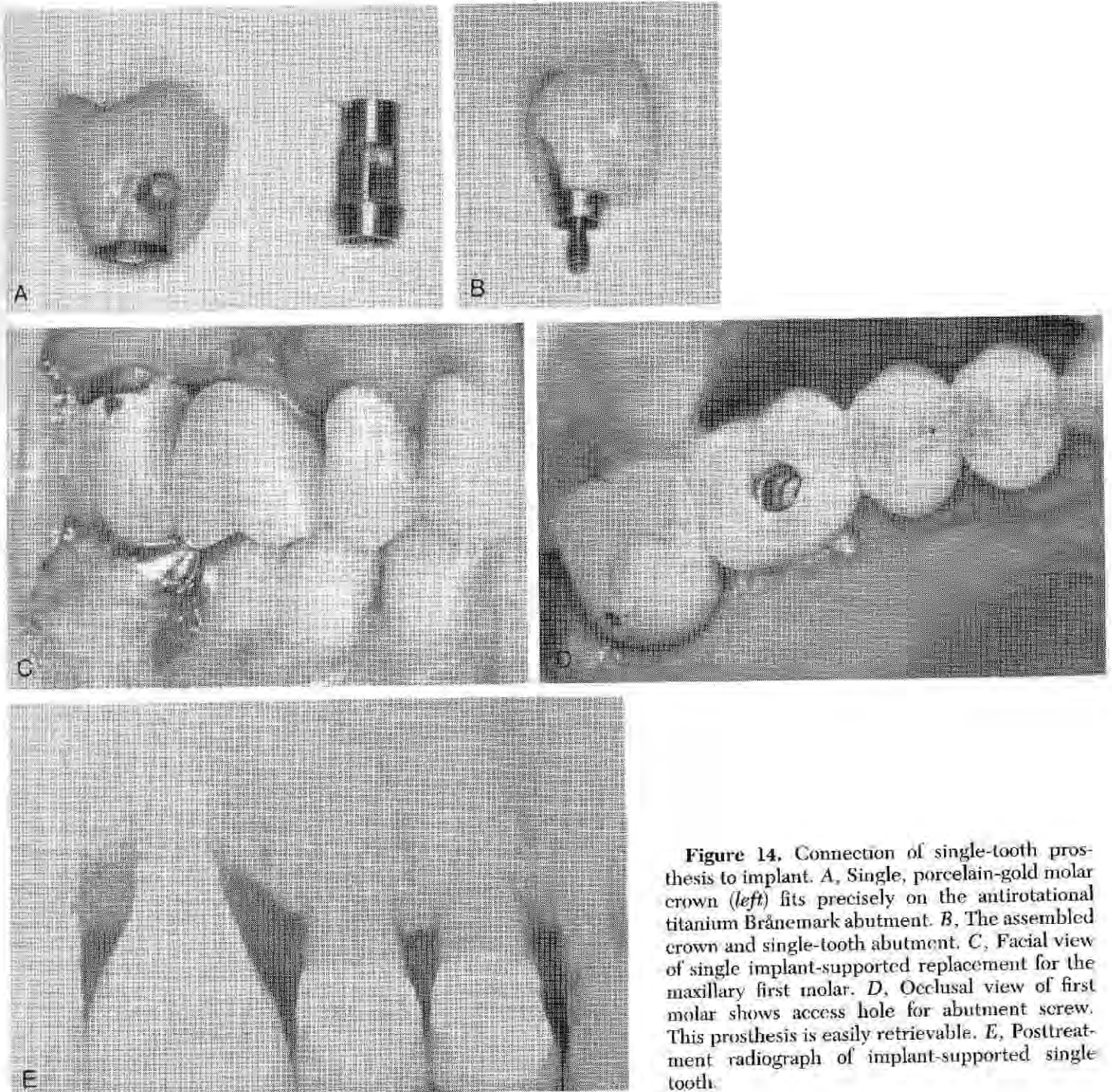


Figure 14. Connection of single-tooth prosthesis to implant. *A*, Single, porcelain-gold molar crown (*left*) fits precisely on the antirotational titanium Brånemark abutment. *B*, The assembled crown and single-tooth abutment. *C*, Facial view of single implant-supported replacement for the maxillary first molar. *D*, Occlusal view of first molar shows access hole for abutment screw. This prosthesis is easily retrievable. *E*, Posttreatment radiograph of implant-supported single tooth.

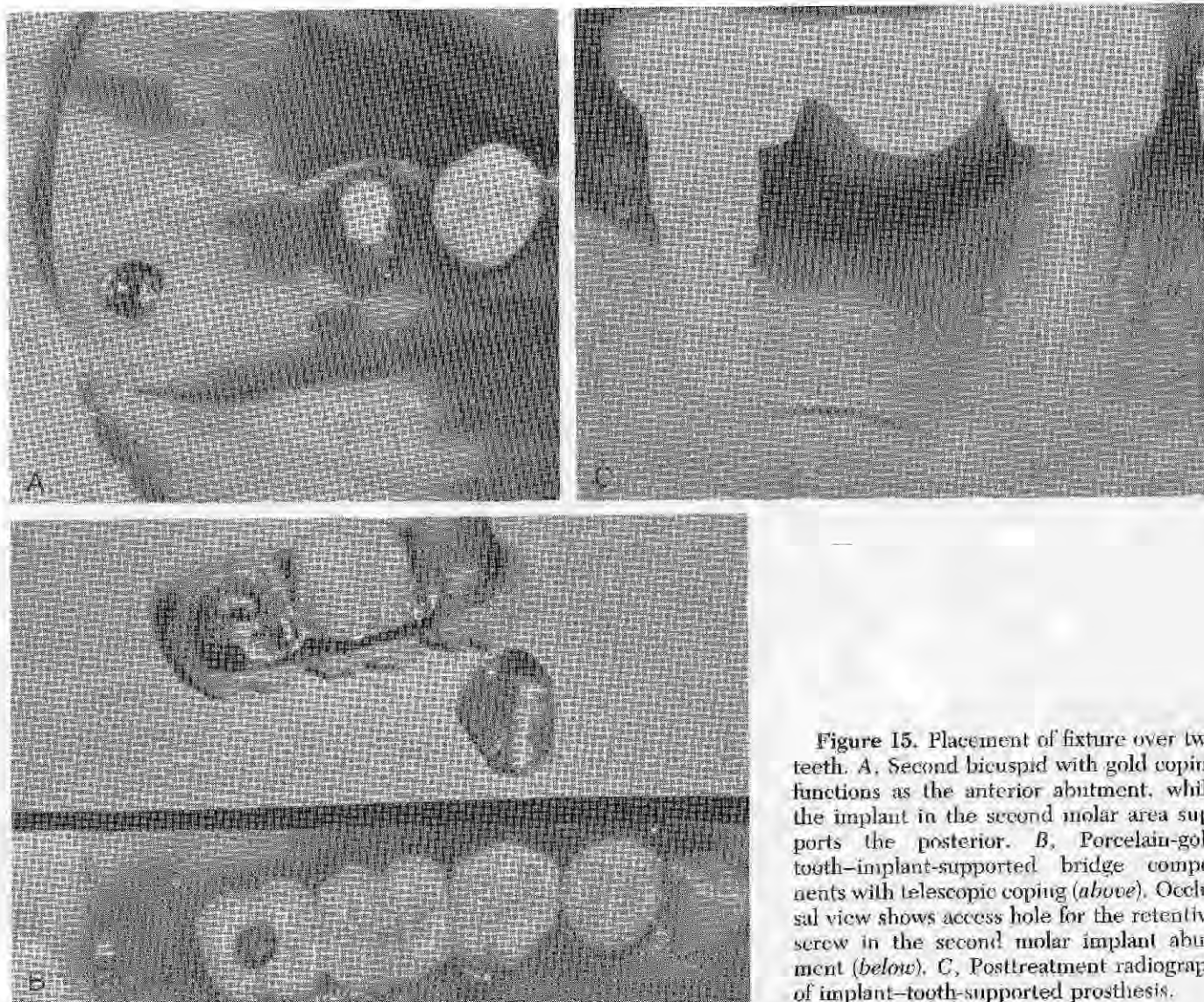


Figure 15. Placement of fixture over two teeth. *A*, Second bicuspid with gold coping functions as the anterior abutment, while the implant in the second molar area supports the posterior. *B*, Porcelain-gold tooth-implant-supported bridge components with telescopic coping (*above*). Occlusal view shows access hole for the retentive screw in the second molar implant abutment (*below*). *C*, Posttreatment radiograph of implant-tooth-supported prosthesis.

Connecting for Periodontal Support

Osseointegrated fixtures may be used to stabilize teeth when the natural dentition has suffered from diminished periodontal support secondary to periodontitis and loss of surrounding alveolar bone, shortened roots of congenital or iatrogenic origin, or longstanding parafunctional overload. Using a 0 to +3 mobility scale, only those teeth with +1 or +2 mobility should be considered for fixture-connected stabilization.

Loose anterior teeth that present with functional mobility as a result of occlusal function will generally require multiple fixtures for stabilization, because the same occlusal forces will be totally directed to the osseointegrated implants when the patient moves through the

excursive movements.^{3, 4} The forces will be transmitted to the fixtures via the essentially cantilevered crown used to stabilize the mobile tooth.

Special care must be taken in the treatment-planning stage to design a retrievable prosthesis suitable for easy modification in the future should the periodontally compromised tooth be lost (Fig. 16).

CONSTRUCTION OF THE FINAL IMPLANT-SUPPORTED PROSTHESIS

Historically, the full-arch implant-supported prosthesis reported by Swedish researchers was constructed of resilient veneer material, such as acrylic resin (Laboratory of Experimental

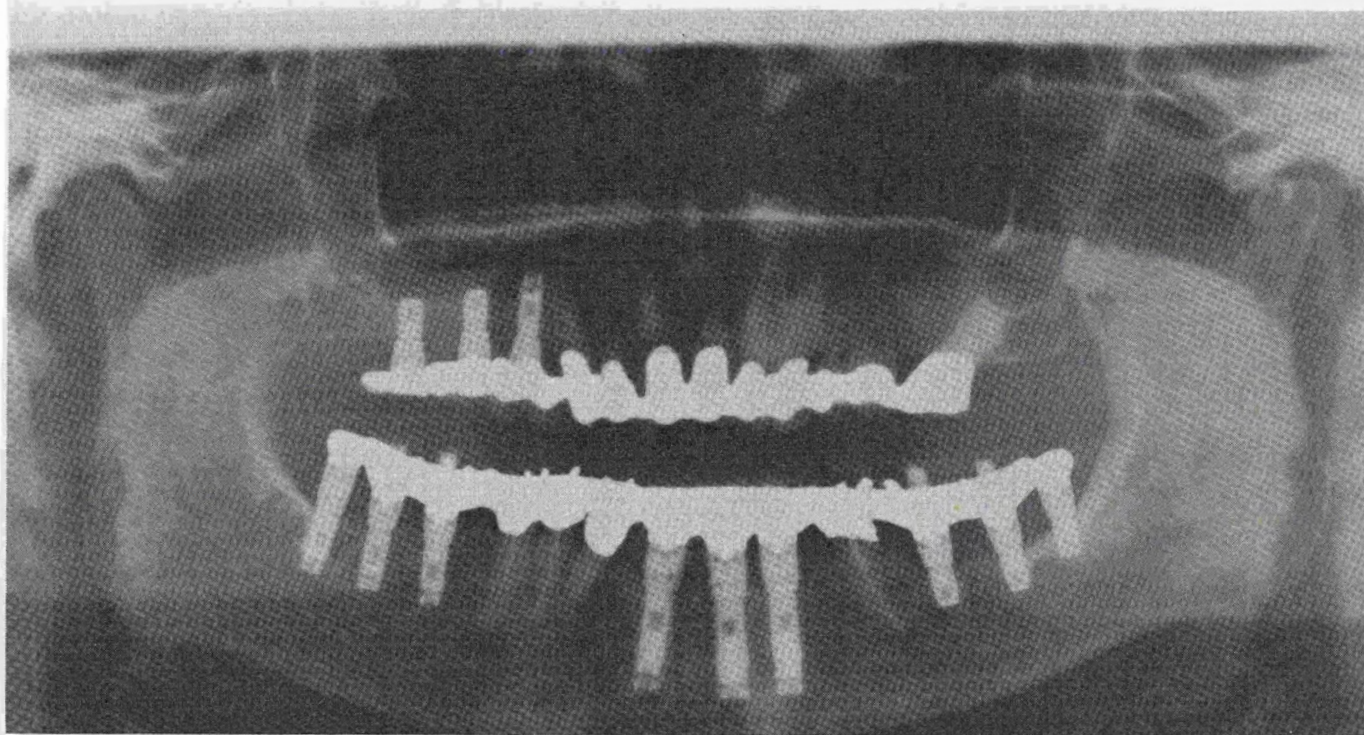


Figure 16. Posttreatment panoramic radiograph shows periodontally mobile bicuspids and left canine stabilized by an implant-supported prosthesis.

Biology, University of Göteborg, Sweden, unpublished data). Porcelain has proved to be an effective veneer material for osseointegrated implant bridges.⁵ If porcelain is selected for a tissue-integrated prosthesis, the opposing dentition should be supported by natural teeth so that the periodontal ligament will function as a shock absorber. If the porcelain prosthesis is to be opposed by another implant-supported dentition, that prosthesis should be veneered with a more resilient material. The use of a porcelain tissue-integrated prosthesis opposed by another porcelain tissue-integrated prosthesis may in time produce fractures in the porcelain or at the implant-bone interface.

DESIGN DISTRIBUTION AND MATERIALS

The four Kennedy classifications of partially edentulous patients may be applied to individuals to be restored with a tissue-integrated prosthesis. The classifications are valid in both maxilla and mandible for independent prostheses and for those connected to the natural teeth.¹⁶

For the maxillary anterior implant-supported

prosthesis, porcelain fused to gold is the material of choice. Porcelain provides excellent color stability and wear characteristics. Should an opposing implant prosthesis be required, porcelain may be used, with great care taken to minimize centric impact while maintaining appropriate contact for occlusal guidance in excursive movements.

SUMMARY

The Brånemark method of osseointegration has offered a multitude of possibilities for restoration of the partially edentulous patient. When Brånemark fixtures are used as abutments in conjunction with the natural dentition, the difference in the attachment mechanisms to bone should be kept in mind. The resiliency of the periodontal ligament must be taken into account in the bridge construction. When teeth and implants are used for prosthesis support, the design should be completely retrievable. Telescopic copings and precision attachments are essential design elements for the implant-tooth prosthesis. However, whenever the opportunity presents, optimal prosthetic design calls for a totally implant-supported prosthesis with no connection to the natural dentition.

REFERENCES

1. Albrektsson T, Zarb GA, Worthington P, et al: The long term efficacy of currently used dental implants: A review and proposed criteria of success. *Int J Oral Maxillofac Implants* 1:11-25, 1986
2. Balshi T: Surgical guidestents for placement of implants. *J Oral Maxillofac Surg* 45:463-465, 1987
3. Balshi T: Osseointegration for the periodontally compromised patient. *Int J Prosth* 1:51-58, 1988
4. Balshi T: Converting patients with periodontally hopeless teeth to osseointegration prostheses. *Int J Periodontol Restor Dentist* 8:9-34, 1988
5. Balshi T: Use of porcelain in partial edentulism: Presented at the fourth Annual Meeting of the Academy of Osseointegration, Dallas, 1989
6. Balshi T: First molar replacement with an osseointegrated implant. *Quintessence Int* 21:61-65, 1990
7. Balshi T: Overload management of osseointegrated fixtures to achieve optimum bone remodeling through multistage prosthodontic loading. Presented at the second International Congress on Tissue Integration in Oral, Orthopedic and Maxillofacial Reconstruction, Rochester, Minnesota, September 1990
8. Balshi T, Hernandez RE, Hertzog CF, et al: Effect of Vicryl mesh (Polyglactin 910) on osseous defects, and the Brånemark implant: A case report. *Int J Oral Maxillofac Implants* (in press)
9. Balshi T, Parel S, Sullivan D, et al: Gingival augmentation for osseointegrated implant prostheses. *J Prosth Dentist* 56:208-212, 1986
10. Blustein R, Jackson R, Rotskoff K, et al: Use of splint material in the placement of implants. *Int J Oral Maxillofac Implants* 1:47-49, 1986
11. Brunski JB: The influence of biomechanical factors at the tissue-biomaterial interface. In Hanker JS, Giannara BL (eds): *Biomedical Materials and Devices, Materials Research Symposium Proceedings*, vol 10. Pittsburgh, Materials Research Society, 1989, pp 505-515
12. El Charkawi HG, El Wakad MT, Naser ME: Modification of osseointegrated implants for distal-extension prostheses. *J Prosth Dentist* 64:469-472, 1990
13. Ericsson I, Lekholm U, Lyndqvist S: Osseointegrated bridge construction in partially edentulous patients: Prosthetic reconstruction on osseointegrated implants. *Swedish Dent J* 28:157-165, 1985
14. Ericsson I, Lekholm U, Brånemark P-I, et al: A clinical evaluation of fixed-bridge restorations supported by the combination of teeth and osseointegrated titanium implants. *J Clin Periodontol* 13:307-312, 1986
15. Higuchi KW: Nasal inlay bone graft technique. Presented at the second International Congress on Tissue Integration in Oral, Orthopedic and Maxillofacial Reconstruction, Rochester, Minnesota, September 1990
16. Hobo S, Ichida E, Garcia I: *Osseointegration and Oculusal Rehabilitation*. Chicago, Quintessence Publishing, 1989
17. Hure G: Solutions for anatomic contraindications on endosseous implantologic surgery, Brånemark type. World Congress on Implantology and Biomaterials, Paris, March 1989
18. Jovanovic SA: Bone regeneration of dehiscenced titanium dental implants: A clinical study. Presented at the second International Congress on Tissue Integration in Oral, Orthopedic and Maxillofacial Reconstruction, Rochester, Minnesota, September 1990
19. Kirsch A, Ackermann KL: A ten year clinical report of the IMZ implant system: Oral rehabilitation of the partially and totally edentulous patient. *Oral Maxillofac Surg* 90:9, 1989
20. Langer B, Sullivan D: Osseointegration: Its impact on the relationship of periodontics and restorative dentistry: Part I. *Int J Periodont Restor Dentist* 9:85-106, 1989
- 20a. Langer B, Sullivan D: Osseointegration: Its impact on the relationship of periodontics and restorative dentistry: Part II. *Int J Periodont Restor Dentist* 9:165-184, 1989
21. *Oral Hygiene for the Implant Patient* (video) (Barbara Lord, RDH, producer). Fort Washington, Pennsylvania, Institute for Facial Esthetics, 1990
22. Rieder CE: Copings on tooth and implant abutments for superstructure prosthesis. *Int J Periodont Restor Dentist* 10:436-453, 1990
23. Schnitman PA, Shulman LB (eds): *Dental Implants: Benefits and Risks: An NIMH Harvard Consensus Development Conference*. Rockville, US Department of Health and Human Services, 1979
24. Sullivan DY: Prosthetic considerations for the utilization of osseointegrated fixtures in the partially edentulous arch. *Int J Oral Maxillofac Implants* 1:39-45, 1986
25. Sullivan DY, Stiglitz MP, Krogh PHJ: A solution for the prosthetic problem of the hemidentate arch: Tissue integrated prosthesis. *Int J Periodont Restor Dentist* 4:67-81, 1986
26. van Rosten IP, Braak LII, de Putter C, et al: Stress-absorbing elements in dental implants. *J Prosth Dentist* 64:198-205, 1990
27. van Steenberghe D: A retrospective multicenter evaluation of the survival rate of osseointegrated fixtures supporting fixed partial prostheses in the treatment of partial edentulism. *J Prosth Dentist* 61:217-222, 1989

Address reprint requests to

Thomas J. Balshi, DDS
 Institute for Facial Esthetics
 467 Pennsylvania Avenue
 Fort Washington, PA 19034

ORAL AND MAXILLOFACIAL SURGERY CLINICS OF NORTH AMERICA ISSN 1042-3699
November 1991 Volume 3, Number 4

Copyright © 1991 by W. B. Saunders Company. All rights reserved. No part of this publication may be reproduced or transmitted in any form or by any means, electronic or mechanical, including photocopy, recording, or any information retrieval system, without written permission from the publisher. Printed in the United States of America.

Authorization to photocopy items for internal or personal use, or the internal or personal use of specific clients, is granted by W. B. Saunders Company provided that the base fee of \$0.00 per copy plus \$0.20 per page, is paid directly to Copyright Clearance Center (CCC), Transactional Reporting Service, 27 Congress St., Salem, MA 01970. Identify this publication by including with your payment the fee code 1042-3699/91 \$0.00 + \$0.20. For those organizations that have been granted a photocopy license by CCC, a separate system of payment has been arranged. All fees are subject to change without notice.

The *Oral and Maxillofacial Surgery Clinics of North America* (ISSN 1042-3699) is published quarterly by W. B. Saunders Company. Corporate and Editorial Offices: The Curtis Center, Independence Square West, Philadelphia, PA 19106-3399. Accounting and Circulation Offices: 6277 Sea Harbor Drive, Orlando, FL 32887-4800. Second-class postage paid at Orlando, FL 32862, and additional mailing offices. Subscription price is \$79.00 per year (U.S. individuals), \$89.00 per year (U.S. institutions), and \$95.00 per year (foreign). There is a postage charge of \$8.00 for subscriptions shipped outside the United States. POSTMASTER: Send address changes to the *Oral and Maxillofacial Surgery Clinics*, W. B. Saunders Company, Customer Service, Orlando, FL 32887-4800.

The editor of this publication is Livia Berardi, and the production editor is Angela Martello, W. B. Saunders Company, The Curtis Center, Independence Square West, Philadelphia, PA 19106-3399.