

# Implant rehabilitation of a patient after partial mandibulectomy: A case report

T. J. Balshi\*

*Radical surgery was performed to remove the left side of the mandible in a patient diagnosed with mandibular carcinoma. For 36 years, the patient functioned with a hinged, removable partial denture anchored to the remaining natural dentition on the mandibular right side. Because of deterioration of the remaining natural dentition, the patient could no longer function with the partial denture. In lieu of reconstruction with a bone graft, the patient chose to undergo treatment with osseointegrated implants to permit insertion of a stable prosthesis with a cantilevered extension into the area of the surgical resection. The rigid attachment of the prosthesis to the remaining mandible provided function as well as soft tissue support in the area of the surgical defect. (Quintessence Int 1995;26:459-463.)*

## Introduction

Patients diagnosed with malignant lesions of the mandible are frequently treated with radical surgery, resulting in various forms of complete or partial mandibulectomy, often followed by bone-grafting procedures and implant rehabilitation.<sup>1</sup> Radiation and chemotherapy complicate and prolong the treatment process and may inhibit immediate reconstruction.<sup>2,3</sup> Reconstruction with the iliac crest or rib bone is optimal, especially when patients are not irradiated. Irradiated patients should receive treatment with hyperbaric oxygen before and after reconstructive and implant surgery.<sup>4</sup>

Historically, some patients underwent partial or complete mandibulectomies without graft reconstruction, leaving them with grossly distorted facial features. Traditional prosthodontic treatment with removable dentures did little to compensate for the loss of function and facial support. The introduction of osseointegrated implants has opened new avenues for treating cancer patients subjected to radical excision surgery.

## Case report

A 73-year-old woman had been diagnosed 36 years previously with mandibular carcinoma. At that time, radical surgery was performed to remove the left side of the mandible. The patient did not undergo bone graft reconstruction. During the following 36 years, the patient functioned with a hinged, removable partial denture supported by the mandibular right side and anchored to the remaining natural dentition. The patient was referred by a family dentist for implant prosthodontic evaluation because the patient was no longer able to function with the partial denture because the remaining natural dentition had deteriorated.

The patient had been treated for mandibular carcinoma in 1955 and cancer of the uterus in 1988, and received a right knee implant in 1987. At the time of examination, the patient's general health was good, in spite of generalized arthritis. The patient was taking the following medications: HydroDIURIL (Merck Sharp & Dohme) (50 mg), Motrin (Upjohn) (600 mg), and Benadryl (Parke-Davis) (50 mg). The patient indicated allergy to Percocet (DuPont), Darvon (Lilly), and medications containing codeine. She did not use tobacco or alcoholic beverages.

Clinical examination revealed that the only teeth remaining in the mandibular arch were the central incisors and the right lateral incisor. These teeth had

\* Private Practice, Fort Washington, Pennsylvania.

Reprint requests: Dr Thomas J. Balshi, Prosthodontics Intermedica, Institute for Facial Esthetics, 467 Pennsylvania Avenue, 201, Fort Washington, Pennsylvania 19034.

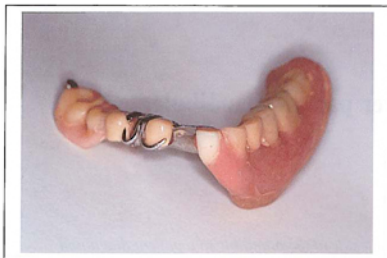

Fig 1 Removable partial denture with failed crowns attached.

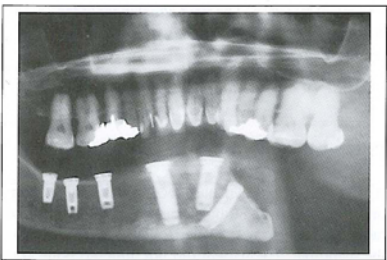


Fig 2b Position of the Brånemark implant fixtures.

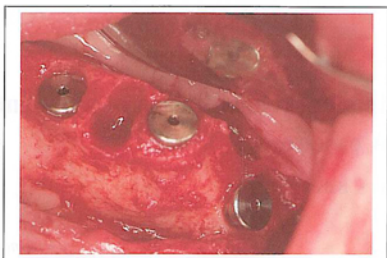


Fig 2a Stage 1 surgery. Installation of the most distal fixture on the left side of the right mandible placed at a 45-degree angle to the crest of the ridge.

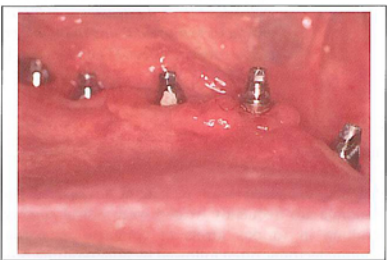


Fig 3 Abutments connected to the connected to the osseointegrated implants following stage 2 surgery.

been previously crowned and splinted to function as retainers for the removable partial denture (Fig 1). The patient functioned predominantly on the remaining natural dentition with a slightly lingualized occlusion on the maxillary dentition.

#### *Treatment plans and alternatives*

The patient was offered several forms of rehabilitation, ranging from bone graft to implants and prosthetics. The patient refused bone graft reconstruction with an iliac crest transplant because of apprehension over general anesthesia. The concept of Brånemark implants (Nobelpharma) for restoration of the mandibular dentition was offered with two prosthetic alternatives.

#### *Prosthetic alternative 1*

Four Brånemark implants placed in the right mandible would stabilize a gold clip bar, which would support an overdenture. The overdenture would be constructed with a hinged section to fill in the missing soft tissue on the left side of the mandible. That section of the denture would have limited, if any, function.

#### *Prosthetic alternative 2*

A fixed gold and acrylic resin prosthesis would be supported by six Brånemark implants positioned to take advantage of the remaining mandibular bone, permitting a rigid, cantilevered extension on the left side to provide soft tissue support for the lips and cheek as well as shock-absorbed<sup>3</sup> occlusal function.

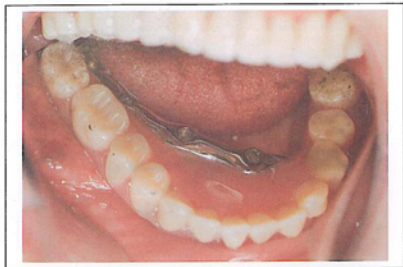


Fig 4a Final tissue-integrated prosthesis with cantilevered section replacing the left mandible.

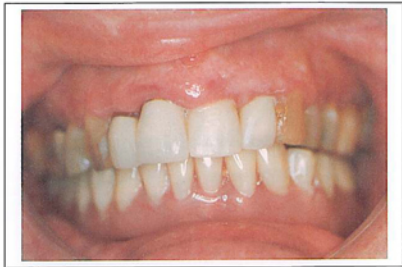

Fig 4b Centric relation established in an Angle Class I position with function on both right and left sides.

### Treatment

The patient elected to proceed with the second prosthetic alternative. At stage 1 surgery, the remaining mandibular incisors were extracted while the patient was under local anesthesia. Alveoplasty was used to level the crest of the remaining mandibular anterior ridge. A crestal incision was made and full-thickness flaps were elevated on the right side, extending onto the previously resected midline of the mandible. The mental foramen was visualized and measurements were made from the crest of the ridge to the top of the foramen to confirm the length of the posterior implants to be placed.

Six Brånemark implants were placed in the remaining mandible (Figs 2a and 2b). Three implants ( $10 \times 4$  mm,  $10 \times 3.75$  mm, and  $8.5 \times 3.75$  mm) were placed posterior to the mental foramen. The  $8.5 \times 3.75$ -mm implant was the most posterior. An  $18 \times 3.75$ -mm implant was placed in the mandible immediately anterior to the mental foramen. A  $15 \times 3.75$ -mm implant was placed at a 45-degree angle to the crest of the ridge immediately adjacent to the resected site. One additional  $15 \times 3.75$ -mm implant was placed between the 15-mm and 18-mm implants at the end of the resected mandible. All soft and hard tissues removed from the patient were submitted for histologic analysis, which revealed no remarkable findings. The patient tolerated the surgery well and experienced little discomfort or swelling following the procedure.

Stage 2 surgery was performed 3 months and 1 day following implant placement. All implants appeared to be osseointegrated. An angulated abutment was placed on the implant that was located at a 45-degree angle to

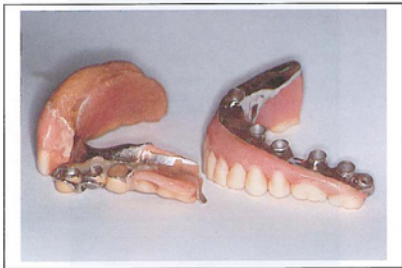

Fig 5 Postcancer surgery prosthesis (left) with hinged removable partial denture connected to conventional crowns and fixed tissue-integrated prosthesis (right) supported by surviving right half of mandible.

the crest of the ridge. With the exception of the 8.5-mm implant in the area of the mandibular right first molar, which received a standard 3-mm abutment, all other implants received titanium EsthetiCone abutments (Fig 3).

At the time of stage 2 surgery, a conversion prosthesis was constructed using the patient's interim removable complete denture.<sup>6,7</sup> The conversion prosthesis had a 15-mm cantilevered section in the region where the left side of the mandible had been removed. Three weeks following stage 2 surgery, the permanent bone-anchored prosthesis was delivered with a 21-mm cantilever into the surgical defect (Figs 4 and 5).

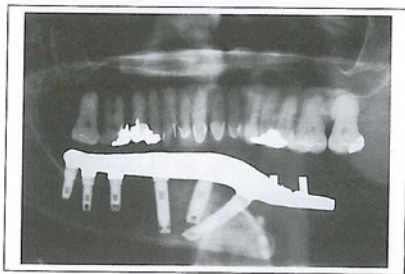


Fig 6a Lengthy cantilever supported by 45-degree angulation of the terminal implant.

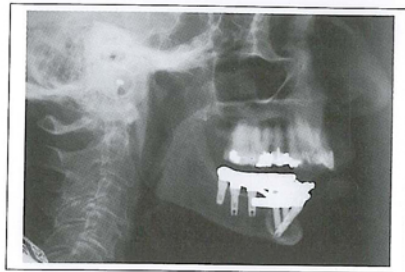


Fig 6b Completed tissue-integrated prosthesis.

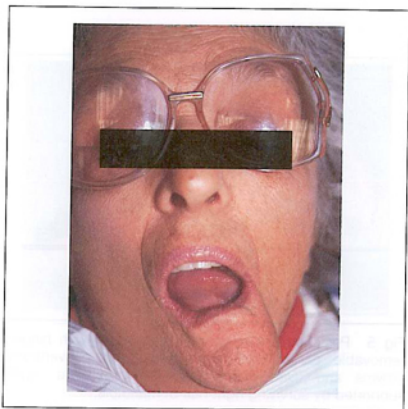

Fig 7a Preoperatively, muscles in mastication pulling the mandible to the left without the use of the tissue-integrated prosthesis.

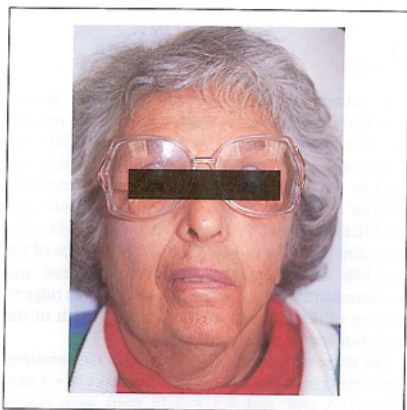

Fig 7b Resting position without a tissue-integrated prosthesis.

Radiographic analysis showed excellent bone response to the titanium implants (Figs 6a and 6b). The patient was given special instructions for oral hygiene following the delivery of the permanent prosthesis.<sup>8</sup> The cantilevered portion extending into the area of the missing left mandible provided excellent cheek and lip support (Figs 7a to 7c) as well as occlusal function.

### Discussion

Autogenous bone grafting is an ideal form of rehabilitation for patients with resected mandibles.<sup>1</sup> However, this procedure requires additional surgery with concomitant morbidity. An osseointegrated implant reconstruction is a viable alternative to bone graft reconstruction for patients reluctant to undergo the additional surgery. A fixed implant-supported pros-



Fig 7c Centric relation with tissue-integrated prosthesis fastened to the implants.

thesis, however, is limited to patients who have an adequate amount of remaining mandible in which a sufficient number of implants can be placed.

The length of the cantilever in the final prosthesis is also a point of discussion. Without mandibular bone under this cantilever, muscles of mastication have little, if any, effect on occlusal forces on that side of the mouth. Therefore, longer cantilevers can be used to provide additional soft tissue support. Additionally, the added occlusal interdigitation of cusp tips helps reposition the remaining portion of the mandible. Because occlusal loading forces to the cantilever will be reduced, loosening or fracture of the components is minimized, in spite of the exceptional length. Nonetheless, clinical experience reveals the use of six implant anchorage units to be optimal.

Implants who undergo radical cancer surgery, such as a hemimandibulectomy, can be restored to excellent function through placement of osseointegrated implants in the portion of the mandible that remains. In lieu of bone graft reconstruction, this system permits a stable, cantilevered extension into the area of the surgically removed mandible. This restoration is superior to any form of prosthetic treatment previously

available. In addition to function, this prosthesis also provides soft tissue support in the area of the surgical resection, and continued stimulation of the remaining mandibular bone appears to be physiologically beneficial for the patient. Proprioception, according to the patient, appeared to be equivalent to that of the natural dentition and superior to that of the removable prosthesis.<sup>9-11</sup>

Long-term maintenance for such patients is essentially the same as for patients with intact mandibles reconstructed with tissue-integrated prostheses.

### Acknowledgments

The author would like to thank Robert Winkelman, CDT, MDT, of Fort Washington Dental Lab, and Liz Kirk for manuscript preparation.

### References

1. Brånemark P-I, Lindstrom J, Hallen O, Briene U, Jeppson P-H, Ohmann A. Reconstruction of the defective mandible. *Scand J Plast Reconstr Surg* 1975;9:116-119.
2. Worthington P. Hemimandibulectomy. In: Worthington P, Brånemark P-I (eds). *Advanced Osseointegration Surgery: Applications in the Maxillofacial region*. Chicago: Quintessence, 1992;259-266.
3. Briene U, Brånemark P-I. Reconstruction of alveolar jaw bone. An experimental and clinical study of immediate and preformed autologous bone grafts in combination with osseointegrated implants. *Scand J Plast Reconstr Surg* 1981;14:23-48.
4. Kindwall EP. Hyperbaric oxygen's effect on radiation necrosis. *Clin Plast Surg* 1993;20:473.
5. Skalak R. Aspects of biomechanical considerations. In: Brånemark P-I, Zarb GA, Albrektsson T (eds). *Tissue Integrated Prostheses: Osseointegration in Clinical Dentistry*. Chicago: Quintessence, 1985;117-128.
6. Balshi T. The Biotes conversion prosthesis: A provisional fixed prosthesis supported by osseointegrated titanium fixtures for restoration of the edentulous jaw. *Quintessence Int* 1985;10:667-677.
7. Balshi T. The conversion prosthesis: A provisional fixed prosthesis supported by osseointegrated titanium fixtures. In: van Steenberghe D (ed). *Tissue Integration in Oral and Maxillofacial Reconstruction: Proceedings of an International Congress*. Brussels: Excerpta Medica, 1985.
8. Balshi T. Hygiene maintenance procedures for patients treated with tissue integrated prostheses. *Quintessence Int* 1986;17:95-102.
9. Mericske-Stern R. Oral tactile sensibility recorded in overdenture wearers with implants or natural roots: A comparative study. Part 2. *Int J Oral Maxillofac Implants* 1994;9:63-70.
10. Lundqvist S, Haraldson T. Occlusal perception of thickness in patients with bridges on osseointegrated oral implants. *Scand J Dent Res* 1984;92:88-92.
11. Jacobs R, van Steenberghe D. Comparative evaluation of the oral tactile function by means of teeth or implant-supported prosthesis. *Clin Oral Impl Res* 1991;2:75-80. □