

Dental Implantology Update™

The International Forum for Continuing Education

Volume 5, Number 9

September 1994

EDITOR

Morton L. Perel, DDS, MScD

EDITORIAL ADVISORS

Charles A. Babbush, DDS, MScD
Head, Section of Dental Implant
Reconstructive Surgery
Mt. Sinai Medical Center
Cleveland, OH

Charles E. English, DDS
Staff Prosthodontist
Veterans Administration Medical Center
Augusta, GA

Israel M. Finger, DDS, MSc, ME
Professor, Department of Removable
Prosthodontics
Louisiana State University School of Dentistry
New Orleans, LA

Jack A. Hahn, DDS
Associate Clinical Professor
Department of Hospital Dentistry
University of Louisville
Louisville, KY

Y.H. Ismail, DMD, PhD
Chairman, Department of Prosthodontics
University of Pittsburgh
School of Dental Medicine
Pittsburgh, PA

Kenneth W.M. Judy, DDS
Clinical Professor
Department of Prosthodontics
University of Pittsburgh
School of Dental Medicine
Pittsburgh, PA

Jaime L. Lozada, DDS
Director, Oral Implantology Center
School of Dentistry
Loma Linda University
Loma Linda, CA

Jack E. Lemons, PhD
Chairman, Department of Biomaterials
University of Alabama School of Dentistry
Birmingham, AL

Carl E. Misch, DDS, MDS
Co-Director, Oral Implantology
Pittsburgh School of Dental Medicine
Pittsburgh, PA

Leonard B. Shulman, DMD, MS
Associate Clinical Professor of Oral and
Maxillofacial Surgery
Division of Implant Dentistry
Harvard School of Dental Medicine
Boston, MA

Daniel Y. Sullivan, DDS
Clinical Professor of Periodontics
Temple University School of Dentistry
Philadelphia, PA

Improve Transition with an Implant Conversion Prosthesis for the Edentulous Arch

Within the moratorium that constitutes the interim stages of prosthetic treatment, provisional prostheses are considered to be a vital part of the osseointegration process. Provisional prostheses not only allow the patient to function in comfort, but also allow for unimpeded bone healing around root-form implants from the time of insertion through the time of total integration. An innovative form of provisionalization is the conversion prosthesis.

Thomas J. Balshi, DDS, a prosthodontist, first described the conversion prosthesis as it applies to current implant restorative procedures.¹ He is the director of Prosthodontics Intermedica at the Institute for Facial Esthetics in Fort Washington, PA. He defines the conversion prosthesis as a "provisional fixed implant prosthesis fabricated chairside, immediately following the placement of abutments at second-stage surgery."

The conversion prosthesis has advantages for both patients and the clinician, Balshi says. The advantages to the patient are:

- The conversion prosthesis reduces the amount of time for which the patient is required to function with a removable prosthesis, by providing a fixed restoration immediately following second-stage surgery (i.e., on the same day).

- The patient is more comfortable and capable orally because the conversion prosthesis provides a means of stable restoration that does not rest on the sutured mucosa, but rather acts to shield and protect it. The conversion prosthesis facilitates undisturbed soft tissue healing.

- The patient is able to preview both the look and the feel of the fixed restoration. Patients are encouraged to provide input for improvement of the final restoration.

- The number of treatment visits is reduced because impression and articulator records are combined in one clinical session, although the conversion prosthetic session is a long treatment appointment.

The conversion prosthesis has advantages for the clinician as well:

- During fabrication of the conversion prosthesis, the clinician is immediately able to visualize potential problems with abutment

This Month Inside

Alternative methods to the repositioning of the inferior alveolar neurovascular bundle69

selection and screw access holes. Thus, the clinician may elect to change abutments or make other alterations prior to making the final impression.

- The conversion prosthesis acts as an acrylic resin verification jig. This prosthesis/jig confirms the accuracy of the master cast prior to fabrication of the final prosthesis.

- It provides a stable base for an interocclusal record to be obtained, transferred to the master cast, and articulated.

- A stone cast of the conversion prosthesis can be used as a model to send to the laboratory to aid in fabrication of the final prosthesis. The clinician can note areas that need to be improved and/or replicated.

- It eliminates the need for healing abutments or healing caps, and for the denture and its soft lining. Third-stage procedures for placement of prosthetic abutments are eliminated, as are adjustment visits, which cause soft-tissue irritations.

- Use of the conversion prosthesis speeds the length of total prosthetic treatment time, and reduces the number of treatment visits.

- It acts as a record preserving the original vertical dimension of occlusion. After years of wear on the acrylic resin teeth of a final prosthesis, a conversion prosthesis can be used to mount the master cast at the original vertical dimension. New teeth can then be placed on the gold bar. This recording restores the original vertical dimension of occlusion in hybrid cases.

- The conversion prosthesis, when retained in the dentist's office, may also act as a provisional fixed restoration should any long-term laboratory procedure become necessary for the final prosthesis, either months or years after insertion.

The fabrication and use of the conversion prosthesis can be applied equally to both the maxilla and the mandible, and in the partially and completely edentulous arches, Balshi says. "It can be used regardless of the type of final prosthesis planned, whether a traditional hybrid prosthesis or a porcelain-fused-to-metal prosthesis," he says. "It can be used in any situation that can retain a fixed prosthesis, and even in some cases in which a removable implant overdenture is planned. As few as four implants have been used to support a conversion prosthesis for an edentulous arch successfully."

The conversion prosthesis has another benefit. "In situations where an implant overdenture is planned for the final prosthesis, some patients have decided to upgrade their treatment plan to a fixed-final-implant-supported restoration, after having the opportunity to function with the conversion prosthesis," he says.

"An accurately made transitional removable denture with proper esthetics, phonetics, occlusal scheme, and vertical dimension of occlusion is a prerequisite for this treatment modality," Balshi says. He advocates the following step-by-step

procedure for the conversion prosthesis:

- While the patient is being anesthetized, the laboratory attaches a wire reinforcement to the facial and buccal surfaces of the denture using clear acrylic resin. The existing established occlusion must not be altered. The denture is then relieved from the lingual aspect in the general areas of the implants. Some soft tissue rests are maintained to act as vertical stops, in order to preserve the existing vertical dimension of occlusion that had been established in the transitional removable dentures.

- After the abutment connection procedure is completed and verified radiographically, screw-retained square impression copings are modified to be used as transitional prosthetic copings. The impression copings and guidepins are modified to clear the occlusion and to provide space between the denture base and the soft tissues when the denture is placed in its proper occlusal position, after it has been modified. Maximum length of the guidepins and copings are indicated to help form proper screw access channels. (See Figure 1.)

- When clearance is confirmed, the rubber dam is then used to protect the freshly sutured mucosa. Indelible ink markers (sticks) can be used to mark the top of the guidepins so the markings can be transferred to the rubber dam. Corresponding holes can be punched into the rubber dam, which

Dental Implantology Update™ (ISSN 1062-0346) is published monthly by American Health Consultants Inc., a unit of Medical Economics Data, 3525 Piedmont Road, N.E., Six Piedmont Center, Suite 400, Atlanta, GA 30305; Telephone: (800) 688-2421 or (404) 262-7436. Second-class postage paid at Atlanta, GA 30374. POSTMASTER: Send address changes to **Dental Implantology Update™**, P.O. Box 740059, Atlanta, GA 30374.

Subscription rates: U.S.A., \$259 per year. Students, \$98 per year. U.S. possessions and Canada, add \$10 per year. Elsewhere, add \$20 per year. To receive student/resident rate, order must be accompanied by name of affiliated institution, date of term, and the signature of program/residency coordinator on institution letterhead. Orders will be billed at the regular rate until proof of student status is received. Back issues, when available, \$23 each. American Health Consultants Inc., in affiliation with Boston University Goldman School of Graduate Dentistry, offers continuing dental education to subscribers. Each issue of **Dental Implantology Update™** qualifies for one continuing education unit. Add \$96 per year.

Opinions expressed are not necessarily those of this publication. Mention of products or services does not constitute endorsement. Clinical, legal, tax and other comments are offered for general guidance only; professional counsel should be sought for specific situations.

Copyright © 1994 by American Health Consultants Inc. President: Robert Williford. Executive Editor: Brenda Mooney. Managing Editor: Lisa Gandy Wargo. Production Editor: Trent Winter.

Reproduction, distribution or translation without express written permission is strictly prohibited.

Dental Implantology Update™ is a trademark of American Health Consultants Inc. The trademark **Dental Implantology Update™** is used herein under license. All rights reserved.

is then trimmed to the appropriate size. The rubber dam should cover the junction between the abutment and modified copings, to ensure that the acrylic resin to be used will not lock into any undercuts of the abutments. (See Figure 2.)

- Now that adequate clearance exists, and the soft tissue is protected, a thin mix of autopolymerizing acrylic resin is placed around the copings and the denture by means of a modified *Monoject* syringe (Monoject, a division of Sherwood Medical, St. Louis, MO). Before the

acrylic resin sets, the patient is asked to bring his or her teeth together and is guided into the previously established centric occlusion position. The rubber dam can be raised and manipulated to help form a smooth underside to the prosthesis.

- Care must be taken to expose all screw heads prior to the final setting of the acrylic resin. The patient is again guided into occlusion while the acrylic resin sets. After the material hardens, but prior to detectable heat from the exothermic reaction of

the setting acrylic resin, guidepins are removed. The modified copings will then disengage the abutments, and the prosthesis can be removed from the mouth and placed into a pressure pot. (See Figure 3.)

Brass analogs and long guidepins are placed in order to add acrylic resin to the conversion prosthesis in the laboratory. (See Figure 4.) The brass analogs protect the shoulder of the copings from alteration and long guidepins enable the formation of tall access screw holes. (See Figures 5 and 6.) After the addition

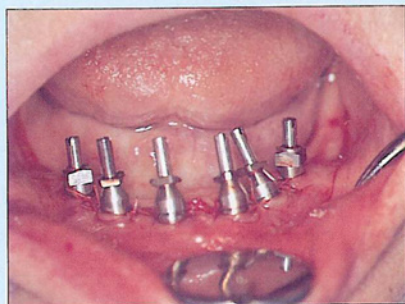


Figure 1: Screw-retained stainless steel impression copings (both standard and conical) and guidepins modified to clear the occlusion are secured into place.

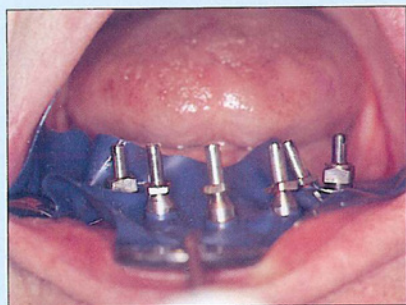


Figure 2: A rubber dam is placed to cover the junction between the copings and the abutments, to protect the freshly sutured mucosa.

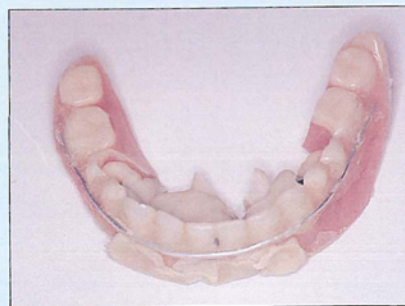

Figure 3: Facial view of the modified denture, which has picked up the copings intraorally using autopolymerizing resin. Note the wire reinforcement secured to the facial and buccal surfaces of the denture with clear acrylic resin.

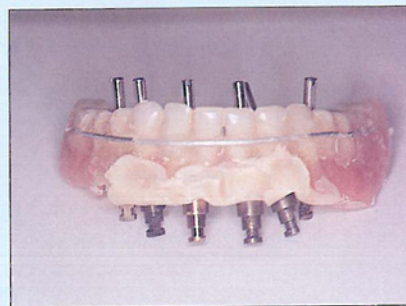


Figure 4: Long guidepins and brass analogs are attached prior to addition of acrylic resin. The brass analogs will protect the surface of the copings from alteration.

of acrylic resin is completed, it is again placed in a pressure pot to facilitate setting of the material.

- Flanges are removed and the conversion prosthesis is initially shaped, smoothed, and polished. The conversion prosthesis can then be placed on the master cast to act as a verification jig, thus verifying the accuracy of the master cast. The prosthesis is then replaced intraorally, and the occlusion is adjusted. An interocclusal record is taken with the conversion prosthesis and is transferred to the master cast. The

mounting of the master cast is thus facilitated in order to achieve a proper relation to the opposing arch on the articulator. Cantilevered sections are reduced, and the conversion prosthesis is then buffed smooth and highly polished for delivery. (See Figures 7 and 8.)

Clinicians should take these precautions to avoid impeding soft tissue healing and to accommodate hard tissue integration, Balshi stipulates:

- The rubber dam must be properly placed to protect the sutured

mucosa from acrylic resin, and to prevent the acrylic resin from locking into undercuts between abutments when it sets.

- Screw access holes must be cleared prior to acrylic resin setting. Otherwise, a high-speed handpiece may be necessary to expose the screw to enable its removal. If too much time is taken, the exothermic heat from the setting action of the acrylic resin may cause a soft- or hard- tissue complication.

- Cantilevered lengths must be reduced to avoid fractures in the

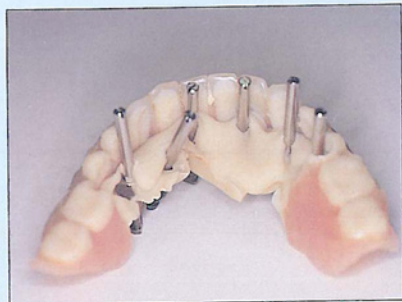

Figure 5: Lingual view of modified denture with retained copings that have been picked up.

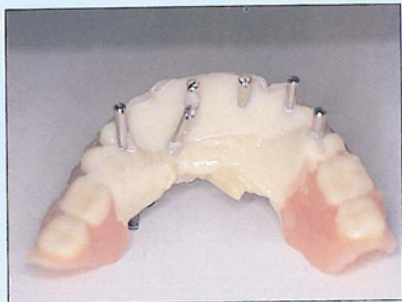


Figure 6: Long guidepins enable addition of autopolymerizing acrylic resin to fill in voids while forming long screw access channels.

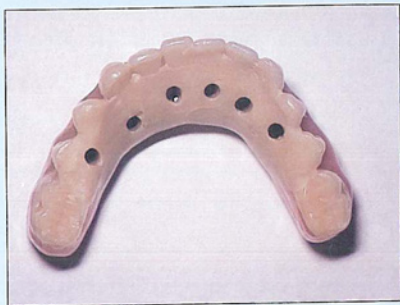

Figure 7: An occlusal view of the finished and polished conversion prosthesis with well-placed and -defined occlusal access holes.

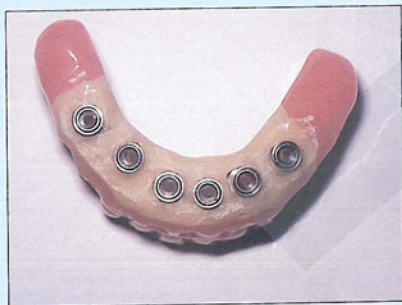

Figure 8: An apical (underside) view of the same conversion prosthesis, which is implant-supported without soft tissue interference. Note the limited length of the cantilevers bilaterally.

acrylic resin. Utilizing maximum gingival-occlusal height is recommended to provide adequate strength for the prosthesis.

Patients should use chlorhexidine gluconate rinses and light mechanical oral hygiene measures during the soft tissue healing phase after the conversion prosthesis has been placed. After soft tissue healing has occurred, normal oral hygiene procedures are acceptable. Patients are instructed in the use of a soft toothbrush, floss, nylon-coated proximal brushes, and water irrigation devices. Each patient is given an instructional videotape, titled "Oral Hygiene for Implant

Patients," to take home to review the plaque control procedures recommended for implant patients.

[Editor's note: "Oral Hygiene for Implant Patients" was produced by Barbara Lord, RDH. The patient education videotape is available for \$45 from the Institute for Facial Esthetics in Fort Washington, PA. Telephone: (215) 646-6334 or (215) 643-5881.]

Reference

1. Balshi TJ. Biotes conversion prosthesis: A provisional fixed prosthesis supported by osseointegrated titanium fixtures for restoration of

the edentulous jaw. *Quintessence International* 1985; 10:667-676.

Related Readings

1. Balshi TJ. "The conversion prosthesis: A provisional fixed prosthesis supported by osseointegrated titanium fixtures." In: Van Steenberghe D, ed. *Tissue Integration in Oral & Maxillofacial Reconstruction, Proceedings of an International Congress May 1985*. The Netherlands: Elsevier Science Publishers B.V.; 1986.
2. Balshi TJ. Osseointegration for the periodontally compromised patient. *Int J Pros* 1988; 1:51-58. ▼

Alternative Methods for Repositioning of the Inferior Alveolar Neurovascular Bundle

The current dominance of root-form implants has prompted surgical innovators to use cylindrical forms as effectively and as often as possible. Proven successful surgical techniques now range from the use of barrier membranes, to LeFort I interpositional bone grafting. Within this range lie other accommodative surgeries, the most prominent of which are maxillary sinus modifications and repositioning of the mandibular inferior nerve.

DIU asked Jon R. Wagner, DDS, to elaborate upon a multi-modal approach to implants in the region of the posterior mandible. Wagner is a diplomate of the American Board of Oral Implantology, has a private practice in Pensacola, FL, and is an assistant editor of the *Journal of Oral Implantology*.

Before describing a multi-modal approach, Wagner first recounts his criteria for selecting procedures:

- **Invasiveness** — "Generally speaking, surgical procedures should not be any more invasive than necessary to accomplish the goal; in this case, replacing some posterior teeth. I consider any

endosseous implant procedure more invasive than a subperiosteal implant," Wagner says.

"With subperiosteal surgery, everything is in full view. All endosseous implant surgery involves a certain amount of 'blind' procedures performed in close proximity to vital structures," he says. "The risks include nerve damage, cortical plate perforation or fracture, thermal damage, or hemorrhage. Inferior alveolar nerve lateralization, as advocated to replace a couple of missing teeth in the posterior region of the mandible, is high on my list of invasive procedures."

- **Paresthesia or dysesthesia** — "Concern for the risk of inferior alveolar nerve damage should be the single most important factor in diagnosis and treatment planning whenever restoring the posterior mandible," Wagner says. "Therefore, it follows that the treatment that enables the clinician to accomplish the task of predictably replacing missing teeth with implant-supported prostheses, with the least amount of risk, is the treatment of choice."

- **CT scans** — "These can be useful in a limited number of situations, in an effort to avoid the inferior alveolar nerve by placing root-form implants lingual to the canal," Wagner says. He notes, however, that the cost of CT scans can be prohibitive.

- **Costliness** — "In reality, fees are a major factor. One blade or plate-form implant with one or two posts, or a single ramus blade implant, can support a prosthesis that would require two or three root-form implants. The use of these alternative implant systems negates the need for any extra expense for the prosthetic abutment posts, which are not necessarily included with root-form systems. Such savings may be passed on to the patient in the form of reduced surgical and/or prosthetic fees," Wagner says.

Wagner describes four methods for implant restoration of the posterior mandible:

- **Root-form implants.** Wagner says he has used osseointegrated root-form implants for about twelve years in situations