

# PROSTHODONTIC

## —Insights—

A Digest of Recent Trends, Techniques and Clinical

Concepts of Dental and Facial Esthetics



*Thomas J. Balshi,  
D.D.S., F.A.C.P.*

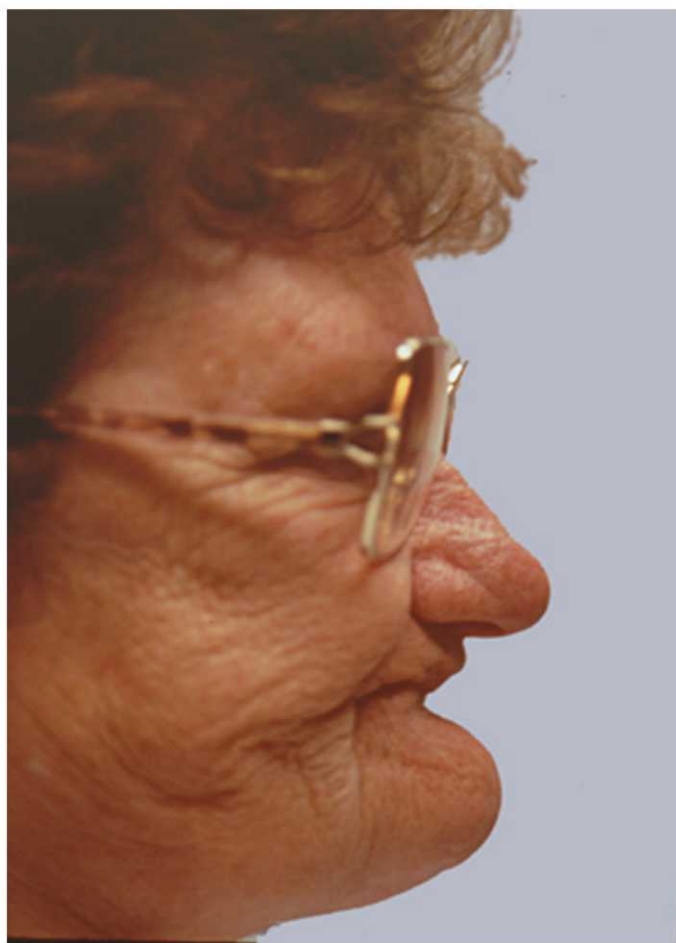### Rehabilitation of a Severely Atrophic Mandible

Rehabilitation of the lower third of the face for patients with severe mandibular atrophy has been unsuccessfully attempted in the past using hydroxyapatite ridge augmentations, Visor-sandwich osteotomies, and onlay bone grafts stabilized with tita-

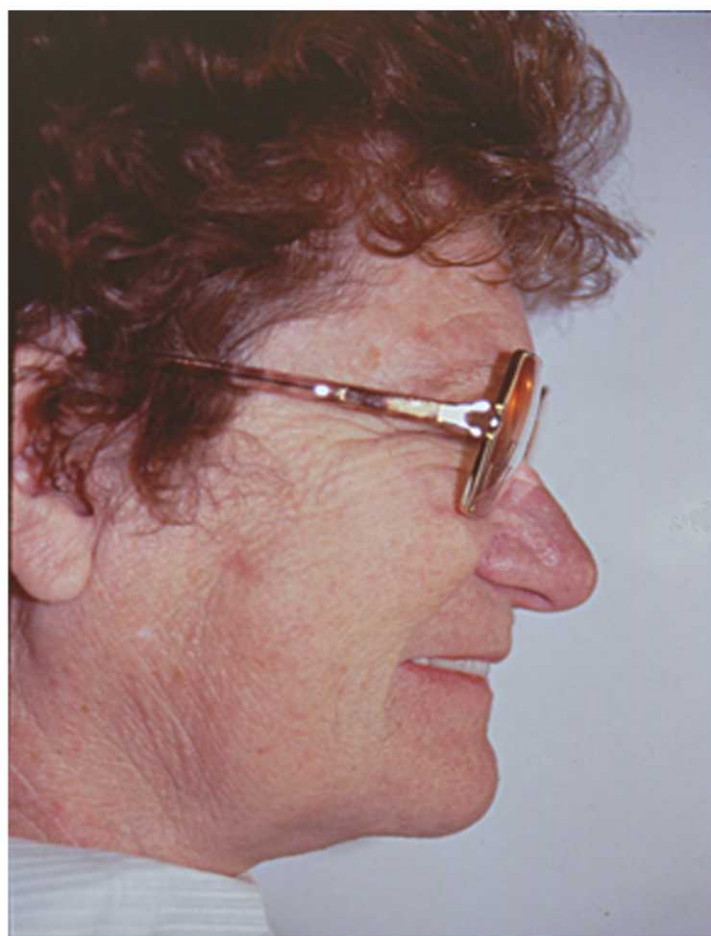nium screw implants, with only modest success.

Preservation of the existing mandible with its generally dense cortical composition in the resorbed state appears to be a prerequisite to successful use of osseointegrated implants. Five to 7 mm of bone height is required if threaded Branemark System implants are used without ridge augmentation, however

*(Continued on Page 2.)*



*Figure 1a:  
Preoperative profile illustrates oral debilitation and collapse of the lower third of the face.*



*Figure 1b:  
Postoperative profile following mandibular inferior border graft and Branemark implant reconstruction.*



## Rehabilitation of a Severely Atrophic Mandible . . .

(Continued from Page 1.)

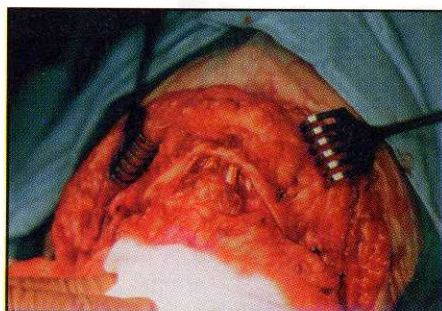


Figure 2b:  
Exposure of the inferior border of the mandible.

pathologic fracture remains a risk factor.

When bone falls below 5 mm, augmentation of the ridge using an inferior border graft, as advocated by Magid, may be considered. This procedure requires substantial autogenous bone, usually harvested from the iliac crest, in combination with a freeze dried cadaver mandible. An extended healing time of 6 to 8 months is neces-

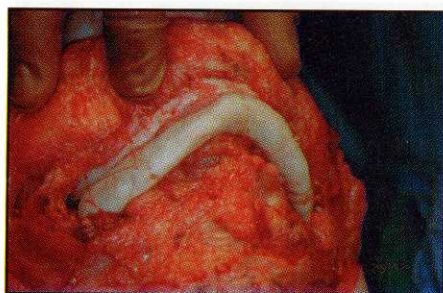


Figure 3a:  
Cadaver graft filled with autogenous bone ligated to the mandibular inferior border.

sary for the graft to ossify prior to the placement of endosseous implants, which should completely penetrate the original mandible and engage the cortex of the inferior border of the grafted mandible.

The treatment plan for a 64 year old female patient who presented with a severely atrophic mandible with less than 4 mm of bone height, prescribed a mandibular rehabilitation with several treatment phases beginning with a mandibular inferior border graft and ending with a fixed implant supported prosthesis (Figure 1a, b). A multistage treatment program for this form of oral facial rehabilitation is described.

An initial neck incision extended

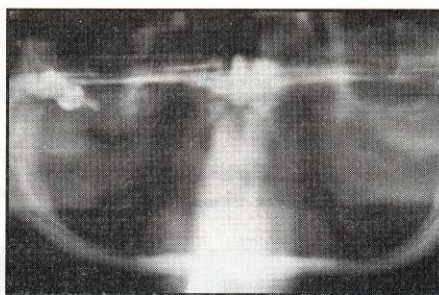


Figure 2a:  
Panradiograph illustrates the preoperative mandible with less than 4 mm height.

from the angle of the mandible across the cricoid region to the contralateral mandible angle. Dissection of the flap exposed the entire inferior border of the mandible (Figure 2 a,b,c). A cadaver mandible was reconstituted prior to the surgical procedure and hollowed out to create a crib to contain the contents of the bone graft. Autogenous marrow and bone was obtained from the anterior iliac crest. The bone was processed through a bone mill. Freeze dried cortical bone chips were added to extend the volume of autogenous bone. A homogenous mixture of marrow

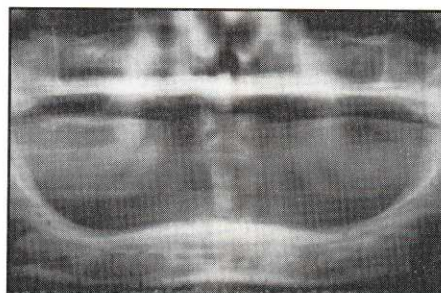


Figure 3b:  
Panradiograph following the placement of the inferior border graft.

(60%) and cancellous (40%) bone was compressed and placed in the cadaver mandible.

Six transcortical holes were drilled through the inferior border of the mandible with a 1 mm wire burr to allow the passage of sutures used to stabilize the crib after its placement. The cadaver crib was scored on its inferior surface creating a groove to stabilize the sutures, preventing movement of the crib. Voids between the recipient mandible and the cadaver graft were filled with bone grafting material prior to closure (Figure 3a,b,c).

Seven months after the inferior border graft was placed, the patient report-

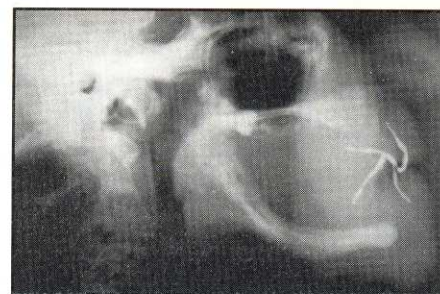


Figure 2c:  
Preoperative lateral cephalometric film.

ed chronic pain in the right mandible and dysesthesia of the third division of the trigeminal nerve due to severe atrophy of the mandible with exposure of the mental nerve on the crest of the ridge. The inferior alveolar nerve was repositioned in a carefully prepared channel cut into the buccal cortex of the mandible, lowering the neurovascular bundle inferiorly. (Figure 4.)

Following this procedure, six 18 mm x 3.75 mm Branemark titanium implants were placed in the anterior mandible between the mental foramen (Figure 5a, b). Three weeks following

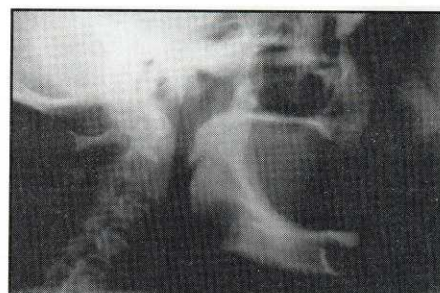

Figure 3c:  
Lateral cephalometric film following placement of the inferior border graft.

implant placement, a temporary removable complete denture was modified and coated with a soft lining.

Four months following implant

(Continued on Page 3.)

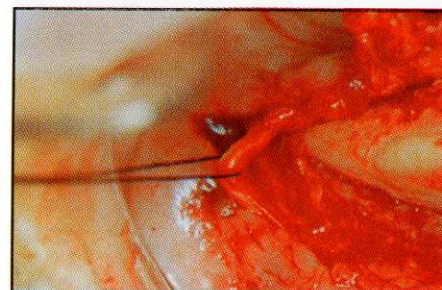


Figure 4:  
The neurovascular bundle is repositioned inferiorly.



## Rehabilitation of a Severely Atrophic Mandible . . .

(Continued from Page 2.)

placement, the mandibular implants were uncovered and all appeared to be osseointegrated. The Conversion Prosthesis (a temporary fixed prosthesis) was constructed immediately following second stage surgery. The Conversion Prosthesis restored oral function and provided excellent support for the muscles and tissues of the lower third of the face.

The final prosthesis used the Procera titanium framework protocol with heat processed resin denture teeth restoring the mandibular arch (Figure 6a, b).

Although initially stable and clinically successful, long term follow up of patients treated with inferior border grafts and a fixed prosthesis anchored to osseointegrated Branemark System implants is necessary. For the short term, however, it appears that complete resolution of collapse of the lower third of the face (Figure 7a, b) can be accomplished using an inferior border graft in a severely atrophic mandible followed by a fixed reconstruction anchored to osseointegrated implants.

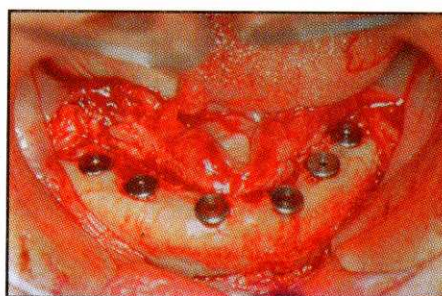


Figure 5a:  
Six 18 mm long Branemark implants placed through the original mandible into the grafted bone.

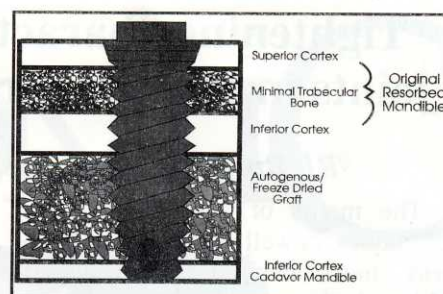


Figure 5b:  
The "anatomy" of osseointegrated implants in the severely resorbed mandible augmented with an inferior border graft.

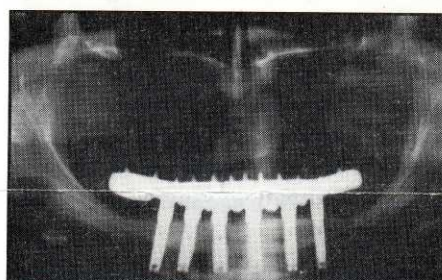


Figure 6a:  
Panoradiograph with Procera titanium framework in place.

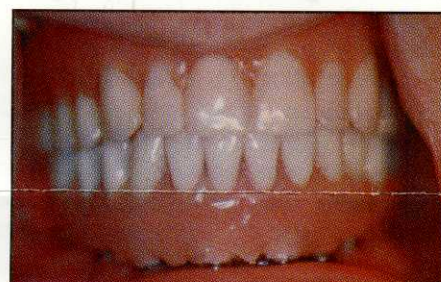


Figure 6b:  
Anterior clinical view of the completed Procera/Branemark implant supported prosthesis.

## Augmentation of the rat mandible using guided tissue regeneration

**Kostopoulos & Karring**

Lack of adequate bone volume frequently limits the possibility of achieving the placement of dental implants as replacement for teeth. The aim of this study was to examine whether it is possible to augment the mandible of the rat with a bioresorbable membrane adapted to create a secluded space for ingrowth of bone tissue.

The experiment was carried out in 18 rats. The mandibular ramus was exposed at both sides. A standardized titanium microimplant was then inserted in the naturally existing curvature at the inferior border of the mandible. One side was covered with a polyhydroxybutyrate bioresorbable membrane, and the contralateral side, serving as control, received no membrane. The membranes were placed in such a way as to create a space in the curvature between the membrane and the inferior border of the mandible.

In the control specimens, the

amount of bone formation was minimal and the naturally existing curvature at the inferior border of the mandible persisted.

The test specimens exhibited considerable bone formation during the 6 month healing period. About 50% of the height of the head of the implants was covered with bone and the naturally existing curvature at the inferior border of the mandible had disappeared or had become reduced in depth. The new bone, formed within the space created by the membrane, appeared mature and resembled the lamellar bone of the adjacent parts of the jaw.

This study differs from previous ones in that the present study took place from a noninjured bone surface into a space where bone had not previously been present. This means that the original anatomical configuration of the mandible had been altered. Although this study does not completely rule out the origin of the cells that have produced the bone underneath the membrane, the results open great perspectives in plastic, reconstructive and maxillofacial surgery. It remains to be shown that this altered configuration of the jaw can be maintained on a long term basis.

*Clin Oral Impl Res 1994;5: 75-82*

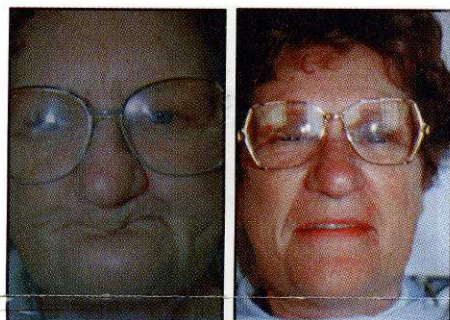

Figure 7a:  
Preoperative frontal view showing extreme collapse of the lower third of the face.



Figure 7b:  
Postoperative front view demonstrates excellent lip and muscle support for the lower third of the face following Branemark implant reconstruction.

Acknowledgements: Mitchell J. Magid, DMD; Bob Winkelman, C.D.T., M.D.T., Fort Washington Dental Lab.



# Implants in Irradiated Tissue

*P.E. Larsen*

A rationale for management of patients with irradiation who would benefit from implant placement can be summarized as follows:

1. In the absence of controlled clinical trials, previous irradiation therapy to the jaws should continue to be a relative contraindication to routine implant placement.
2. If the benefit from placement outweighs the risks, implant reconstruction may be considered using a protocol that includes:
  - a) Informed consent regarding the higher risk of complication
  - b) Delivery of perioperative hyperbaric oxygen
  - c) Minimum implant integration time of 6 months
  - d) Limited soft tissue reflection
  - e) Fabrication of an over engineered, entirely implant borne prosthesis, designed to maximize oral hygiene and soft tissue health.

AAOMS 1994

# Dental Implants in the Growing Jaw

*R.G. Triplett*

Although dental implants are viewed to be predictable with expectation of long term success in adults, little work has been performed in children. There are vertical and horizontal changes in the growing jaw which could significantly affect implant position. The variation in growth from individual to individual is great; and accurate predictions at an early age of the amount and direction of growth in a particular individual is not currently possible.

Dental implants do not move with alveolar growth, therefore there is a real danger of the implants becoming embedded and displaced as the jaw grows. In those individuals in which the alveolar growth potential is minimal, i.e. anodontia, it may be possible to place implants early. Additionally, in those cases of arrested growth of an arch or segment of an arch, reconstructive procedures may also be undertaken early. Implants placed in the late puberty or early adulthood have the best chance of long-term usefulness.

AAOS 1994

## Guided tissue regeneration in jawbone defects prior to implant placement

*Lang et al*

The purpose of this study was to evaluate the volume of regenerated bone in comparison with the volume of the space created for regeneration by the placement of a barrier membrane. In addition, the duration of the healing period necessary for complete bone regeneration was addressed.

Nineteen patients presented with a total of 19 defects which included 11 maxillary concavities ranging from 18 mm<sup>3</sup> to 352 mm<sup>3</sup> and 8 mandibular concavities between 58 mm<sup>3</sup> and 316 mm<sup>3</sup> in volume. Group A contained 13 patients in which the membrane removal was performed according to the planned schedule of 6-8 months after regenerative surgery. The defect sites yielded 90-100% bone regeneration compared with the maximal volume of the

space defined by the membrane placement. It was also found that the volume of regenerated bone in relation to the maximal volume of the space defined by the membrane barrier primarily depended on the duration of undisturbed healing. The size of the defect appeared to influence the percentage of bone regeneration obtained. Since all defects in the individuals of Group A regenerated to 90-100%, it may be postulated that an undisturbed healing period of at least 6 months should be observed to assure optimal jaw bone regeneration in humans.

In Group B, in which the membranes had to be removed after 3-5 months because of developing infection, the percentage of regenerated bone ranged from 0-62% out of the possible volume for regeneration.

❖

**Educational Opportunities  
Sponsored By The Institute  
For Facial Esthetics –  
Pennsylvania's First Official  
Brånemark Training Center**

**Surgical & Prosthodontic  
Certification Courses In  
The Brånemark System®**

ARE ONGOING

**For Information:** Tel: 215-643-5881  
Fax: 215-643-1149

Despite the exposure of the membrane material to the oral cavity, 42-62% of the defects were filled with mineralized bone in cases with exposure and premature removal of the membranes. Bone resorption occurred in a patient with a developing abscess at the membrane site. This indicated that early exposure of the membrane material to the oral environment during the healing period does not per se preclude the possibility for regeneration to a certain degree but rather represents a risk factor for infection.

Infection of the membrane sites in cases of material exposure represented the primary risk for failure.

*Clin Oral Impl Res 1994;5:92-97*



# Guided Bone regeneration in mandibular defects in rats using a bioresorbable polymer

*Kostopoulos & Karring*

Guided tissue regeneration (GTR) has been used successfully in the treatment of surgically created jaw bone defects in rats and monkeys by isolating the defects from the surrounding soft tissues with Teflon membranes. This resulted in complete bone fill of the defects 3 months following surgery. The aim of this study was to evaluate whether bone regeneration can be achieved predictably in jaw bone defects with a bioresorbable barrier, applied according to the principles of GTR.

The mandibular ramus in 31 rats was exposed in both sides and a 2 x 3 mm defect was produced. The defect on one side was covered with a polyhydroxybutyrate resorbable membrane (test side), and no membrane was placed over the defect on the other side of the jaw (control side). At the early stages of healing, the test and control sides exhibited similar

amounts of bone formation. However, after 1 month, the formation of new bone in the control defects ceased, where in the experimental defects, bone regrowth continued until the defects were completely or almost completely filled with bone at 90 days after treatment.

The polyhydroxybutyrate acid membranes elicited very little tissue reaction, indicating that this material is biocompatible. No sign of degradation of the membrane was observed before 5 months of implantation, as indicated by the presence of macrophages along the external surface of the membrane. Whether a bioresorbable membrane with a shorter degradation time could be used without interfering with bone healing needs to be demonstrated.

A major problem with the membranes used was their rigidity, making the adaptation of the membranes

over the defects difficult; and a microspace was often present between the membrane and the bone surrounding the defects at the inferior border of the ramus. Also, the type of membrane used was brittle and sometimes microruptures occurred during healing. These shortcomings of the membrane are most likely responsible for the variation of bone regeneration observed in the test defects.

Problems regarding the properties of the membranes were encountered during the surgical procedures and during healing. This implies that guided bone regeneration is sensitive with respect to the type of membrane used. However, the material was biocompatible and did not interfere with healing. Therefore, it is possible that membranes of polyhydroxybutyrate, with other structural and surface properties, can be developed for clinical application in the treatment of bony defects in the craniomaxillofacial region.

*Clin Oral Impl Res 1994;5:66-74*

## On long-term maintenance of osseointegrated response

*T. Albrektsson*

There is a need for adequate clinical research in assuring the long term success of dental implants. Every oral implant system should be backed up by controlled reporting of the clinical outcome. Materials, research and invitro studies are only initial studies in the development of a new clinical product. Invivo investigations and controlled clinical applications are the true test of a dental implant system. A minimum of 5 years clinical investigations should be required before introducing a new biomaterial for widespread clinical use.

There are potential hazards for patients being treated with poorly investigated oral implant systems. Look-a-like implants do not necessarily show similar long term clinical results. Commercially pure titanium and titanium alloys give rise to different tissue reactions. Animal studies

have shown a stronger bone response to commercially pure titanium, such as that found in the Nobelpharma implant, than it does to the titanium alloy, titanium 6 aluminum 4 Vanadium alloy, used in such implants such as 3I and CoreVent.

Design differences could also cause different outcomes in clinical success. It has been reported by many researches that cylindrical implants, such as those used in IMZ and Integral implant systems were found to exhibit a significantly greater amount of bone loss or bone saucerization with no tendency to a steady state. Based on the alarming results of previous implant systems, it is only responsible to await the results of long term adequate clinical studies prior to inserting HA coated implants into the jaw of the patient. Furthermore, the patient must be made aware of risks involved and other treatment options available.

Albrektsson states that osseointegration of an implant is not the same as clinical success, as secondary loss of osseointegration may be a frequent problem with respect to certain biomaterials, as well as implant designs.

The author suggests a new way of

reporting the outcome of oral implants in a 4 field table including success, survival, unaccounted for, and failure categories. Success applies to those implants that meet the specific success criteria. Survival are those implants that are still in the jaw of the patient but where criteria for success or failure are not met. Unaccounted for, are implants in patients who dropped out of the study for one reason or the other, including patient death. Failures are those implants which have been removed from the jaw, or where absolute failure criteria such as implant mobility or therapy resistant pain apply.

At a recent consensus meeting with 70 scientifically leading European periodontists, the four field table analysis, coupled with controls at fixed time intervals, was considered as the evaluation method of choice. Commercially pure titanium was regarded as the only material where osseointegration had been experimentally verified where there is positive 5 year documentation. The workshop concluded that the only design that has demonstrated acceptable 5 year figures in the literature is



# Tightening characteristics for screwed joints in osseointegrated dental implants

*RL Burguete, RB Johns, T King, & EA Patterson*

The merits of various tightening techniques, as well as the level of tightness most desired is discussed. Although the examples used refer to the Branemark System, the principles are applicable to other screw-retained implant systems.

Loosening occurs in two stages: external forces applied to the screwed joint, such as chewing, lead to the effective erosion of the preload in the screwed joint; and external forces and vibrations that cause the mating threads to turn or "back off". To avoid loosening of the screw, the long-held belief has been to apply as high a torque as possible.

The aim in tightening a screwed joint is to achieve the optimum preload that will maximize the fatigue life while offering a reasonable degree of protection against loosening. The applied torque required to achieve

optimum preload varies from one screw to another. It is common practice to use the term "optimum torque"; however, in most cases it is the design torque that devices achieve.

The importance of tightening is the application of the optimum preload, but the operation of tightening involves the application of torque. There are three classes of tightening methods: (1) torque control, (2) angle control, and (3) torque/angle control. The torque control methods are the most widely used class of tightening methods in both general engineering and dentistry.

Studies revealed a wide variation in the ability of clinicians to perceive torque with hand held screwdrivers. Tests conducted on an electronic torque controller indicate that the electronic torque controller typically achieves a torque equivalent to

between 65% and 80% of the set torque at the low speed setting. The tests did not indicate the accuracy with which the optimum preload was achieved; however an estimate of the variation in preload under typical conditions was obtained showing the relationship between preload and applied torque, for both a poorly and a well lubricated joint, with no axial force applied through the torque device.

When the screw hole in the prosthesis does not align with that in the abutment, the geometric factors will be changed as a result of the small-scale deformation of the fixture screw. Both angle control and torque/angle control methods can be used to identify this type of misfit, because the angle of rotation from the point at which significant torque is applied will be much greater than that in the usual situation. This is because a greater axial deflection of the clamped parts is necessary to bring them into contact. Therefore there are significant potential advantages in the use of torque/angle control to tighten screws in dental implants, both in terms of improved quality in the tightening operation and sensing misfits in the system. The development of an appropriate torque device based on torque/angle control methods is needed.

*J Prosthet Dent 1994;71:592-9*

## On long-term maintenance . . .

*(Continued from page 5.)*

the screw type oral implant. It was also agreed that the average marginal bone loss should be less than 1.5 mm during the first year after insertion of the prosthesis; and less than .2 mm annually thereafter. Coats of various types of calcium phosphates were only regarded as having demonstrated interesting experimental data.

Albrektsson concludes that "For oral implants to become a truly acceptable treatment modality in the future it is essential the profession demand proper documentation of at least 5 years from every implant company and that such documentation be published in refereed journals before marketing the various devices".

*Australian Prosthodontic Journal 1993;7 (Suppl)*

## Oral Hygiene Video For The Implant Patients

**Educate** your patients with a detailed film of home care techniques for implant patients.

**Reinforce** the hygiene instructions you have already shown your patients.

**Optimize** the time that your hygienist spends with home care instructions.

**Legal** documentation is verified by patient viewing homecare video.

**1 Video \$35.00**

**5 Videos \$150.00**

Return \_\_\_\_\_

Address \_\_\_\_\_

Please mail check and form to:

Institute for Facial Esthetics

467 Pennsylvania Avenue, Fort Washington, PA 19034

Tel: 215-643-5881 • Fax: 215-643-1149

## PROSTHODONTIC — Insights —

A Digest of Recent Trends, Techniques and Clinical Concepts of Dental and Facial Esthetics

is published by Prosthodontics Intermedica and distributed without charge to qualified individuals. Please request a subscription on your organization's letterhead.



*Fixed, Removable, Maxillofacial  
and Implant Prosthodontics*

Prosthodontics Intermedica  
467 Pennsylvania Avenue, Suite 201  
Fort Washington, PA 19034 U.S.A.  
Tel: 215-646-6334  
Fax: 215-643-1149