

**MAINTENANCE PROCEDURES
FOR PATIENTS AFTER
COMPLETE FIXED
PROSTHODONTICS**

THOMAS J. BALSHI, D.D.S.
and

ERNEST B. MINGLEDORFF, D.D.S.

Temple University, School of Dentistry, Phila-
delphia, Pa.

Reprinted from

**THE JOURNAL OF PROSTHETIC
DENTISTRY**
St. Louis

Vol. 37, No. 4, pp. 420-431, April, 1977

(Copyright © 1977 by The C. V. Mosby Company)
(Printed in the U. S. A.)

Maintenance procedures for patients after complete fixed prosthodontics

Thomas J. Balshi, D.D.S.,* and Ernest B. Minglehoff, D.D.S.**
Temple University, School of Dentistry, Philadelphia, Pa.

Public awareness of preventive dentistry is increasing as evidenced by many patients requesting information on how to stop dental decay and prevent receding gums. Preventive programs and patient education are necessary in all phases of dentistry, including fixed partial prosthodontics.

Too often, patients assume that the "permanent" crown or fixed partial denture is just that—permanent. They assume nothing more is required to maintain this condition. It is the responsibility of dentists to inform their patients that further care is necessary to maintain the restoration and the remaining teeth.

INFORMATION ON PLAQUE FOR PATIENTS

Dental disease may be divided into two basic categories: (1) caries, affecting the hard tissues, and (2) periodontal disease, attacking the investing tissues. Both diseases are closely related. Each entity has bacterial plaque as an active agent in the destructive process. Patients must understand plaque, its composition, and how it relates to dental disease. They should be informed that certain bacteria present in the plaque consume fermentable carbohydrates from the diet and convert these into a sticky substance and an acid. The acid component etches the enamel of the teeth as acid etches glass. This is the initiation of dental decay or caries. The sticky substance produced by the bacteria aids in holding the bacteria to the tooth. This mass of substance held closely to the tooth in the region of the gums may enlarge and become hard.

Fitch and Moxley¹ advocate giving the patient as much information as possible without overloading them. They suggest using terms which are meaningful to the patient instead of "dull, scientific terms." An example used is: "The tartar buildup under your gums is acting like a splinter. The body tries to wall it off, bacteria and blood congest, tissues swell, get sore and die." Patients understand this much better

*Assistant Professor, Fixed Partial Prosthodontics.

**Professor and Chairman, Fixed Partial Prosthodontics.

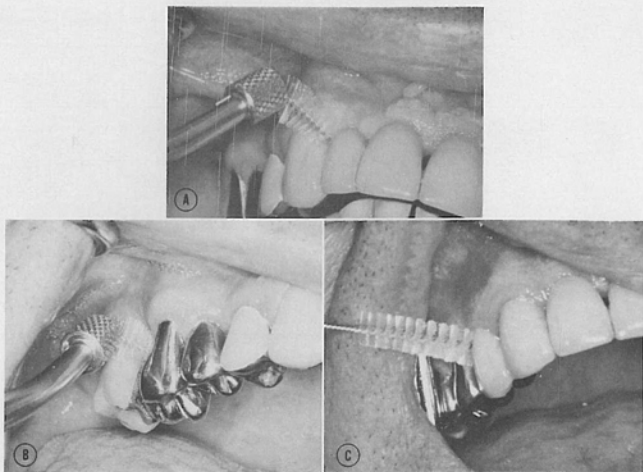


Fig. 1. (A) A "proxy" brush used to clean between pontic and abutment tooth. (B) The spiral plaque brush is well suited for cleansing teeth restored after root amputation. (C) Small interdental brush removes plaque deposits from proximal surfaces of a restored dentition.

than, "You have necrotizing gingivitis with periodontal involvement due to subgingival calculus deposits."

When patients understand what plaque is and how it affects the oral cavity, they are attuned to suggestions for plaque control, especially those who have committed themselves to extensive restorative procedures.

The responsibility for complete restorative therapy does not end with the cementation of a fixed prosthesis. The patient must know how to maintain his mouth including the newly placed prosthesis.

PREVENTION MODALITIES

Numerous techniques have been advocated for the removal of plaque. Two or more methods may be required for patients who have received fixed partial prostheses. These methods and materials include: dentifrices, brushes, flosses, holding and threading devices for floss, stimulating devices, disclosing solutions, water irrigating devices, and self-applied fluoride.²

Dentifrices. Plaque may be removed from a restoration or the teeth without the use of toothpaste. However, most patients like its taste. It gives the mouth a refreshed feeling. Fluoridated toothpastes also aid in reducing the incidence of dental caries. However, some products have been shown to cause inflammation and irritation to the soft oral tissues.³ The abrasive effect of continued use of a dentifrice, in con-

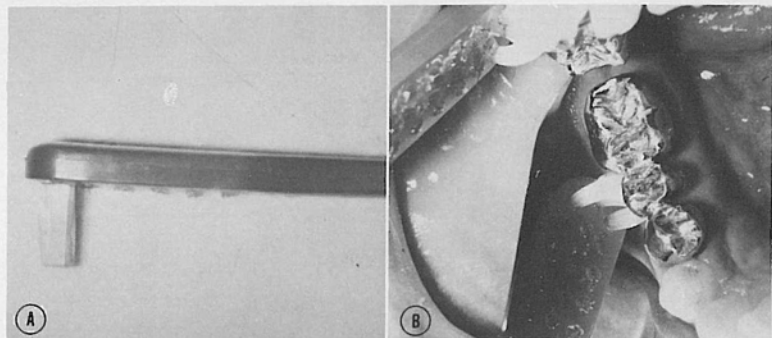


Fig. 2. (A) Multitufted toothbrush modified by removing several tufts of bristles. (B) Modified brush easily cleans difficult-to-reach regions.

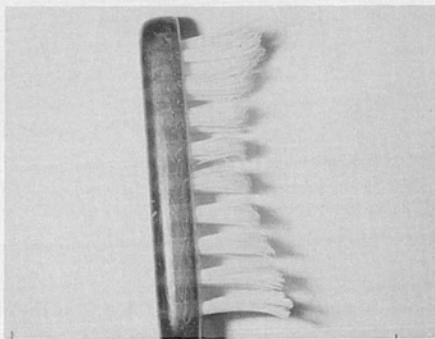


Fig. 3. A typical worn brush brought to the dental office for evaluation.

junction with improper brushing techniques, is dangerous and is not essential for the removal of the bacterial plaque.

Brushes. The toothbrush probably evolved from a type of chew stick. Any twig or root could be used, with one end "frayed out" by chewing. Very often, the other end served as a toothpick. The invention of the toothbrush is credited to the Chinese around the year 1498. Early toothbrushes were elaborate and often had gold handles. By the late 1800's, American manufacturers were producing toothbrushes of a variety of sizes and shapes.

Today, manufacturers produce millions of toothbrushes annually. Brushes are available in every color, shape, and size; are of various textures—hard, soft, and medium; have natural or nylon bristles; and are multitufted—two, three, four, or five rows, etc. Patients need guidance in the selection of a toothbrush. The size of the brush relates to the size of the oral cavity. The bristles should be polished and round on the ends to minimize abrasiveness.

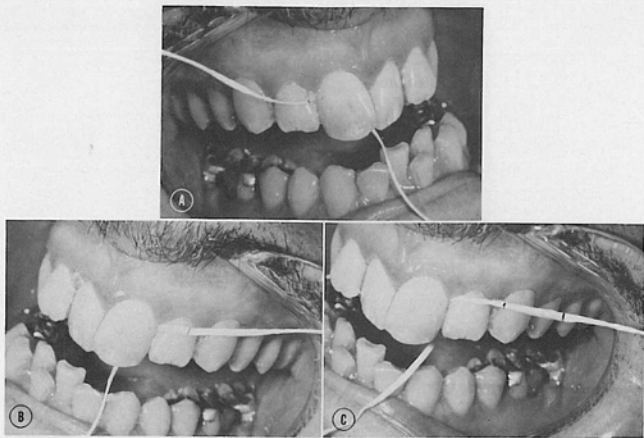


Fig. 4. (A) Floss is inserted interproximally. (B) Pulling the floss through the interdental space "drags" plaque. Line on floss indicates the area where plaque is picked up by floss. (C) Plaque is effectively removed as shown between the indicating lines on the floss.

In addition to conventional multitufted brushes, there are modified brushes which are used to clean under fixed partial dentures or between teeth where space is available. The interproximal brush is well suited for plaque disorganization in hard-to-reach areas. It is also useful for cleaning under pontics (Fig. 1). Conventional toothbrushes may be modified so that only two or three tufts of bristles remain to reach restricted regions (Fig. 2).

It may be of value to request that the patient bring the toothbrush he is using to the office. Often these brushes will be ineffective due to wear (Fig. 3).

Flosses. Should the floss be waxed or unwaxed, tape or ribbon, thick or thin? The particular floss used to eliminate plaque is not as important as the concept itself. Unwaxed floss has been advocated, because it does not leave a wax residue on the teeth. Some patients report that they prefer the wax-type floss over the unwaxed. The authors suggest using any type of floss which will effectively remove the bacterial plaque. The technique for proper flossing must be demonstrated to each patient. After a demonstration showing the floss inserted between the teeth or under a pontic, the patient is asked to repeat the task (Fig. 4). Upon completion, both the dentist and the patient recognize the ability of the patient to use floss properly.

In addition to dental floss, other similar materials may be used to eliminate plaque. An opened gauze sponge is used to clean under the pontic of a fixed partial denture. Dental floss may be tied to one corner of the gauze to act as a lead for starting the procedure which is best performed when the pontic is the sanitary type

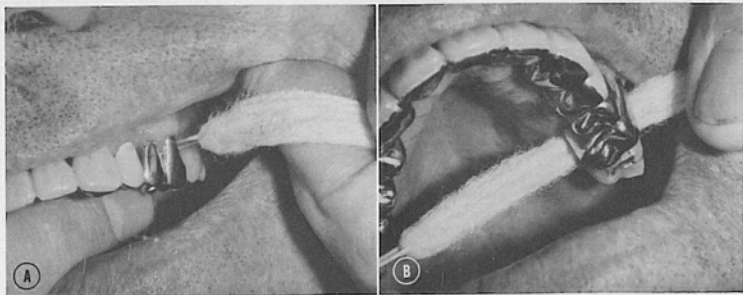


Fig. 7. (A) A floss lead guides several thicknesses of knitting yarn through a large embrasure created by removal of the distal-buccal root. (B) The porous texture of knitting yarn is well suited for plaque removal.

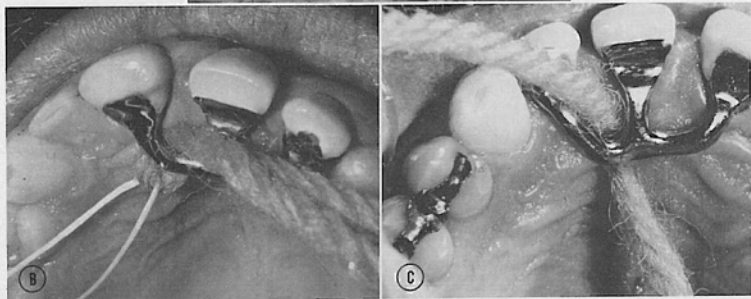
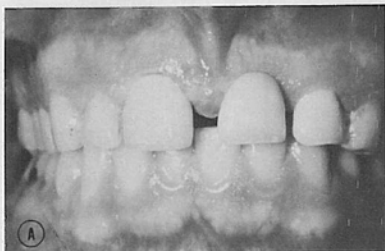

Fig. 8. (A) A maxillary anterior fixed partial denture replaces the left central incisor maintaining esthetic diastemata. (B) A floss lead pulls the yarn under the palatal bar. (C) A single thickness of yarn is all that is required to maintain a plaque-free prosthesis.

proximal surfaces of the abutments (Fig. 6). Many layers of yarn may be used for larger spaces. It is useful where periodontal disease has required the removal of a molar root (Fig. 7) and for controlling plaque formation on the tissue surface of a palatal bar prosthesis which maintains diastemata necessary for esthetics (Fig. 8). Both yarn and gauze are useful in cleaning under the stabilizing bars used in such

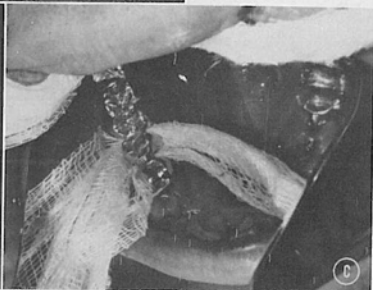
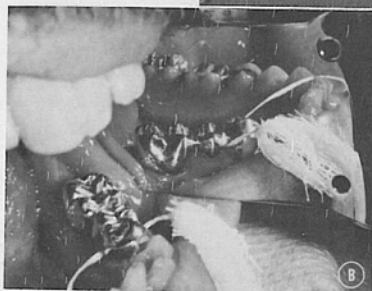
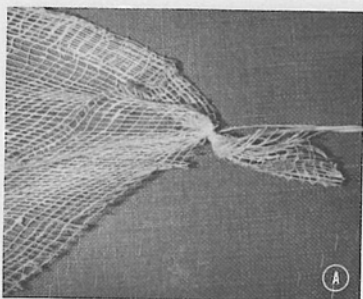


Fig. 5. (A) Dental floss tied to a corner of a gauze pad. (B) The floss "lead" is threaded under the sanitary pontic. (C) Gauze polishes the gingival surface of the pontic.

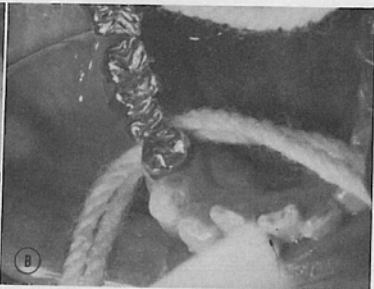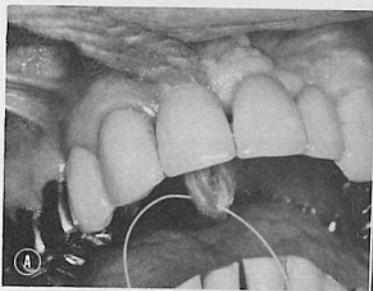


Fig. 6. (A) Knitting yarn is used to remove bacterial plaque on a maxillary anterior pontic. (B) A lower posterior pontic is cleaned using knitting yarn.

(Fig. 5). Gauze is also helpful in cleaning the distal surfaces of terminal molars. This concept is not original with contemporary man, since ancient Assyrians cleaned their teeth with the index finger covered with cloth.¹

Another floss-like modality is knitting yarn. It may be pulled back and forth under a pontic to clean plaque from the tissue, the undersurface of a pontic, and the

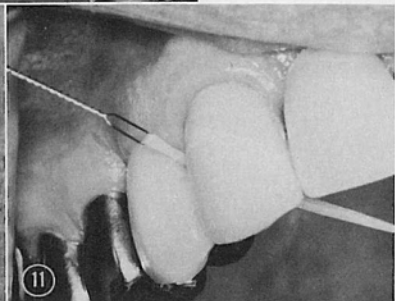
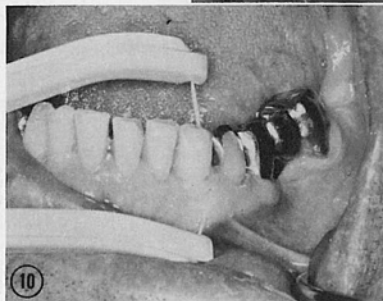
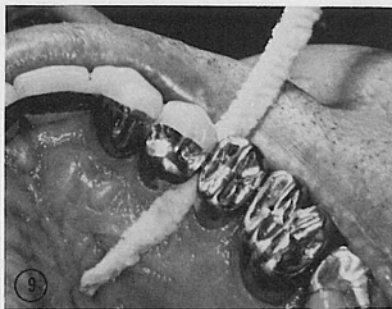


Fig. 9. A flexible pipe cleaner is useful in disorganizing bacterial plaque.

Fig. 10. A floss-carrying device assists many patients in flossing regions that are difficult to reach.

Fig. 11. Orthodontic wire, twisted to form a loop, is used as a floss threader.

prostheses as the Andrews bridge, Dolder bar, or similar clip-bar fixed-removable appliances.

Another material which will accomplish a similar result is a flexible pipe cleaner (Fig. 9). Regardless of which agent is used, *plaque disorganization* is the basic concept.

Floss holders and threaders. Floss-holding devices are numerous and available in various shapes and sizes. For patients who are unable to manipulate dental floss, especially in the posterior parts of the mouth, floss-carrying devices are valuable (Fig. 10).

Floss threaders are probably as important as the toothbrush for the elimination of bacterial plaque for patients having fixed partial dentures. One of the earlier floss threaders consisted of a loop of twisted orthodontic wire through which dental floss could be threaded (Fig. 11). The wire acted as a lead to slide the floss under a pontic or between splinted abutment teeth. Although wire floss threaders are still available, the trend is the use of plastic floss threaders. The Johnson & Johnson Zon*

*Johnson & Johnson Company, East Windsor, N. J.

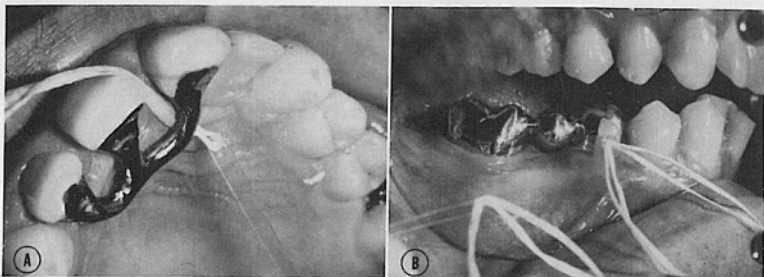


Fig. 12. (A) The Zon threads floss under the palatal bar. (B) The floss is easily placed under a posterior pontic with the aid of the Zon floss threader.

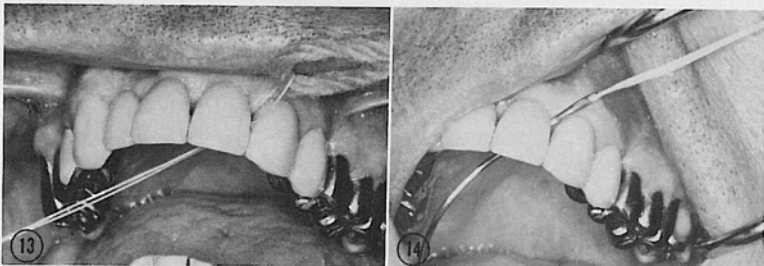


Fig. 13. The Butler Ezz-Thru floss threader collapses on itself as it pulls knitting yarn between the pontic and the abutment tooth.

Fig. 14. A modified upholstery needle may be used as a floss threader.

is a clear wedge-shaped plastic device having a small hole at its base (Fig. 12). Since it is difficult to thread the hole with floss and the wedge is too wide and has sharp, unyielding corners, the Zon has been reported by patients to cut gingival tissues, especially where space is limited.

The Butler Ezz-Thru floss-threading device* is a plastic filament having a large flexible loop that is easy to thread. The loop closes on itself as it is pulled through the region to be cleaned (Fig. 13). This device may be used to thread either dental floss or knitting yarn. It is highly recommended for patients with fixed partial dentures or splinted restorations.

In situations where commercially manufactured threading devices are unavailable, curved upholstery needles may be used after blunting the tip to avoid tissue injury. Curved surgical suture needles are similar and will also function as floss-threading instruments. The size of the thread hole and the inflexibility of these devices, however, limit their usefulness (Fig. 14).

*John O. Butler Company, Chicago, Ill.

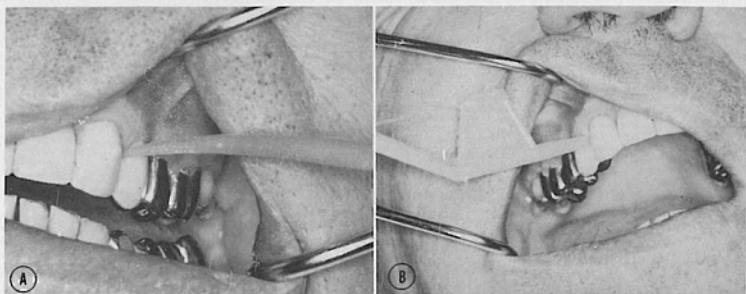


Fig. 15. (A) A plastic toothpick with raised projections is used to remove plaque. (B) A sharp plastic toothpick may damage soft tissues if the patient uses heavy force.

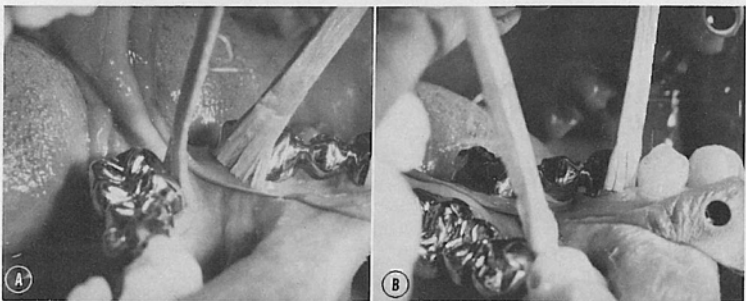


Fig. 16. (A) A moistened Stim-U-Dent used as a toothbrush. (B) The Stim-U-Dent serves as a gingival stimulator.

Picks. Toothpicks are one of the most commonly used devices for oral hygiene. Almost every restaurant makes them available to their patrons.

Handles are available which will carry a toothpick to the distant corners of the mouth, cleansing the hard-to-reach regions. Some plastic devices intended for use between the teeth have raised projections on their sides, presumably to remove dental plaque as they are passed through the interproximal space. Very often, these devices are extremely sharp and tend to lacerate the gingival tissues (Fig. 15).

Soft wooden wedges called Stim-U-Dents* are available in a matchbook-like package. When the wood is wet, it softens, which aids in removing plaque and food debris from between teeth and under pontics. The broad, flat end of the Stim-U-Dent may be moistened by chewing which spreads the wood fibers, allowing them to be used as a small toothbrush similar to a chewing stick (Fig. 16).

Stimulating devices. Rubber points and tips, often included on the handle of a toothbrush, are intended for gingival stimulation. Individual handles with separate

*Johnson & Johnson Company, East Windsor, N. J.



Fig. 17. A rubber tip is used to stimulate gingival tissues.

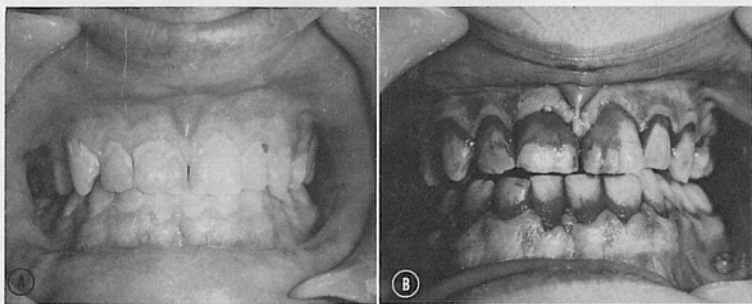


Fig. 18. (A) Plaque-covered teeth before disclosing agent is used. (B) After disclosing agent has stained bacterial deposits.

tips are also available (Fig. 17). These devices are placed interproximally and rotated in a circular motion. This action stimulates the tissue and improves circulation in the immediate region. However, they are ineffective in the total removal of plaque from interproximal areas.

Disclosing solutions. Many dentists and patients have found disclosing solutions, tablets, or wafers to be valuable in visualizing the mucin film and deposits clinging to the teeth (Fig. 18). The greatest benefit is gained by use of a disclosing agent after the mouth has been thoroughly cleansed. Since the disclosing agents do not stain the teeth, any remaining mucin or debris will be stained. The stained areas will be visually clear to the patient and may then be cleaned; thus, the patient will be assured that all plaque has been removed.

Goldman and Cohen⁵ suggest magenta concentrate (beta rose or red iron oxide) as a good dye for staining. Arnim⁶ advocates the use of compressed erythrosin in tablet form.

Glickman⁷ describes the use of a combination of basic fuchsin (6 Gm.), ethyl alcohol (95 per cent), and water as one type of disclosing solution. Potassium iodide

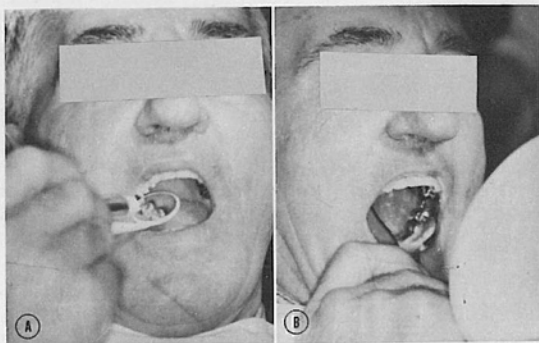


Fig. 19. (A) A small dental mirror is used by the patient to observe bacterial deposits on the lingual surface of the restored dentition. (B) A large plastic intraoral mirror provides good visibility.

(1.6 Gm.), iodine crystals (1.6 Gm.), water (13.4 c.c.), and glycerin make up 30 c.c. of another disclosing agent.

Fluorescent disclosing solutions are also commercially available, with an accompanying plaque light.* The advantage of this type of disclosing solution is that it does not stain the soft tissues red as do the dye-type disclosing agents.

The practice of using disclosing agents is very helpful in dramatizing to the patient the need for continual use of methods for plaque removal. Plaque accumulations on the lingual and gingival surfaces of pontics are often heavier than those on the facial surface of the prosthesis. It is often necessary to use a mirror to view the lingual surfaces and areas under the pontics (Fig. 19). A simple hand mirror may be given to the patient to aid in these efforts. Plastic intraoral mirror kits with small penlights attached are also available. It is wise to advise the patient to warm the mirror under warm water before placing it in the mouth. This brings the temperature of the mirror up to body temperature, and fogging is thereby prevented. Clear visibility is necessary to view remaining plaque which has been disclosed by the staining agent.

Water irrigating devices. These are hydraulic devices which use water under pressure to clean teeth. The water jet may be a spray or stream. It may have a continuous flow or be of a pulsating nature. The devices range in design from simple bathroom sink-faucet adaptors to elaborate self-contained units. When first marketed, the manufacturers suggested beneficial effects for cleaning under fixed partial dentures. However, according to the studies of Seibert,³ water irrigating devices are only effective in removing food debris and materia alba. They are ineffective in removing plaque. In addition, these devices may be detrimental to the periodontal tissues, forcing debris deeper into already inflamed gingival crevices. Water irrigating devices

*International Pharmaceutical, Warrington, Pa.

are not recommended as a means of controlling plaque deposits for the prosthetically treated patient.

SUMMARY

The philosophy of dental disease control has been discussed. Various devices used in the elimination of plaque have been listed and discussed. These include dentifrices, brushes, flosses, devices for holding and carrying floss, stimulating devices, disclosing solutions, and water irrigating devices. The responsibility for complete and thorough restorative therapy is shared by both dentist and patient. The treatment is not final when the restoration or prosthesis is inserted. Ongoing physiotherapy in the form of a rigid plaque-control program will influence the ultimate success or failure of any restorative treatment.

The authors gratefully acknowledge Mr. A. Mucha and his staff of Temple University, School of Dentistry, Audio-Visual Department, for the photographic reproductions.

References

1. Fitch, M., and Moxley, R.: Preventive Dentistry With Behavior Modifications, *J. Am. Soc. Prev. Dent.* 2: 44-46, 1972.
2. Feller, R. P.: Reduction of Enamel Solubility by Daily Use of 0.4% Stannous Fluoride Gel, *J. Dent. Res.* 53: 1280-1283, 1974.
3. Seibert, J. S.: Lecture to the Academy of Stomatology of Philadelphia, Pa., Oct. 15, 1974.
4. Garfield, S.: *Teeth, Teeth, Teeth*, New York, 1969, Simon & Schuster, Inc., pp. 28, 93.
5. Goldman, H., and Cohen, D. W.: *Periodontal Therapy*, Ed. 4, St. Louis, 1968, The C. V. Mosby Company, p. 949.
6. Arnim, S. S.: The Use of Disclosing Agents for Measuring Tooth Cleanliness, *J. Periodontol.* 34: 227-245, 1963.
7. Glickman, I.: *Clinical Periodontology*, Ed. 3, Philadelphia, 1968, W. B. Saunders Company, p. 693.

DR. BALSHI
1244 FORT WASHINGTON AVE.
FT. WASHINGTON, PA. 19034

DR. MINGLEDORFF
900 COOPERTOWN RD.
BRYN MAWR, PA. 19010