

Mandibular Rehabilitation: A Case Study Using Inferior Cadaver Graft

Thomas J. Balshi, DDS*/Mitchell J. Magid, DMD**

The visor-sandwich osteotomy augmentation and onlay bone grafts are among the various methods for rehabilitating the lower third of the face and restoring oral function. However, these methods have provided unpredictable results. When sufficient bone is available for reconstruction of atrophic jaws with endosseous implants, this can be the treatment of choice. In patients with insufficient bone available for conventional implant treatment, the use of an adjunctive inferior border graft may be considered.

(INT J ORAL MAXILLOFACIAL IMPLANTS 1995;10:589-594)

Key words: Brånemark implants, cadaver mandible, mandibular reconstruction, Procera prosthesis, severe mandibular atrophy

Bone resorption in the jaws is an inevitable consequence of edentulism. It leads to reduction of bone volume in the residual alveolar ridge, creating serious problems in the treatment of patients with conventional removable dentures. In addition to lack of denture support, bone loss in the edentulous jaw also leads to circumoral hypotonia and collapse. In extreme cases, this may result in loss of the patient's facial form.¹

There are three general areas to consider for the treatment of the severely atrophic mandible: the superior border, the body of the atrophic mandible itself, and the inferior border. Several methods of surgical bone and ridge augmentation have been used with variable results. These include onlay bone grafts, visor-sandwich osteotomy augmentation, hydroxyapatite ridge augmentation, vestibuloplasty/lowering the floor of the mouth, and the use of osseointegrated

endosseous implants. Treatment options such as vestibuloplasty or lowering the floor of the mouth are not applicable for the extremely atrophic jaw.

The use of osseointegrated implants has been shown to be an effective method for restoring the dentition, either with a fixed bone-anchored prosthesis or a stabilized overdenture.² A minimum amount of bone is required for osseointegration.

Fugler et al³ reported on 28 patients with severely resorbed mandibles, all of whom were treated with osseointegrated implants without bone grafts. This study concluded that implant treatment for severely resorbed mandibles was successful and effective. Extremely severe atrophy can lead to pathologic and spontaneous fractures.^{4,5}

A minimum of 5 mm of bone height and 6 mm of bone width is recommended for endosseous implant placement.^{6,7} There are a variety of opinions regarding the number of implants to use in treating the severely atrophic edentulous mandible. Worthington⁷ advocates using only four implants and suggests that an attempt should not be made to spread the load over a wider area of the jaw by using more implants. However, five to six implants have been used successfully in similarly atrophic mandibles for more than 5 years (unpublished results, Prosthodontics Intermedica, Fort Washington, PA). A mandibular inferior border graft has the potential to add bone volume to an extremely atrophic mandible and to provide a viable site for osseointegrated implants.⁸

*Private Practice, Prosthodontics, Prosthodontics Intermedica, Institute for Facial Esthetics, Fort Washington, Pennsylvania.

**Private Practice, Oral and Maxillofacial Surgery, Prosthodontics Intermedica, Institute for Facial Esthetics, Fort Washington, Pennsylvania.

Reprint requests: Dr Thomas J. Balshi, Prosthodontics Intermedica, Institute for Facial Esthetics, 467 Pennsylvania Avenue, 201, Fort Washington, Pennsylvania 19034.

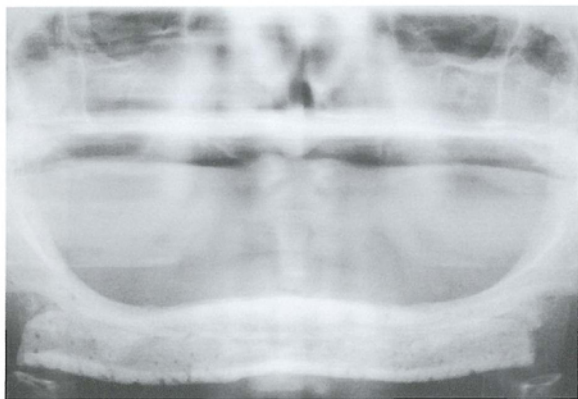


Fig 3 Panoramic radiograph of the grafted mandible immediately postoperation.

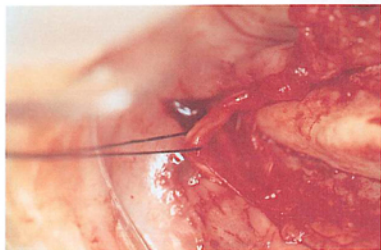


Fig 4a Neurovascular bundle repositioned inferiorly and posteriorly to permit more distal implant placement.

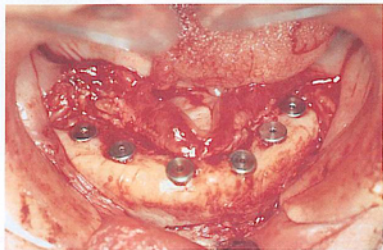


Fig 4b Six Brånemark implants, 18 x 3.75 mm, placed through the original mandible engaging grafted cadaver mandible, after 6 months of healing.

layers to eliminate dead space. The patient was seen postoperatively and healed uneventfully (Fig 3).

Stage 1 Surgery. Seven months after inferior border graft placement, the patient reported chronic pain in the right mandible and dyesthesia caused by severe atrophy of the mandible with exposure of the mental nerve on the residual ridge crest. An intraoral incision was made to expose the mental nerve. Surgical dissection also exposed the grafted portion of the mandible, which appeared to be very well ossified.

The inferior alveolar nerve was repositioned in a carefully prepared channel cut into the buccal cortex of the mandible, thereby relocating the neurovascular bundle inferiorly (Fig 4a). Following this proce-

dure, six 18 x 3.75-mm Brånemark titanium implants (Nobelpharma AB, Gothenburg, Sweden) were placed in the anterior mandible between the mental foramina (Fig 4b).

The incision was closed with interrupted sutures, and the patient was prescribed the usual medication regimen (penicillin V four times a day, acetaminophen and codeine phosphate [60 mg codeine] once every 4 hours, chlorhexidine gluconate oral rinse three times a day). Three weeks following implant placement, a temporary removable complete denture was modified and relined with a soft base material. Five weeks after implant placement, the patient presented with a minor submandibular swelling that

Case Report

A 64-year-old woman presented with a severely atrophic mandible and was unable to wear a conventional removable denture. Radiographic examination revealed an atrophic mandible with less than 4 mm of bone height, a situation with a high risk for spontaneous mandibular fracture (Fig 1). Clinical evaluation revealed ulcerated mucosa that had resulted from attempts at wearing a removable denture. The patient was psychologically stable but was considered "high strung" and "intense."

The treatment plan devised prescribed mandibular rehabilitation to be carried out in several phases, beginning with a bone graft to the inferior mandibular border and ending with a fixed implant-supported prosthesis. The following describes a multistage treatment program for a patient requiring this form of orofacial rehabilitation.

Surgical Procedure for Inferior Border Graft. The initial neck incision extended from the

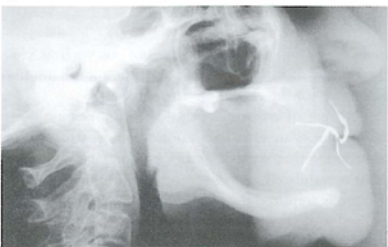

Fig 1 Preoperative lateral cephalometric radiograph. Radioopaque outline of maxillary and mandibular incisors shows the lip support provided by the removable prosthesis.

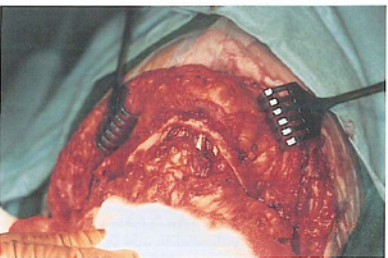


Fig 2a Surgical exposure of the inferior border of the mandible.

angle of the mandible across the cricoid region to the contralateral mandibular angle. Appropriate dissection of the flap exposed the entire inferior border of the mandible (Figs 2a and 2b). The periosteum was elevated 2 to 3 mm superiorly from the inferior border to preserve the blood supply to the existing severely atrophic mandible. A cadaver mandible was reconstituted 3 hours prior to the surgical procedure using clindamycin (900 mg) and saline (500 cc), with gentamicin (80 mg). The cadaver mandible was hollowed out using a pineapple-shaped bur with copious irrigation, creating a hollow crib to contain the contents of the bone graft. Autogenous marrow was obtained from the anterior iliac crest. Autogenous cancellous bone, also taken from the anterior iliac crest, was processed through a bone mill.

To extend the volume of the autogenous graft, 30 cc of freeze-dried cortical bone chips (100 to 200 μ m in size) were added. The freeze-dried bone chips were also reconstituted in clindamycin and gentamicin approximately 1 hour before use. A homogenous mixture of marrow (60%) and cancellous bone (40%) was then compressed to extrude any saline and antibiotic solution to obtain a compact mass of bone graft material. It was then placed in the cadaver mandible. Bacitracin irrigation (50,000 units in 250 cc of saline) was used to prepare the recipient bed prior to the placement of the cadaver mandible crib. Six transcortical holes were drilled through the inferior border of the mandible with a 1-mm wire-passing bur to allow the passage of 3-0 Maxon sutures, which were used to stabilize the crib after its placement against the inferior border of the patient's mandible. The cadaver crib was scored on its inferior surface, creating grooves to stabilize the Maxon sutures and prevent movement of the crib. Voids between the recipient mandible and the cadaver graft were packed with grafting material prior to closure. Closure of the wound was done in

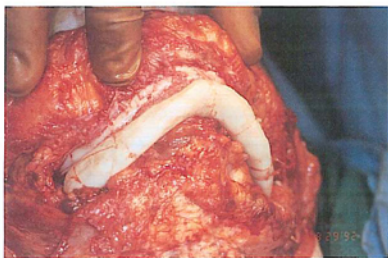


Fig 2b Ligation securely fastens cadaver graft to the mandible.

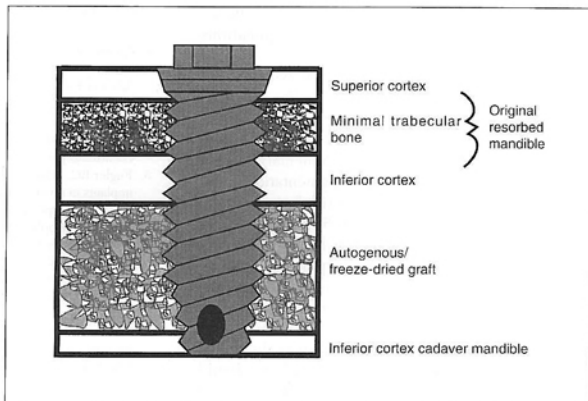


Fig 7 "Anatomy" of osseointegrated implants in the severely resorbed mandible augmented with an inferior border graft.

Discussion

Rehabilitation of the lower third of the face for patients with severe mandibular atrophy has been unsuccessfully attempted using hydroxyapatite ridge augmentation, visor-sandwich osteotomy, and onlay bone grafts stabilized with titanium screw implants. However, osseointegrated endosseous implants have been used to restore severe mandibular atrophy.⁶

When less than 5 mm of bone height precludes the direct placement of implants, augmentation of the mandible inferiorly may be considered. An inferior border graft of autogenous and freeze-dried demineralized bone in a cadaver mandible crib can become a viable host for the osseointegration of titanium screw implants once the graft site has ossified.

In considering why implants might work more successfully with an inferior border graft than an onlay graft, some thought should be given to the known resorption process long noted with onlay grafts.¹² This type of bone resorption may be the result, in part, of indirect intraoral loading, which prematurely and inadvertently occurs during oral function. In our experience, onlay rib bone grafts stabilized with endosseous implants resorb almost completely within 3 years, requiring removal of the original implants and placement of additional implants. However, our experience also shows little change in bone height or resorption around Brånemark System implants in the original mandible 4 years following initial placement and loading. Considering the lack of bone resorption noted around these implants, even in severely atrophic mandibles, the concept of engaging

the superior cortex of the original mandible with the countersink bevel of the Brånemark implant is appealing, especially if the apical portion of the implant can extend through the inferior cortical border of the original mandible and then engage a third cortical plate of the grafted cadaver mandible (Fig 7).

Following stage 2 surgery, immediate loading of an implant places the greatest stress on the most dense cortical bone at the upper third of the implant. It appears from radiographic study of severely atrophic mandibles, with or without inferior border grafts, that horizontal bone loss and postloading angular osseous defects are negligible up to 3 years postoperatively. This negligible bone loss demonstrates the superior results achieved with threaded implants in the severely atrophic mandible in conjunction with an inferior border graft. This observation may be partially a result of the long-standing vitality of the original mandibular cortices and the ability of this area of the bone-implant interface to remodel favorably, as demonstrated historically.¹⁰ Assuming vitality of the grafted area, extrapolation could suggest that maturing bone in the grafted crib will also favorably remodel in the region of the apical portion of the loaded implant.

Summary

Facial and oral rehabilitation of the lower third of the face in patients with extreme mandibular atrophy has been attempted with a variety of treatments. Grafting procedures such as visor-sandwich and onlay grafts have limited application because of the highly pre-

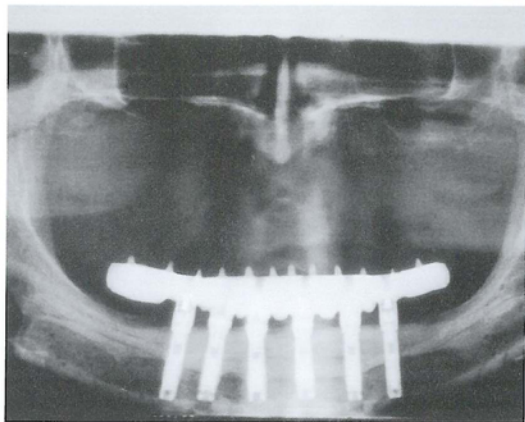


Fig 5 Panoramic radiograph of ProCera-produced, framework-supported, tissue-integrated prosthesis in cadaver-grafted mandible.

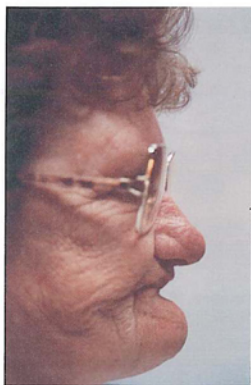

Fig 6a (Left) Preoperative profile shows loss of vertical dimension in the lower third of the face.

Fig 6b (Right) Postoperative lateral view of prosthetic restoration providing support for the lower third of the face.

decreased with ice application. The patient was placed on 500 mg of amoxicillin (Augmentin) three times a day and 500 mg of cefuroximeaxetil (Ceftin) two times a day. There was no intraoral swelling or symptoms.

Stage 2 Surgery. Four months following implant placement, the mandibular implants were uncovered. All six implants were stable and appeared to be osseointegrated. A provisional fixed conversion prosthesis⁹⁻¹¹ was fabricated immediately following stage 2 surgery. Final impressions were made im-

mediately after the abutment connection. The conversion prosthesis was used to record occlusal vertical dimension and to permit final articulation of the mandibular master cast. An irreversible hydrocolloid impression of the conversion prosthesis was poured to create a cast for recording the position of the teeth and the screw access holes for the fixed detachable prosthesis. The conversion prosthesis (Fig 5) restored oral function and provided excellent support for the muscles and tissues of the lower third of the face (Figs 6a and 6b).

dictable resorption experienced with onlay grafts, or the moderate resorption and other complications with the visor-sandwich technique.

Preservation of an existing mandible, with its generally dense cortical composition in the resorbed state, appears to be a prerequisite for the successful use of osseointegrated implants. Bone height of 5 to 7 mm is required when threaded Brånemark System implants are used without ridge augmentation; however, pathologic fracture remains a risk factor.

When bone height is less than 5 mm, augmentation of the ridge using an inferior border graft may be considered. This procedure requires substantial autogenous bone, usually harvested from the iliac crest, in combination with a freeze-dried cadaver mandible. An extended healing time of 6 to 8 months is necessary for the graft to ossify prior to the placement of endosseous implants. The implants should completely penetrate the original mandible and engage the cortex of the inferior border of the grafted mandible.

Although initially stable and clinically successful, long-term follow-up of patients treated with inferior border grafts and a fixed prosthesis is necessary. For the short term, however, it appears that collapse of the lower third of the face can be resolved using an inferior border graft in a severely atrophic mandible followed by a fixed restoration anchored to Brånemark osseointegrated implants.

Acknowledgments

The authors wish to thank Jonathan Bromber, MD, for harvesting the graft; Robert Winkelman, CDT, MDT, Fort Washington Dental Lab Inc, for fabrication of the prosthesis; Nobelpharma USA Inc for assistance with the Procera framework; Liz Kirk for manuscript preparation; and Chris Raines for computer graphics.

Résumé

*Réhabilitation Mandibulaire: Étude de Cas
Traité à l'Aide de Greffe de Cadavre*

L'augmentation par ostéotomie intercalée dite "visor" et les greffes osseuses de recouvrement font partie des méthodes diverses en vue de réhabilitation du tiers inférieur de la face et de la fonction orale. Ces méthodes aboutissent cependant à des résultats imprévisibles. Le traitement de choix se présente lorsque l'on dispose de suffisamment d'os en vue de la reconstruction des machoires atrophiées à l'aide d'implants endo-osseux. L'adjonction d'une greffe osseuse au rebord inférieur peut être considérée pour les patients présentant une déficience osseuse en vue de traitement implantaire conventionnel.

Zusammenfassung

Die Augmentation des Unterkieferknochens zur mandibulären Rekonstruktion: Eine Fallbericht unter Verwendung von allogenen Knochen

Die Visor-Sandwich-Osteotomie und Onlay-Augmentation gehören zu den verschiedenen Verfahren zur Rekonstruktion des unteren Gesichtsdrittels und der stomatognathen Funktion. Jedoch erzielten diese Verfahren unvorhersagbare Ergebnisse. Bei ausreichendem Knochenvolumen zur Rekonstruktion atrophischer Kiefer stellt die Verwendung von Implantaten das Verfahren der Wahl dar. Bei Patienten mit ungenügendem Knochenangebot könnte die Augmentation des Unterkieferknochens als zusätzliche Therapie zur Implantation in Betracht gezogen werden.

References

- Carlsson GE, Haraldsson T. Fundamental aspects of mandibular atrophy. In: Worthington P, Brånemark P-I (eds). *Advanced Osseointegration Surgery*. Chicago: Quintessence, 1992:109-118.
- Adell R, Lekholm U, Rockert B, Brånemark P-I. A 15-year study of osseointegrated implants in the treatment of the edentulous jaw. *Int J Oral Surg* 1981;10:387-416.
- Fugler RC, Mason M, Triplett RG. Endosseous cylinder implants in severely atrophic mandibles [abstract 998]. *J Dent Res* 1990;69(special issue):233.
- Alt JHM. Atrophy of the mandible and spontaneous fracture: A report of two cases. *Br Dent J* 1963;114:118-190.
- Tolman DE, Keller EE. Management of mandibular fractures in patients with endosseous implants. *Int J Oral Maxillofac Implants* 1991;6:427-436.
- Keller EE, Desjardins RP, Tolman DE, Lancy WR, van Roekel NB. Reconstruction of the severely resorbed mandibular ridge using the tissue-integrated prosthesis. *Int J Oral Maxillofac Implants* 1986;1:101-109.
- Worthington P. Clinical aspects of severe mandibular atrophy. In: Worthington P, Brånemark P-I (eds). *Advanced Osseointegration Surgery*. Chicago: Quintessence, 1992:119-122.
- Quinn P, Kent K, MacAfee KA II. Reconstructing the atrophic mandible with inferior border grafting and implants: A preliminary report. *Int J Oral Maxillofac Implants* 1992;7:87-93.
- Balshi T. The Biotes conversion prosthesis: A provisional fixed prosthesis supported by osseointegrated titanium fixtures for restoration of the edentulous jaw. *Quintessence Int* 1985;16:667-677.
- Balshi T. Converting patients with periodontally hopeless teeth to osseointegrated prostheses. *Int J Periodont Rest Dent* 1988;8(2):9-33.
- Balshi T. The conversion prosthesis: A provisional fixed prosthesis supported by osseointegrated titanium fixtures. In: van Steenberghe D (ed). *Tissue Integration in Oral and Maxillofacial Reconstruction* [Proceedings of an International Congress, May 1985, Brussels]. Amsterdam, The Netherlands: Excerpta Medica, 1986.
- Davis DM. The role of implants in the treatment of edentulous patients. *Int J Prosthodont* 1990;3:42-50.

Resumen

Rehabilitación mandibular: Un caso en el que se utilizó un injerto de la parte inferior de un cadáver

Se han reportado varios métodos para la rehabilitación del tercio inferior de la cara y para la restauración de la función oral. Ejemplos de estos métodos son el aumento y osteotomía en sandwich-visera y los injertos óseos "onlay". Sin embargo, estos métodos no han presentado resultados pronosticables. Cuando existe suficiente hueso para la reconstrucción de mandíbulas atrofiadas, por medio de implantes endoséos, éste puede ser el tratamiento preferido. En pacientes con hueso insuficiente para el tratamiento convencional con implantes, el uso adicional de un injerto para el borde inferior puede ser considerado.