

Osseointegration to Reconstruct Lower-Lip Support for the Severely Atrophic Mandible

Thomas J. Balshi, DDS

Osseointegrated implants are becoming an excellent choice to permanently reconstruct lost dentition and lower-lip support. Evidence is mounting to support this procedure as the prosthodontic wave of the future.

Collapse and inversion of the lower lip and perioral musculature frequently follow total loss of teeth and subsequent loss of the alveolar ridge. The remaining mandibular bone may atrophy further, thereby creating additional intraoral complications that make the use of conventional denture prosthodontics difficult or frequently impossible. This leaves the patient without the benefit of any form of intraoral lip support (Figures 1, 2a and 2b).

Several reconstructive methods have been used in the past to reha-

bilitate the atrophic mandible. These have included rib and iliac crest autogenous grafts, although this material has had only limited success. More recently, hydroxyapatite crystal or block implantation has also been used to rebuild the residual ridge. In both cases, the "best" results have permitted the patient to only wear a removable denture.

The proven success of osseointegration now allows the permanent reconstruction of lower lip support¹ and patients no longer need to depend on removable-denture prosthodontics to establish intraoral soft-tissue support. Permanent teeth can be installed in cases of even the most severe maxillary or mandibular atrophy.

Reconstructive facial surgeons

and prosthodontists together can produce drastic changes to enhance facial features with a high degree of predictability.

The basis for long-term success stems from the stability created by the osseointegrated titanium fixtures serving as the basis for the jawbone-anchored prosthesis.

The term *osseointegration* was coined by Per-Ingvar Branemark, the Swedish orthopedic surgeon who has been involved in the research and development of processes for implantation and reconstruction since 1952. These techniques create a direct structural and functional connection between ordered living bone and the surface of a load-carrying implant (Figures 3 and 4).²

Biotes titanium screw implants

Thomas J. Balshi, DDS, FACP, is a prosthodontist in Fort Washington, Pa. and president, Pennsylvania chapter of the American College of Prosthodontists.

tial prerequisite to cosmetic surgery. Restoring proper dental occlusal vertical dimension reestablishes the functional as well as positional relationship of the lower third of the face.

The degenerative bone loss associated with removable dentures is always inevitable. Unfortunately, it often goes unnoticed by the patient. The plastic and reconstructive surgeon must carefully assess those effects that have degenerative changes in dental support on the long-term prognosis of the face-lift.

Patients functioning for two or more years with a removable dental prosthesis should be examined by a prosthodontist prior to any elective cosmetic surgery. This can determine if the existing prosthesis provides adequate dental func-

tion and facial soft-tissue support.

The effects of the tissue-integrated prosthesis on plastic and reconstructive surgery are significant. Perioral age lines are frequently apparent with severe or even moderate intraoral collapse. These are often reduced and sometimes virtually eliminated through a combination of prostheses with standard rhytidectomy or dermabrasion procedures.

The use of osseointegrated Biotes fixtures has an excellent prognosis, even for patients with systemic diseases (such as diabetes), oncologic patients receiving chemotherapy, or post-radiation patients.³

Osseointegrated fixtures have worked well in healthy persons and have supported nonremova-

ble dental bridges for over 20 years. It is not unlikely that such reconstruction methods can successfully provide function and support that simultaneously maintains residual bone levels for many years.

Osseointegration realistically provides a superior alternative to the constant problems and changing facial support experienced with conventional removable dentures. □

Bibliography

1. Adell R, Lekholm U, Rockler B, et al: A 15-year study of osseointegrated implants in the treatment of the edentulous jaw. *Int J Oral Surg* 1981;10:387.
2. Branemark PI: Osseointegration and its experimental background. *J Prosthet Dent* 1983;50:399-410.
3. Branemark PI, Zarb G, Albrektsson T: *Tissue Integrated Prosthesis. Osseointegration in Clinical Dentistry*. Chicago, Quintessence Publishing Co, Inc, 1985.

Bernard Bragg has won critical acclaim as an actor.

He has never heard applause.

Bernard Bragg is a co-founder of The National Theatre of the Deaf. He has performed on television and Broadway and was an artist-in-residence at the Moscow Theatre of Mimicry and Gesture. He has studied under Marcel Marceau and taught workshops at Harvard University.


PHOTO: LINDA JO HILTON

Believe in them. Break the barriers.

PRESIDENT'S COMMITTEE ON EMPLOYMENT OF THE HANDICAPPED, WASHINGTON D.C. 20210

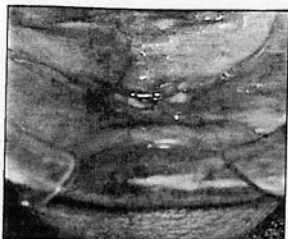

Figure 1. Atrophic mandibular alveolar ridge.

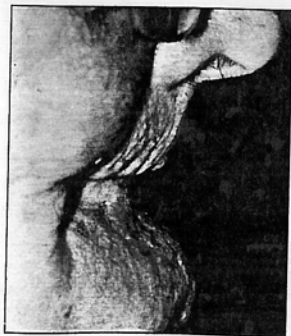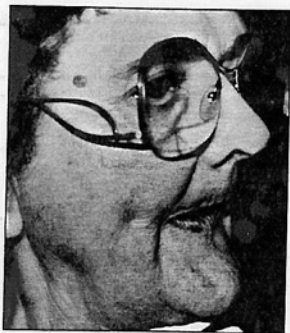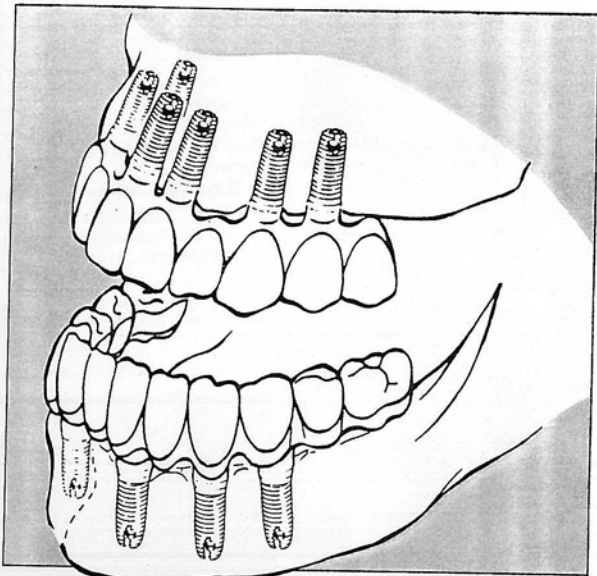


Figure 2a and 2b. Collapse and inversion of the lower lip and perioral musculature.

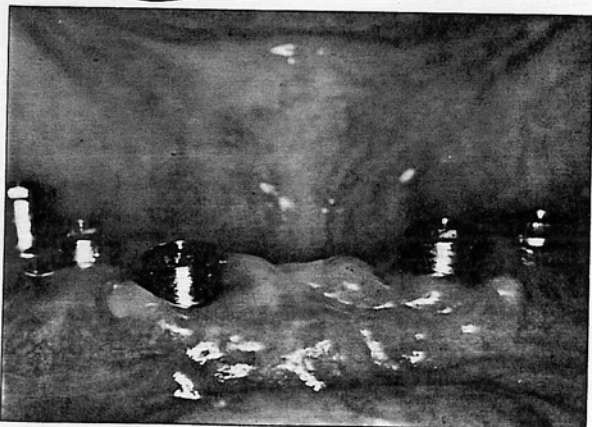


Figure 3. The osseointegration concept illustrates the Biotes fixtures supporting both maxillary and mandibular tissue integrated prostheses.

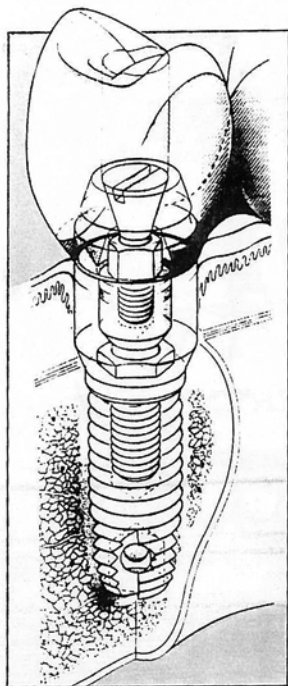


Figure 4. The Biotes concept depends on osseointegration of Biotes titanium fixtures (implants) supporting a specially designed prosthesis.



Figure 5. Securely integrated in the mandibular bone, titanium screw implants with a custom-designed gold substructure support the prosthesis.

are securely integrated in the remaining mandibular bone and a custom gold substructure is designed to support prosthetic teeth (Figure 5). This allows the teeth to be supported anteriorly and laterally well beyond the point of muscle attachment. This occurrence previously limited denture position and provided only minimal lip support.

When adequate lip support and dental aesthetics have been established, the prosthesis is completed using conventional gold and acrylic denture materials.

The prosthesis and titanium Biotes implanted fixtures have been referred to as the *tissue-integrated prosthesis* because this

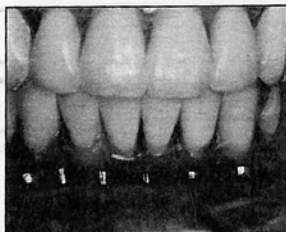

Figure 6. Frontal view of the Biotes tissue-integrated prosthesis that has become one with the jawbone.

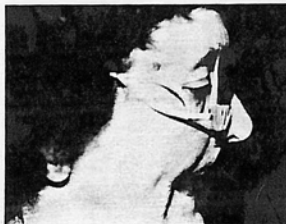

Figure 7. Preoperative profile photograph of a 72-year-old woman with severe perioral collapse.

prosthesis becomes fully integrated with the jawbone when small gold screws are used to fasten the custom-designed dental replacement securely to the titanium fixtures (Figure 6).

Figures 7, 8a, and 8b demonstrate the preoperative and postoperative profile view of a 72-year-old woman showing severe perioral collapse followed by osseointegrated intraoral reconstruction.

According to Pappas, Rojer and Rosenfeld (personal communication, February 6, 1984), reconstructive facial surgeons now believe that many patients currently wearing removable dentures or contemplating cosmetic surgery should have the permanent restoration of proper intraoral support. This is likely to become an essen-

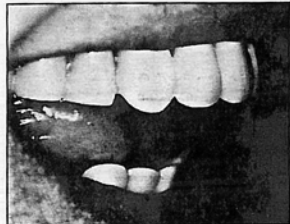
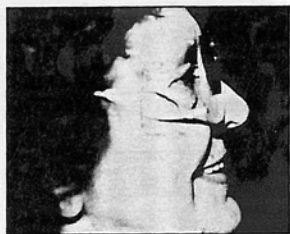

Figure 8a and 8b. Postoperative profile photos following osseointegration intraoral reconstruction.

continued

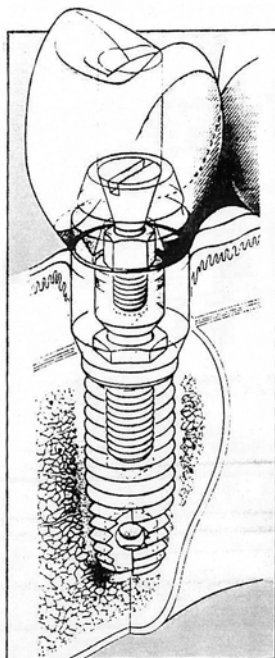


Figure 4. The Biotes concept depends on osseointegration of Biotes titanium fixtures (implants) supporting a specially designed prosthesis.



Figure 5. Securely integrated in the mandibular bone, titanium screw implants with a custom-designed gold substructure support the prosthesis.

are securely integrated in the remaining mandibular bone and a custom gold substructure is designed to support prosthetic teeth (Figure 5). This allows the teeth to be supported anteriorly and laterally well beyond the point of muscle attachment. This occurrence previously limited denture position and provided only minimal lip support.

When adequate lip support and dental aesthetics have been established, the prosthesis is completed using conventional gold and acrylic denture materials.

The prosthesis and titanium Biotes implanted fixtures have been referred to as the *tissue-integrated prosthesis* because this

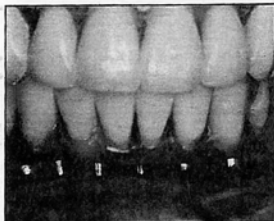


Figure 6. Frontal view of the Biotes tissue-integrated prosthesis that has become one with the jawbone.

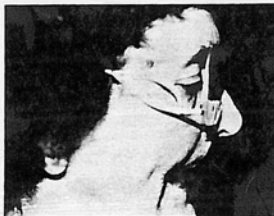

Figure 7. Preoperative profile photograph of a 72-year-old woman with severe perioral collapse.

prosthesis becomes fully integrated with the jawbone when small gold screws are used to fasten the custom-designed dental replacement securely to the titanium fixtures (Figure 6).

Figures 7, 8a, and 8b demonstrate the preoperative and postoperative profile view of a 72-year-old woman showing severe perioral collapse followed by osseointegrated intraoral reconstruction.

According to Pappas, Rojer and Rosenfeld (personal communication, February 6, 1984), reconstructive facial surgeons now believe that many patients currently wearing removable dentures or contemplating cosmetic surgery should have the permanent restoration of proper intraoral support. This is likely to become an essen-

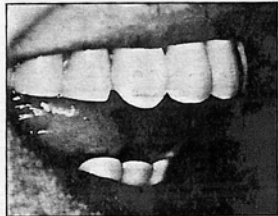
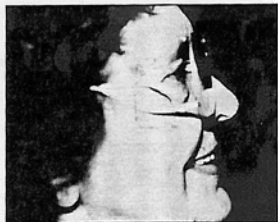

Figure 8a and 8b. Postoperative profile photos following osseointegration intraoral reconstruction.

continued

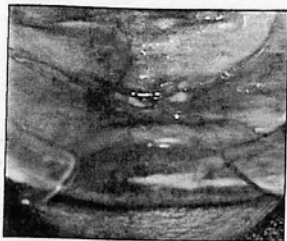


Figure 1. Atrophic mandibular alveolar ridge.

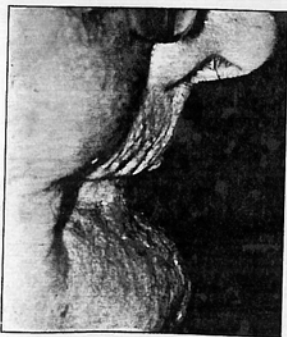
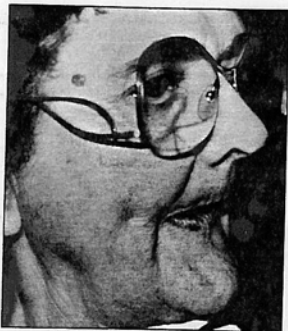
Figure 2a and 2b. Collapse and inversion of the lower lip and perioral musculature.

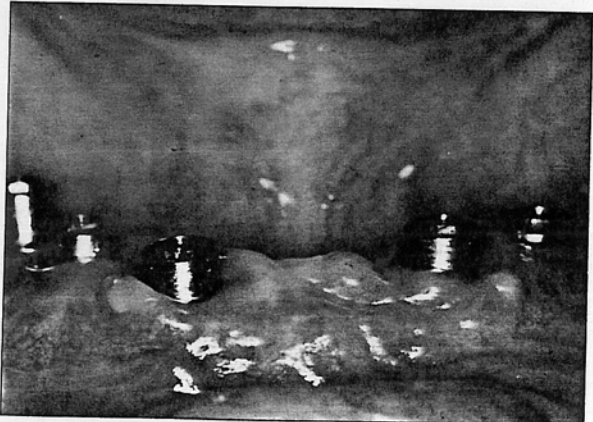
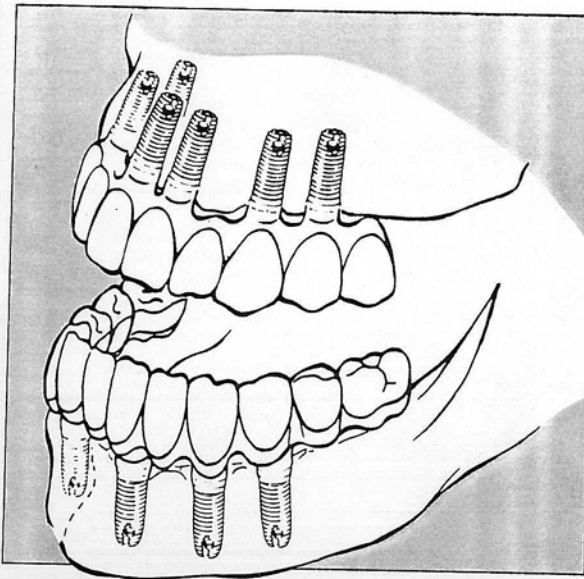


Figure 3. The osseointegration concept illustrates the Biotes fixtures supporting both maxillary and mandibular tissue integrated prostheses.