



TREATMENT OF A SEVERELY ATROPHIC MAXILLA USING AN IMMEDIATELY LOADED, IMPLANT-SUPPORTED FIXED PROSTHESIS WITHOUT THE USE OF BONE GRAFTS: A CLINICAL REPORT

Jeffrey S. Sherry, DDS, MSD,^a Thomas J. Balshi, DDS,^b Lawrence O. Sims, DDS,^c and Stephen F. Balshi, MBE^d

This report describes a clinical approach to using the zygomatic and pterygomaxillary bones to provide additional anchorage for longer implants to support an immediately functional maxillary screw-retained provisional fixed prosthesis. The purpose is to report the problems of patients who have experienced the most severe form of maxillary alveolar resorption and to demonstrate a specific protocol which provides immediately loaded implants without bone grafting. (J Prosthet Dent 2010;103:133-138)

The problems experienced by the patient described in this report are common to many patients who have worn removable prostheses and have progressive alveolar atrophy, resulting in difficulties with mastication and prosthesis retention.¹⁻³ Implant therapy and restoration of the severely resorbed edentulous maxilla poses a unique set of difficulties for the surgeon and the restorative dentist. In particular, this type of treatment in the past may have included particulate autogenous bone, with barrier membranes and stabilizing tacks and screws or large autogenous iliac crest block grafts.^{4,5} Other bone grafting options have included allograft,⁵ xenograft,^{6,7} monocortical blocks,⁵ or iliac crest grafts to augment the existing residual ridge both vertically and laterally.^{8,9}

Grafting in severely resorbed situations is most often accomplished as part of a 2-stage implant protocol, which is followed by a 3- to 6-month healing period to allow for maturation of the graft prior to the placement of dental implants. Once the implants have been placed, they have historically remained submerged for several months, undisturbed, prior to a second surgery to “uncover” the

implants and place abutments for fabrication of the definitive prosthesis.^{10,11} The time from the start to the completion of treatment for a patient requiring such bone grafting can be more than a year and include multiple surgeries, increased potential for complications, and donor site morbidity.¹²⁻¹⁴

The concept of immediately loading implants has been well documented in the literature.¹⁴⁻¹⁸ The maxillary arch poses difficulties for immediate loading that are not found for the mandible. These difficulties include a predominance of type III and IV bone, shown to be responsible for an increased number of implant failures,¹⁹⁻²¹ as well as the presence of the maxillary sinus, which can limit the quantity of vertical bone necessary to place implants. To provide patients with a successful, immediately loaded prosthesis, these problems must be overcome. Use of the pterygomaxillary and zygomatic regions has been shown by others to be a viable treatment modality to support immediate implant placement and the immediately loaded fixed prosthesis.²²⁻³⁴ The median palatal bone, which has been shown to have a high percentage of dense bone relative to total bone

volume,³⁵ should also be considered, as needed, to provide additional stability during implant surgery and the provisional restoration phase. The purpose of the treatment described in this clinical report was to provide the patient with an immediately loaded, functional maxillary fixed prosthesis without bone grafting surgery in a single visit, demonstrating that even the most severely resorbed maxilla can be restored and functionally loaded when the pterygomaxillary and zygomatic regions are used for implant support.

CLINICAL REPORT

A 69-year-old woman with a medical history of well controlled type II diabetes presented to a private practice with the chief complaint that she was unable to wear her maxillary complete removable denture. She had been provided with several treatment options over the years, including bone grafting techniques that she believed were unacceptable. Prosthodontic treatment options were discussed, including bone grafting, implant placement, and delayed loading. She ultimately accepted a treatment plan that would allow for fixed, screw-retained maxillary and mandibular prostheses

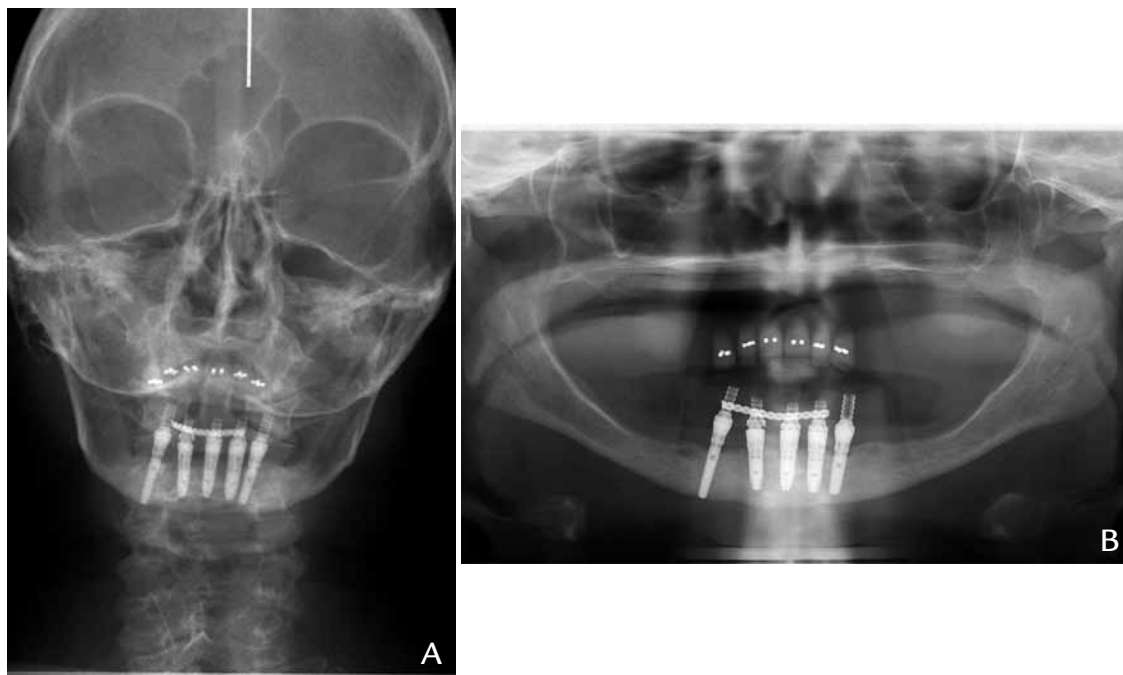
^aPrivate practice, Douglasville, Ga.

^bPrivate practice, Fort Washington, Pa.

^cPrivate practice, Atlanta, Ga.

^dPrivate practice, Fort Washington, Pa; dental laboratory, Mahwah, NJ.





1 A, Cephalometric radiograph, frontal view, depicting advanced atrophy of maxilla. B, Panoramic radiograph depicting advanced atrophy of maxilla.

with immediate loading.

An immediate, functionally loaded, maxillary fixed implant-supported acrylic resin provisional prosthesis was planned for insertion immediately following implant placement, to be followed in 3 months with a definitive ceramic prosthesis using a milled titanium framework. A mandibular immediate fixed prosthesis had been fabricated for the patient 1 year prior to treatment of the maxilla. The patient was evaluated clinically and radiographically using traditional panoramic and cephalometric films, which revealed the extreme degree of bone loss and the complexity of future prosthetic treatment (Fig. 1).

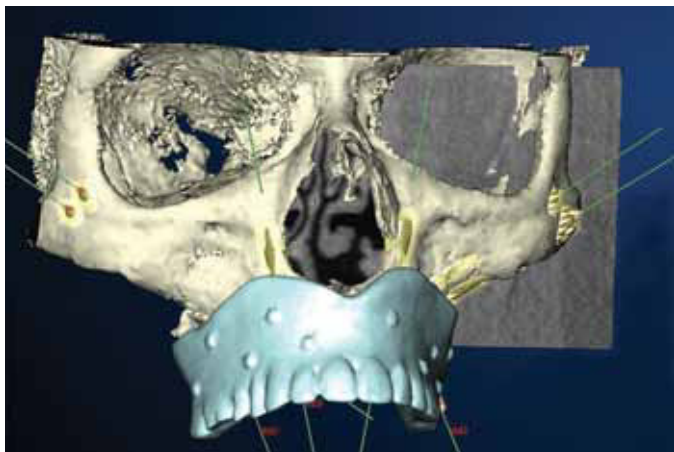
A cone beam computed tomography (CBCT) scan (i-CAT; Imaging Sciences Intl, Hatfield, Pa) was performed to acquire additional radiographic data and to assist with surgical and prosthodontic treatment planning. Prior to scanning, a new maxillary denture was made for the patient, with emphasis on the accuracy of intaglio surface fit and esthetics. Fourteen uniform but randomly positioned perforations were made in the denture using a no. 8 round bur (Brasseler USA, Savannah, Ga). The perforations were

then filled with gutta-percha (Coltène/Whaledent, Inc, Cuyahoga Falls, Ohio), creating fiduciary radiographic markers used by the planning software, according to a specific guided surgery protocol (NobelGuide, Procera; Nobel Biocare USA, Yorba Linda, Calif) that uses a dual-scan technique to acquire the pertinent information.³⁶⁻³⁸

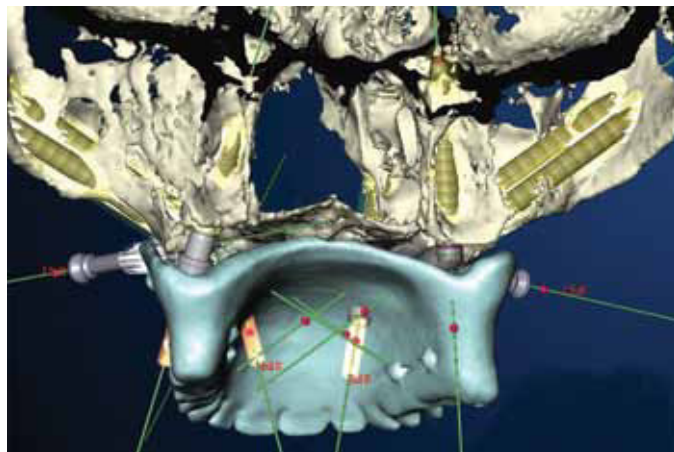
The digital imaging and communications in medicine (DICOM) formatted files that were exported from the CBCT scan were converted into a proprietary 3-dimensional (3-D) format so that further evaluation and virtual implant planning could begin. The software was used to plan implant locations for the pterygomaxillary, lateral-nasal, midpalatal, and zygomatic areas (Figs. 2 and 3). One implant (NobelSpeedy Groovy; Nobel Biocare USA) was planned for each of the pterygomaxillary and lateral-nasal areas. Canine eminences did not exist in the patient, just a narrow isthmus of bone separating the lateral aspect of the nose and the maxillary sinus. Two additional implants (Brånemark System; Nobel Biocare USA) were planned for each zygomatic region. A single short implant (Brånemark System Shorty) was planned for the

midpalate to increase the stability of the surgical template and, if needed, to help support the fixed provisional prosthesis during the initial healing and osseointegration period. Following completion of the virtual implant planning, the data was uploaded to the manufacturing facility (Nobel Biocare AB, Göteborg, Sweden) for fabrication of a surgical template (Fig. 4). At the time of the procedure, the guided surgery protocol was not compatible with all phases for placement of a zygomatic implant. Preparation and placement of the zygomatic implants were accomplished freehand, using flap reflection and direct vision, even though they were included in the virtual planning.

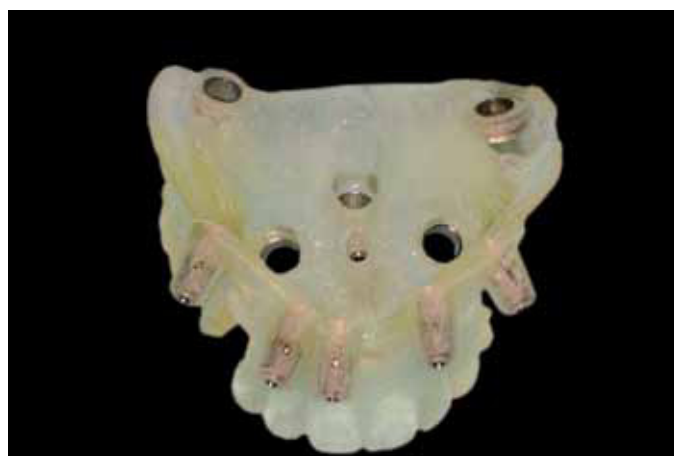The patient was draped and prepared for implant surgery in the standard sterile fashion ad modum Brånemark.³⁹ The anesthesiologist administered general anesthesia with nasal intubation, followed by local anesthesia that included 8 carpules of bupivacaine 0.5% with 1:200,000 epinephrine (Hospira, Inc, Lake Forest, Ill), and 4 carpules of lidocaine 2% with 1:50,000 epinephrine (Novocol Pharmaceutical of Canada, Inc, Cambridge, Ontario, Canada). The local



2 Three-dimensional image of maxilla, including removable maxillary denture planning prosthesis.



3 Three-dimensional image of virtual plan, emphasizing zygomatic and midpalatal implant locations.



4 Surgical template with guide sleeves indicating implant locations.

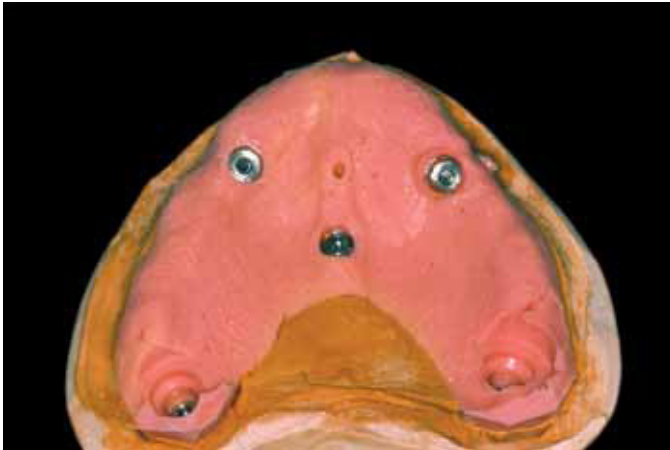anesthesia was administered high into the vestibular areas to avoid changing the volume topography of the palate at the beginning of the surgery.

The surgical template was aligned intraorally using a surgical index provided by the laboratory (CM Ceramics USA, Mahwah, NJ). A 1.5-mm twist drill (Nobel Biocare USA) was used to prepare osteotomies to place 6 anchor pins (Nobel Biocare USA) designed to secure the surgical template. One of the anchor pins was positioned on the palate to engage palatal and septal bone. The surgical index was then removed to begin preparation for implant placement. Soft tissue was removed and crestal bone was profiled using the guided counterbore drill (Nobel Biocare USA). A 2-mm guided twist drill (Nobel Biocare USA) was used, followed by a 3-mm twist drill (Nobel Biocare

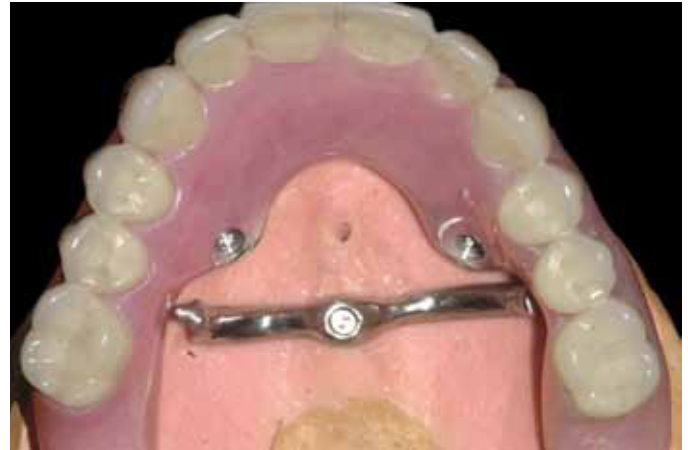USA), to prepare the implant osteotomies. The following implants were placed using the template: a midpalatal implant (Brånemark System Mk III Shorty, 4 x 7-mm implant; Nobel Biocare USA) was placed first, to provide additional stabilization for the surgical template, then the right and left pterygomaxillary implants (Nobel Speedy Groovy; Nobel Biocare USA), 4 x 18 mm, were placed. The right and left lateral-nasal sites received 3.75 x 15-mm implants (Brånemark System Mk III Groovy; Nobel Biocare USA). The surgical template was removed, and 4 zygomatic implants (Brånemark System, Nobel Biocare USA) were placed in the manner previously reported.³⁴

Zygomatic implants (Brånemark System; Nobel Biocare USA) were placed in the premolar and first molar areas on each side. Conical abut-

ments (EsthetiCone; Nobel Biocare USA) were placed on the lateral-nasal implants and low-profile abutments (Standard; Nobel Biocare USA) on the pterygomaxillary implants. Thirty-degree angled conical abutments (EsthetiCone; Nobel Biocare USA) and long guide pins (Nobel Biocare USA) were placed on the zygomatic implants and rotated to position the screw access holes closer to the occlusal table, minimizing the palatal bulge that can be associated with zygomatic implants. A maxillary acrylic resin screw-retained provisional prosthesis with a cast, midpalatal strut was fabricated prior to implant surgery, using a definitive cast retro engineered from the surgical template (Figs. 5 and 6), following this specific guided surgery protocol.^{37,38,40} The surgical template allows for fabrication of the definitive cast by specific hardware components



5 Definitive cast made from surgical template. Implant replicas are present in lateral-nasal, pterygomaxillary, and midpalatal locations.



6 Fixed provisional prosthesis mounted on definitive cast. Note midpalatal strap engaging midpalatal implant. Strap was designed to engage midpalatal implant to provide additional stability for immediately loaded prosthesis, if deemed necessary.

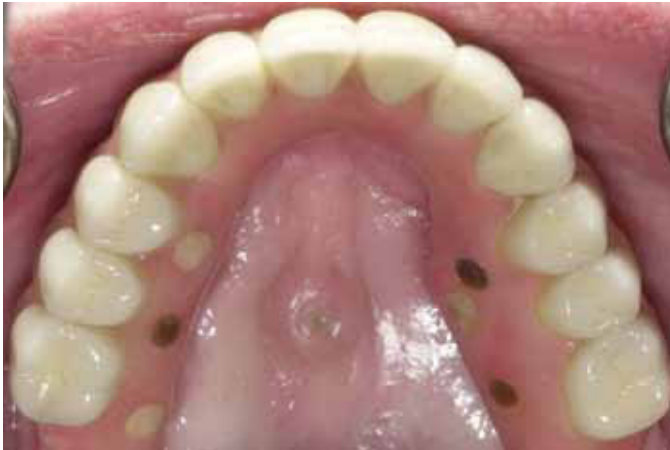(Nobel Biocare USA), setting the implant replicas in the precise positions planned virtually.

The prosthesis was fabricated on the previously mentioned abutments, instead of on the traditionally used guided abutments (Nobel Biocare USA). It is the authors' preference to use the style of abutment that is placed on the implant and never removed.⁴¹ The palatal acrylic resin of the maxillary provisional fixed prosthesis was relieved in the area of the zygomatic implants, permitting unobstructed placement of the prosthesis onto abutments of the pterygomaxillary and lateral-nasal implants. Using a technique designed to convert a removable prosthesis into a fixed, implant-supported provisional prosthesis,⁴² a rubber dam (Hygenic; Coltène/Whaledent, Inc) was trimmed, marked using an ink stick (Dr. Thompson's Sanitary Color Transfer Applicators; Great Plains Dental Products Co, Inc, Kingman, Kan) to locate the precise position for the rubber dam punch, and placed over the implant abutments and the stainless steel prosthetic cylinders. These copings were used with the rubber dam in place to help prevent acrylic resin from locking into undercuts during the coping luting process, and to protect the underlying tissue.

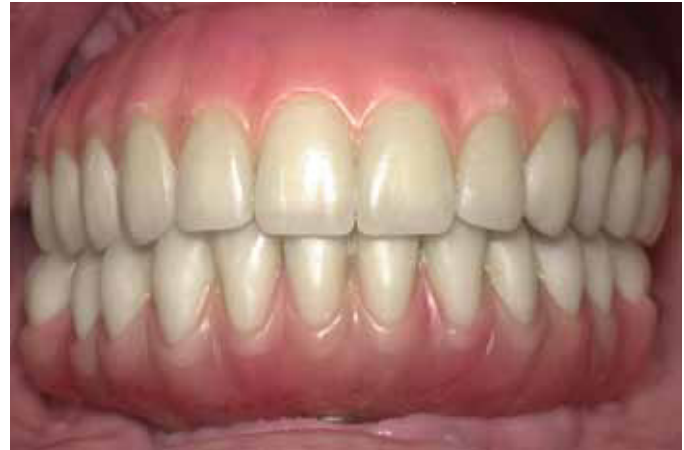The prosthesis was inserted and fully seated on the 4 implants that were placed using the surgical template. The prosthesis was then screwed into place with hand tightening. Acrylic resin (Jet Acrylic; Lang Dental Mfg Co, Wheeling, Ill) was mixed, loaded into a syringe (Monoject Syringe; Kendall Healthcare, Mansfield, Mass), and flowed around the zygomatic prosthetic cylinders to join them to the fixed prosthesis. The provisional prosthesis was then removed from the patient, refined, and polished in the laboratory. The tissue was sutured (4-0 interrupted Vicryl sutures; Ethicon, Inc, Somerville, NJ). It was determined that the placed implants could support immediate function without the palatal implant, so the metal strap that was fabricated was removed and not used. A cover screw was placed on the palatal implant. The flap was sutured prior to placement of the prosthesis to maximize visibility and access to the wound margins, to obtain primary closure. The completed provisional acrylic resin prosthesis was then screwed into position with a uniform torque force of 15 Ncm.

Three months following the initial implant surgery and provisional prosthesis placement, the provisional restoration was removed. All implants were clinically determined to

be stable, with no mobility. The provisional restoration was replaced with long guide pins (Nobel Biocare USA), and a definitive open-tray impression was made by using the maxillary fixed provisional prosthesis as an impression template. Heavy-body impression material (Reprosil; Dentsply Intl, York, Pa) was syringed beneath the acrylic resin maxillary implant prosthesis, and a pick-up impression was made. Abutment replicas (EsthetiCone and Brånemark standard abutment replicas; Nobel Biocare USA) were placed onto the temporary cylinders of the provisional prosthesis. A soft tissue (Gingifast Rigid; Zhermack, Inc, Eatontown, NJ) definitive cast using type IV die stone (Vel-Mix; Kerr Corp, Orange, Calif) was poured and separated from the provisional prosthesis. The maxillary and mandibular casts were articulated using the provisional prosthesis and an occlusal registration (Regisil 2x; Dentsply Intl). The dental laboratory (CM Ceramics USA, Mahwah, NJ) fabricated a definitive maxillary fixed prosthesis using a custom-milled titanium framework with pink gingival methyl methacrylate resin (Clássico resin; Clássico Artigos Odontológicos Ltda, São Paulo, SP, Brazil), individual alumina ceramic copings (Procera; Nobel Biocare USA), and individual



7 Definitive maxillary prosthesis in function for more than 30 months.



8 Definitive maxillary and mandibular implant-supported prostheses.

porcelain (NobelRondo Alumina; Nobel Biocare USA) crowns fused to the copings, designed to provide mutually protected occlusion (Figs. 7 and 8).

The patient cleans the prosthesis twice each day using a toothbrush and irrigation device (Water Pik, Inc, Ft. Collins, Colo). All implants have remained in function over the past 30 months, and the patient follows her prescribed professional hygiene recall schedule.

SUMMARY

Combined computer-guided and freehand implant surgical techniques improve surgical precision, efficiency, and treatment outcomes in the atrophic maxilla. Even patients with the most severe forms of alveolar atrophy of the maxilla can be candidates for treatment with an immediately loaded, fixed, screw-retained prosthesis with trained, skillful use of the pterygomaxillary and zygomatic regions. This treatment can be accomplished without bone grafts.

REFERENCES

- Carlsson GE, Bergman B, Hedegård B. Changes in contour of the maxillary alveolar process under immediate dentures. A longitudinal clinical and x-ray cephalometric study covering 5 years. *Acta Odontol Scand* 1967;25:45-75.
- Tallgren A. The continuing reduction of the residual alveolar ridges in complete denture wearers: a mixed-longitudinal study covering 25 years. *J Prosthet Dent* 1972;27:120-32.
- Carlsson GE. Responses of jawbone to pressure. *Gerodontology* 2004;21:65-70.
- Gomes KU, Carlini JL, Biron C, Rapoport A, Dedivitis RA. Use of allogeneic bone graft in maxillary reconstruction for installation of dental implants. *J Oral Maxillofac Surg* 2008;66:2335-8.
- Trombelli L, Farina R, Marzola A, Itró A, Calura G. GBR and autogenous cortical bone particulate by bone scraper for alveolar ridge augmentation: a 2-case report. *Int J Oral Maxillofac Implants* 2008;23:111-6.
- Barone A, Aldini NN, Fini M, Giardino R, Calvo Guirado JL, Covani U. Xenograft versus extraction alone for ridge preservation after tooth removal: a clinical and histomorphometric study. *J Periodontol* 2008;79:1370-7.
- Norton MR, Odell EW, Thompson ID, Cook RJ. Efficacy of bovine bone mineral for alveolar augmentation: a human histologic study. *Clin Oral Implants Res* 2003;14:775-83.
- Moses O, Nemcovsky CE, Langer Y, Tal H. Severely resorbed mandible treated with iliac crest autogenous bone graft and dental implants: 17-year follow-up. *Int J Oral Maxillofac Implants* 2007;22:1017-21.
- Güven O. Rehabilitation of severely atrophied mandible using free iliac crest bone grafts and dental implants: report of two cases. *J Oral Implantol* 2007;33:122-6.
- Brånemark PI, Hansson BO, Adell R, Breine U, Lindström J, Hallén O, et al. Osseointegrated implants in the treatment of the edentulous jaw. Experience from a 10-year period. *Scand J Plast Reconstr Surg Suppl* 1977;16:1-132.
- Brånemark PI, Adell R, Albrektsson T, Lekholm U, Lundkvist S, Rockler B. Osseointegrated titanium fixtures in the treatment of edentulousness. *Biomaterials* 1983;4:25-8.
- Hallman M, Mordenfeld A, Strandkvist T. Bone replacement following dental trauma prior to implant surgery--status. *Dent Traumatol* 2009;25:2-11.
- Del Fabbro M, Rosano G, Taschieri S. Implant survival rates after maxillary sinus augmentation. *Eur J Oral Sci* 2008;116:497-506.
- Babbush CA, Kent JN, Misiek DJ. Titanium plasma sprayed (TPS) screw implants for the reconstruction of the edentulous mandible. *J Oral Maxillofac Surg* 1986;44:274-82.
- Schnitman PA, Wöhrle PS, Rubenstein JE, DaSilva J, Wang NH. Ten-year results for Brånemark implants immediately loaded with fixed prostheses at implant placement. *Int J Oral Maxillofac Implants* 1997;12:495-503.
- Becker W, Becker BE, Israelson H, Lucchini JP, Handelsman M, Ammons W, et al. One-step surgical placement of Brånemark implants: a prospective clinical multicenter study. *Int J Oral Maxillofac Implants* 1997;12:454-62.
- Tarnow DP, Emtiaz S. Classi A. Immediate loading of threaded implants at stage 1 surgery in edentulous arches: ten consecutive case reports with 1- to 5-year data. *Int J Oral Maxillofac Implants* 1997;12:319-24.
- Balshi TJ, Wolfinger GJ. Immediate loading of Brånemark implants in edentulous mandibles: a preliminary report. *Implant Dent* 1997;6:83-8.
- Jaffin RA, Berman CL. The excessive loss of Brånemark fixtures in type IV bone: a 5-year analysis. *J Periodontol* 1991;62:2-4.
- Friberg BS, Jemt T, Lekholm U. Early failures in 4,641 consecutively placed Brånemark dental implants: a study from stage I surgery to the connection of the completed prostheses. *Int J Oral Maxillofac Implants* 1991;6:142-6.
- Truhlar RS, Orenstein IH, Morris HF, Ochi S. Distribution of bone quality in patients receiving endosseous dental implants. *J Oral Maxillofac Surg* 1997;55(12 Suppl 5):38-45.
- Balshi SF, Wolfinger GJ, Balshi TJ. Analysis of 164 titanium oxide-surface implants in completely edentulous arches for fixed prosthesis anchorage using the pterygomaxillary region. *Int J Oral Maxillofac Implants* 2005;20:946-52.

23. Aghabeigi B, Bousdras VA. Rehabilitation of severe maxillary atrophy with zygomatic implants. *Clinical report of four cases*. *Br Dent J* 2007;202:669-75.
24. Peñarrocha-Diago M, Uribe-Origone R, Guarinos-Carbó J. Implant-supported rehabilitation of the severely atrophic maxilla: a clinical report. *J Prosthodont* 2004;13:187-91.
25. Balshi TJ, Wolfinger GJ, Petropoulos VC. Quadruple zygomatic implant support for retreatment of resorbed iliac crest bone graft transplant. *Implant Dent* 2003;12:47-53.
26. Valerón JF, Valerón PF. Long-term results in placement of screw-type implants in the pterygomaxillary-pyramidal region. *Int J Oral Maxillofac Implants* 2007;22:195-200.
27. Davo R, Malevez C, Rojas J. Immediate function in the atrophic maxilla using zygoma implants: a preliminary study. *J Prosthet Dent* 2007;97(6 Suppl):S44-51.
28. Tulasne JF. Implant treatment of missing posterior dentition. In: Albrektsson T, Zarb GA, editors. *The Brånemark osseointegrated implant*. Chicago: Quintessence; 1989. p. 103-15.
29. Bedrossian E, Rangert B, Stumpel L, Indresano T. Immediate function with the zygomatic implant: a graftless solution for the patient with mild to advanced atrophy of the maxilla. *Int J Oral Maxillofac Implants* 2006;21:937-42.
30. Bedrossian E, Sullivan RM, Fortin Y, Malo P, Indresano T. Fixed-prosthetic implant restoration of the edentulous maxilla: a systematic pretreatment evaluation method. *J Oral Maxillofac Surg* 2008;66:112-22.
31. Bedrossian E, Stumpel L 3rd, Beckely ML, Indresano T. The zygomatic implant: preliminary data on treatment of severely resorbed maxillae. A clinical report. *Int J Oral Maxillofac Implants* 2002;17:861-5.
32. Bedrossian E, Stumpel L 3rd. Immediate stabilization at stage II of zygomatic implants: rationale and technique. *J Prosthet Dent* 2001;86:10-4.
33. Kahnberg KE, Henry PJ, Hirsch JM, Ohnell LO, Andreasson L, Brånemark PI, et al. Clinical evaluation of the zygoma implant: 3-year follow-up at 16 clinics. *J Oral Maxillofac Surg* 2007;65:2033-8.
34. Balshi SF, Wolfinger GJ, Balshi TJ. A retrospective analysis of 110 zygomatic implants in a single-stage immediate loading protocol. *Int J Oral Maxillofac Implants* 2009;24:335-41.
35. Wehrbein H. Bone quality in the midpalate for temporary anchorage devices. *Clin Oral Implants Res* 2009;20:45-9.
36. Jacobs R, Adriansens A, Verstreken K, Suetens P, van Steenberghe D. Predictability of a three-dimensional planning system for oral implant surgery. *Dentomaxillofac Radiol* 1999;28:105-11.
37. van Steenberghe D, Naert I, Andersson M, Brajnovic I, Van Cleynenbreugel J, Suetens P. A custom template and definitive prosthesis allowing immediate implant loading in the maxilla: a clinical report. *Int J Oral Maxillofac Implants* 2002;17:663-70.
38. van Steenberghe D, Ericsson I, Van Cleynenbreugel J, Schutyser F, Brajnovic I, Andersson M. High precision planning for oral implants based on 3-D CT scanning. A new surgical technique for immediate and delayed loading. *Appl Osseoint Res* 2004;4:27-30.
39. Brånemark PI, Albrektsson T, Zarb GA. *Tissue-integrated prostheses*. Chicago: Quintessence; 1985. p. 211-2.
40. van Steenberghe D, Glauser R, Blombäck U, Andersson M, Schutyser F, Pettersson A, et al. A computed tomographic scan-derived customized surgical template and fixed prosthesis for flapless surgery and immediate loading of implants in fully edentulous maxillae: a prospective multicenter study. *Clin Implant Dent Relat Res* 2005;7 Suppl 1:S111-20.
41. Balshi SF, Wolfinger GJ, Balshi TJ. Guided implant placement and immediate prosthesis delivery using traditional Brånemark System abutments: a pilot study of 23 patients. *Implant Dent* 2008;17:128-35.
42. Balshi TJ. The Biotes conversion prosthesis: a provisional fixed prosthesis supported by osseointegrated titanium fixtures for restoration of the edentulous jaw. *Quintessence Int* 1985; 16:667-77.

Corresponding author:

Mr Stephen F. Balshi
PI Dental Center, Institute for Facial Esthetics
467 Pennsylvania Ave
Ft. Washington, PA 19034
Fax: 215-643-1149
E-mail: balshi2@aol.com

Acknowledgements

The authors thank their administrative and clinical assistants for their kind and gentle treatment of the patient; Mark Palmer and the technicians at 360 Imaging for assistance with the CT scan; and Rui Moniz, Aline Cruz, and Dora Silva of CM Ceramics USA, for their contribution of final prosthesis construction.

Copyright © 2010 by the Editorial Council for
The Journal of Prosthetic Dentistry.