


Management of Biotechnical Complications Associated with a Full-Arch Implant Restoration Using Digital and Conventional Workflows: A Clinical Report

Niranjan Joshi, BDS, MDS , Jack Piermatti, DMD, FACP, Max Nahon, DDS, FACP, & Thomas Balshi, DDS, PhD, FACP

Department of Prosthodontics, College of Dental Medicine, Nova Southeastern University, Fort Lauderdale, FL

Keywords

CAD/CAM dentures; hybrid dentures; monolithic; retreat.

Correspondence

Niranjan Joshi, Nova Southeastern University
– Prosthodontics, 3200 S University Dr., Fort
Lauderdale, FL 33314–7796.
E-mail: njprostho@gmail.com

*The authors deny any conflicts of interest
regarding this study*

Accepted April 11, 2019

doi: 10.1111/jopr.13066

Abstract

Full-arch implant-supported restorations using a metal-acrylic resin design have had a high success rate but are also associated with frequent technical complications including framework misfit due to casting errors, debonding of denture teeth, and fracture of the acrylic from the metal framework. This clinical report describes a case of maxillary and mandibular full-arch implant-supported rehabilitation associated with technical and biological complications and use of digital technology for fabricating monolithic restorations. The use of a bio-functional try-in and its subsequent use as a conversion prosthesis for fabricating a master cast is described. The use of the patient's existing metal bar to fabricate a retreat type prosthesis is also described along with using digital technology for fabricating a new metal bar and a monolithic type of restoration. The integration of digital and conventional workflows to obtain an increased level of accuracy and simplicity is also discussed.

This clinical report reviews the management of 3 biotechnical complications associated with a fixed, implant-supported rehabilitation. The complications include abutment screw fracture, delamination of acrylic resin veneer material, and framework misfit. A detailed step-by-step technique of treatment using a digital technology is used to mill a monolithic prosthesis, to eliminate framework misfit, and to re-veneer an existing metal-acrylic resin restoration.¹

The full-arch implant restoration delivered in the “All-on-Four” concept has been shown to be a successful treatment approach for long-term function.^{2–4} This restoration can be fabricated in several different dental materials depending on the clinician's choice and the patient's clinical presentation. A popular choice is a metal framework veneered in acrylic resin, while other choices include porcelain-fused-to-metal, porcelain layered over zirconia, and monolithic zirconia.^{5–7} Regardless of the choice of material, the full-arch, fixed, screw-retained implant-supported restoration can provide excellent comfort and function for the edentulous patient.

Technical complications occurring with these restorations include chipping, fracture and wear of the veneering material, fracture and/or loosening of the abutment screws, and misfit and fracture of the metal framework.^{5–11} Multiple designs and changes in fabrication techniques have been proposed in an effort to ameliorate these complications.¹²

The focus of this article is to examine consequences of a lack of passivity of the metal framework within the acrylic veneered hybrid restoration. The stability of the interface between the restoration and the supporting implants is predicated upon passive fit of the restoration. Without a passive fit, technical complications such as screw loosening, fracture of the abutment, or of the implant itself have been reported.^{13–17}

Clinical report

An 80-year-old male patient presented to the postgraduate prosthodontic clinic with chief complaint of a loose mandibular prosthesis. The patient presented with a mandibular metal acrylic, screw-retained prosthesis reinforced with a cast metal substructure. He also had an existing maxillary conventional acrylic hybrid prosthesis with a cast metal framework. The patient's maxillary prosthesis also demonstrated multiple repairs of existing denture teeth associated with acrylic delamination. The maxillary restoration was supported by 6 implants (Nobel Biocare Kloten, Switzerland, and Biomet 3i, Palm Beach Gardens, FL), and the mandibular restoration was supported by 4 implants (Nobel Biocare), all of which were at the abutment level. On examination it was noted that the lower prosthesis was mobile on the anterior implants, and fractured abutment screws was suggested as a provisional diagnosis.

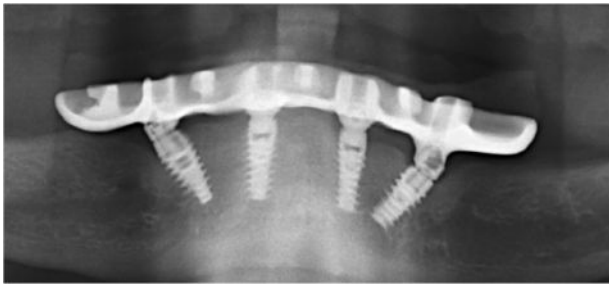

Figure 1 Radiographic view depicting fractured multiunit screws on anterior implants.



Figure 2 Retrieved fractured components of the anterior multiunit abutments.

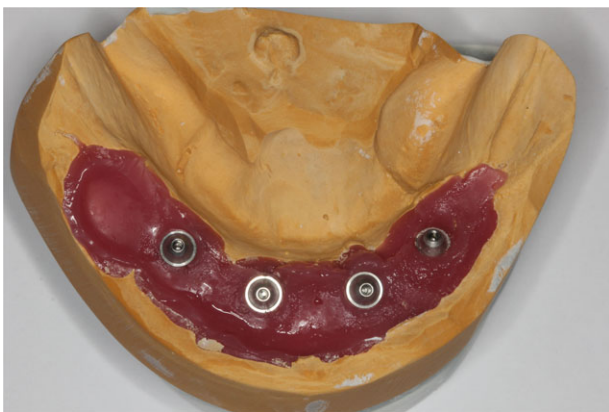


Figure 3 Initial abutment level working cast.

A 9 mm × 5 mm × 5 mm soft tissue overgrowth was noticed at the lingual crest of the left anterior implant. An initial diagnosis of irritational fibroma due to mobility of the prosthesis was suggested. Removal of the prosthesis revealed fractured multiunit abutment screws in the 2 anterior implants. This was confirmed radiographically (Fig 1).

The fractured portion of each screw was carefully rotated counterclockwise using a #23 explorer until the fractured screw was visible above the shoulder of the implant. A #34 carbide bur in a high-speed handpiece lightly touched the exposed

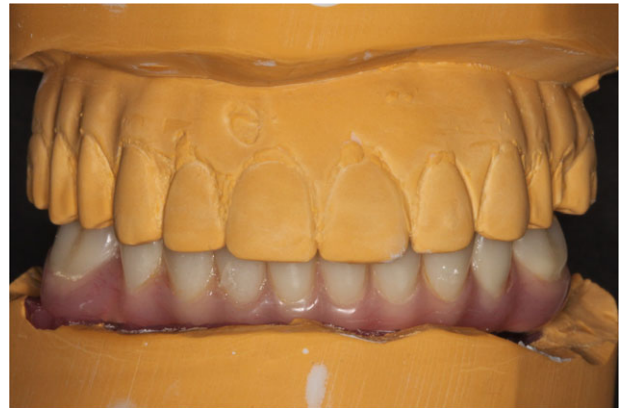

Figure 4 Mounted mandibular prosthesis against the maxillary arch.

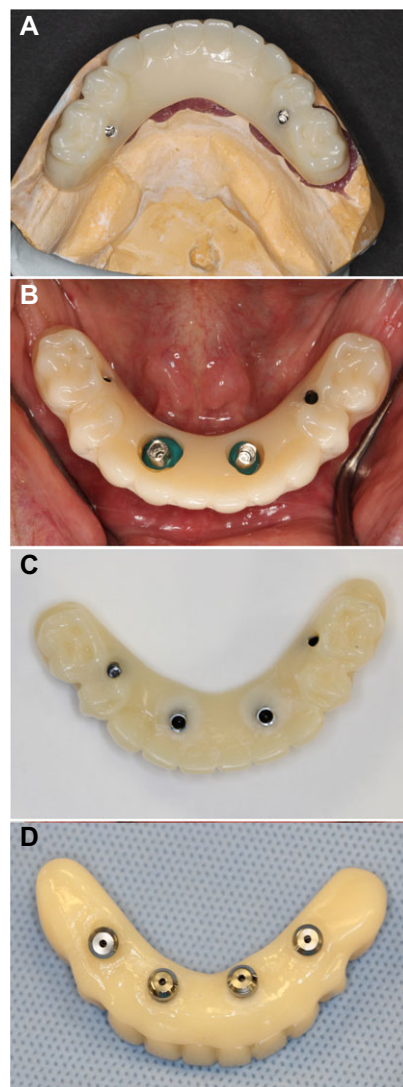


Figure 5 (A) Bio-functional try-in obtained from the lab secured only on the posterior abutments; (B) temporary cylinders secured on the anterior abutments prior to pick-up in acrylic; (C) bio-functional try-in after pick-up; and (D) intaglio view of the finished bio-functional try in.

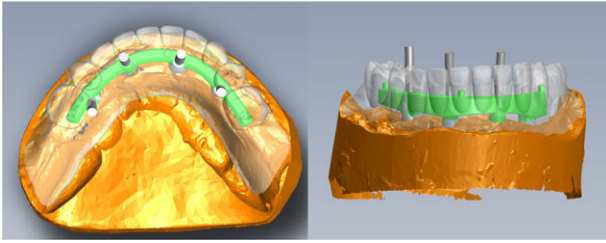


Figure 6 Digital preview of the bar design and the virtual tooth set-up for approval.

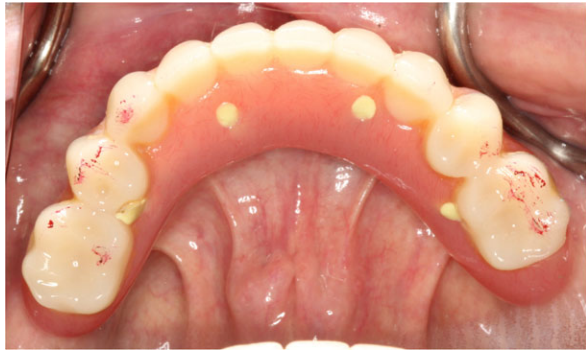

Figure 7 Occlusal view of the delivered mandibular definitive prosthesis.

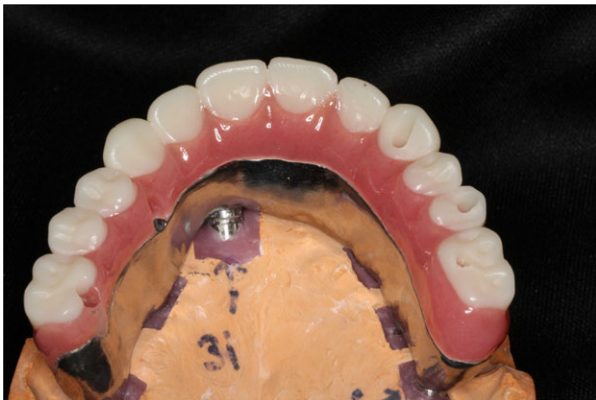

Figure 8 The definitive maxillary prosthesis "retreaded" on the existing metal substructure.

outer threads of the fractured screw to rotate it the rest of the way out of the implant body (Fig 2). New multiunit abutments (Nobel Biocare) were placed on the anterior implants, and the prosthesis was tried in. The prosthesis could not be retained passively, suggesting that the framework had a stress-inducing misfit.^{15,18,19}

An open tray impression of the mandibular prosthesis using long guide pins was made to obtain a working cast of the mandibular arch (Fig 3),²⁰ with the full realization that this would replicate the misfit condition currently experienced with the existing prosthesis. Maxillary and mandibular stone casts of the existing prostheses were obtained and cross-mounted with the working cast on which the mandibular prosthesis was

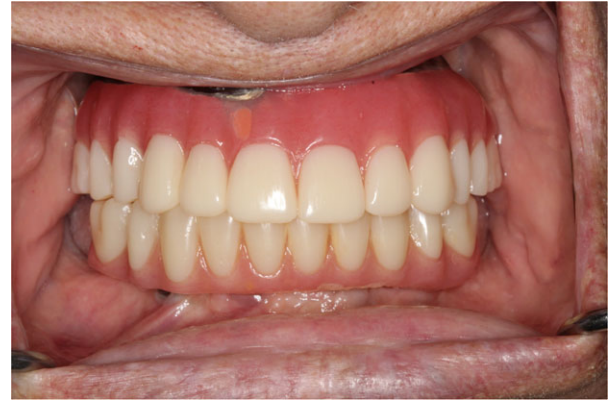

Figure 9 Frontal view of the completed prostheses.

secured, to maintain the existing occlusal vertical dimension (Fig 4).

The patient's existing prosthesis was inserted by using lightly tightened prosthetic screws on the newly installed anterior abutments. The patient was advised to maintain a soft diet until the new provisional prosthesis was made available. Maxillary and mandibular stone casts of the existing prostheses and cross-mounted working cast of the mandibular arch were used to fabricate a monolithic polymethylmethacrylate (PMMA) acrylic provisional restoration used for a bio-functional try-in (Global Dental Sciences Laboratory, AvaDent Digital Dental Solutions, Scottsdale, AZ). A putty matrix of the mandibular prosthesis against the working cast was also included. The bio-functional try-in prosthesis was obtained and secured on the posterior implants only (Fig 5A). At the second appointment the prosthetic screws on the 2 anterior abutments were fractured, further confirming a framework misfit.^{15,16,18,19} These were again removed carefully with an explorer. Temporary cylinders were attached to the anterior multiunit abutments (Fig 5B). With the bio-functional try-in secured to the posterior abutments, the temporary cylinders were picked up using autopolymerizing acrylic resin (Jet Tooth Shade; Lang Dental Mfg. Co., Worth, IL), and the prosthesis was finished and polished (Fig 5C, 5D).

The bio-functional try-in was checked for passivity using tactile method, the one-screw test, and radiographs. The bio-functional try-in was delivered, and the patient was scheduled to be seen after 3 weeks. After 3 weeks the mandibular provisional prosthesis was stable, with no movement detected. Removal of the prosthesis revealed no fractures of any abutment or prosthetic screws. Passivity of the monolithic PMMA interim prosthesis was rechecked using tactile method, the one-screw test, and radiographs.¹⁵ A new open tray impression of the bio-functional try-in was made using long guide pins, and a new master cast was obtained.²⁰ It was cross-mounted as described previously and sent to the laboratory for fabrication of the definitive mandibular prosthesis. At this same visit, since the hyperplastic soft tissue did not resolve, the mass was completely excised from its base and sent for histopathologic examination.

A monolithic PMMA resin prosthesis with a titanium bar was constructed (Avadent). The design of the bar was reviewed first, and any necessary changes were made (Fig 6).

The biofunctional try-in, which also served as an interim prosthesis, was removed, and the definitive prosthesis was securely fastened to the abutments with prosthetic screws. Minimal adjustments to the occlusion were made, and the prosthesis was delivered (Fig 7). The histopathological report of the soft tissue growth reported peripheral giant cell granuloma with fibrovascular tissue, chronic inflammatory cells, and multinucleated giant cells consistent with the preliminary diagnosis and will be followed up for recurrence.

During the treatment phase of the mandibular arch, the maxillary prosthesis functioning against the bio-functional try-in had to be repaired twice. A treatment plan for “Retread”¹ of the maxillary arch using the patient’s existing metal framework was presented and accepted by the patient. The maxillary prosthesis was checked for passivity by the previously mentioned method.¹⁵ Open tray impression of the maxillary prosthesis was made using long guide pins.²⁰ The models were cross articulated, and a bio-functional try-in was also fabricated for the maxillary arch to serve as an interim prosthesis.

The maxillary interim prosthesis was evaluated for function, and no chips or fractures were noted. A milled maxillary monolithic PMMA prosthesis (Fig 8) incorporating the patient’s existing bar was constructed (Avadent). The maxillary definitive “retread” prosthesis was delivered, and minimal adjustments to the occlusion were required (Fig 9). The patient has been followed up for 8 months, and no complications have been reported to date.

Discussion

The first use of acrylic resin dentures as fixed functional restorations came into being with their use as metal acrylic restorations on dental implants. As osseointegration became more predictable, clinicians expanded the use of dental implants to fabricate maxillary or mandibular full-arch fixed restorations opposing natural teeth or fixed restorations. This was the first time conventional acrylic denture teeth were used as fixed restorations opposing another fixed restoration.

Although these types of restorations provided high implant and prosthetic survival rates,^{2,3,21} they were also associated with significant technical complications. Most of these complications involved chipping of the veneered acrylic and debonding or fracture of denture teeth.^{13,22} Monolithic, full-arch, fixed, implant-supported zirconia prostheses have been shown to have the lowest incidence of technical complications.^{6,7,23}

Although conclusive scientific evidence is still unavailable, it is logical to assume that a monolithic restoration will be less likely to fracture or delaminate due to its inherent strength and lack of interfaces. Recent advances in the digital technology of denture resins allow us to fabricate monolithic acrylic dentures. These can either be monolithic bases with bonded denture teeth or more recently polychromatic billets having white and pink as one monolithic block.²⁴⁻²⁷

Due to inherent mechanical properties of acrylic resins, the hybrid prostheses have been supported by a metal bar.¹² CAD/CAM-fabricated frameworks have been shown to provide superior fit as opposed to conventional casting techniques.^{28,29} Different cross-sectional shapes have been suggested for the cantilever bar design, with I- and U-shaped configurations

showing lower end deflections.³⁰ However, L/I/U or the elliptical bar design can be used, depending upon the clinical situation and available space.³⁰

Summary

This clinical report demonstrates the diagnosis of an implant framework misfit, the removal of fractured abutment screws without the danger of injuring the internal threads of the implant body, and the construction of a monolithic provisional conversion prosthesis. After satisfactory clinical use of this prosthesis with no fractures of screws or veneer material, a new master cast was constructed using the conversion prosthesis protocol for the construction of a monolithic PMMA prosthesis for the mandibular arch. The maxillary prosthesis consisted of using digital positioning technology to incorporate the patient’s existing metal bar in the final prosthetic design of the revision treatment. All the methods described were developed to create an accurate, monolithic prosthesis with minimal interfaces and using components from the existing prosthesis.

References

- Balshi TJ, Wolfinger G, Alfano S, et al: The retread: A definition and retrospective analysis of 205 implant-supported fixed prostheses. *Int J Prosthodont* 2016;29:126-131
- Balshi TJ, Wolfinger G, Slauch R, et al: A retrospective analysis of 800 Brånemark System implants following the All-on-Four™ Protocol. *J Prosthodont* 2014;23:83-88
- Malo P, Rangert B, Nobre M: “All-on-Four” immediate-function concept with Brånemark System® implants for completely edentulous mandibles: a retrospective clinical study. *Clin Implant Dent Relat Res* 2003;5(Suppl 1):2-9
- Agnini A, Agnini AM, Romeo D, et al: Clinical investigation on axial versus tilted implants for immediate fixed rehabilitation of edentulous arches: preliminary results of a single cohort study. *Clin Implant Dent Relat Res* 2014;16:527-539
- Alshawaf B, Kudara Y, Weber HP, et al: Management of technical complications during full-mouth implant rehabilitation with hybrid prostheses over a 7-year period. *Compend Contin Educ Dent* 2018;39:e1-e4
- Box VH, Sukotjo C, Knoernschild K et al: Patient-reported and clinical outcomes of implant-supported fixed complete dental prostheses: a comparison of metal-acrylic, milled zirconia, and retrievable crown prostheses. *J Oral Implantol* 2018;44:51-61
- Gonzalez J, Triplett RG: Complications and clinical considerations of the implant-retained zirconia complete-arch prosthesis with various opposing dentitions. *Int J Oral Maxillofac Implants* 2017;32:864-869
- AlBader B, Alhelal A, Proussaefs P, et al: Digitally milled metal framework for fixed complete denture with metal occlusal surfaces: a design concept. *Int J Periodontics Restorative Dent* 2017;37:e180-e188
- Jemt T: Failures and complications in 391 consecutively inserted fixed prostheses supported by Brånemark Implants in edentulous jaws: a study of treatment from the time of prosthesis placement to the first annual checkup. *Int J Oral Maxillofac Implants* 1991;6:89-102
- Malo P, Nobre M, Guedes C, et al: Outcomes of immediate function implant prosthetic restorations with mechanical complications: a retrospective clinical study with 5 years of follow-up. *Eur J Prosthodont Restor Dent* 2017;25:26-34

11. Yilmaz B, Gilbert A, Seidt JD et al: Displacement of implant abutments following initial and repeated torqueing. *Int J Oral Maxillofac Implants* 2015;30:1011-1018
12. Drago C, Howell K: Concepts for designing and fabricating metal implant frameworks for hybrid implant prostheses. *J Prosthodont* 2012;21:413-424
13. Papaspyridakos P, Chun-Jung C, Sung-kiang C, et al: A systematic review of biologic and technical complications with fixed implant rehabilitations for edentulous patients. *Int J Oral Maxillofac Implants* 2012;27:102-110
14. Zarb GA, Schmitt A: The longitudinal clinical effectiveness of osseointegrated dental implants: the Toronto study. Part III: Problems and complications encountered. *J Prosthet Dent* 1990;64:185-194
15. Kan JYK, Rungcharassaeng K, Bohsali K, et al: Clinical methods for evaluating implant framework fit. *J Prosthet Dent* 1999;81:7-13
16. Katsoulis J, Takeichi T, Gaviria AS, et al: Misfit of implant prostheses and its impact on clinical outcomes. Definition, assessment and a systematic review of the literature. *Eur J Oral Implantol* 2017;10:121-138
17. Balshi TJ: An analysis and management of fractured implants: a clinical report. *Int J Oral Maxillofac Implants* 1996;11:660-666
18. Balshi TJ: Preventing and resolving complications with osseointegrated implants. *Dent Clin North Am* 1989;33:821-868
19. Abduo J, Judge RB: Implications of implant framework misfit: a systematic review of biomechanical sequelae. *Int J Oral Maxillofac Implants* 2014;29:608-621
20. Balshi TJ, Wolfinger G, Alfano S, et al: Fabricating an accurate implant master cast: a technique report. *J Prosthodont* 2015;24:654-660
21. Balshi TJ, Wolfinger G, Slauch R, et al: Branemark system implant lengths in the pterygomaxillary region: a retrospective comparison. *Implant Dent* 2013;22:610-612
22. Millen C, Bragger U, Wittneben JG: Influence of prosthesis type and retention mechanism on complications with fixed implant-supported prostheses: a systematic review applying multivariate analyses. *Int J Oral Maxillofac Implants* 2015;30:110-124
23. Bidra A, Rungruanganunt P, Gauthier M: Clinical outcomes of full arch fixed implant-supported zirconia prostheses: a systematic review. *Eur J Oral Implantol* 2017;10:35-45
24. Steinmassl PA, Klaunzer F, Steinmassl O, et al: Evaluation of currently available CAD/CAM denture systems. *Int J Prosthodont* 2017;30:116-122
25. Steinmassl O, Dumfahrt H, Grunert I, et al: CAD/CAM produces dentures with improved fit. *Clin Oral Investig* 2018;22:2829-2835
26. Kattadiyil M, Goodacre C, Lozada J, et al: Digitally planned and fabricated mandibular fixed complete dentures. Part 2. Prosthodontic phase. *Int J Prosthodont* 2015;28:119-123
27. Fernandez MA, Nimmo A, Behar-Horenstein LS, et al: Digital denture fabrication in pre- and postdoctoral education: a survey of U.S. dental schools. *J Prosthodont* 2016;25:83-90
28. Drago C, Saldarriaga R, Domagala D, et al: Volumetric determination of the amount of misfit in CAD/CAM and cast implant frameworks: a multicenter laboratory study. *Int J Oral Maxillofac Implants* 2010;25:920-929
29. Takahashi T, Gunne J: Fit of implant frameworks: An in vitro comparison between two fabrication techniques. *J Prosthet Dent* 2003;89:256-260
30. Staab GH, Stewart RB: Theoretical assessment of cross sections for cantilevered implant-supported prostheses. *J Prosthodont* 1994;3:23-30